


A Definitive Guide to Prosthodontics

Demystifying the Complex World of Contemporary Clinical Procedures



MODERN
Dental Pacific



TRANSFORMATION

The world of dentistry is changing rapidly. As dental professionals you are on the cusp of a quantum leap in technological change. New digital technologies are driving fundamental changes in almost every aspect of your work, including how you practice, what materials you use, and what choices you offer your patients.

At the same time, today's patients are keen to know how the art and the science of dentistry can transform their smiles and sustain oral health. They want to avoid the negative dental experiences of previous generations, and they truly value the expertise of dental teams who can deliver new technologies and services.

In response, today's dentists need to stay up to date with technological changes and patient expectations. The new wave of digital transformation provides unprecedented opportunities for dentists to embrace new and exciting developments and use them alongside their own tried and tested techniques and materials.

Taking the time to understand the diverse range of possibilities that are now available for your patients is a smart business move. With Modern Dental Pacific by your side, you'll be able to offer the best solutions to your patients, while liaising with fellow health professionals, suppliers and laboratories to ensure the best outcome is achieved.

As leaders in dental prosthetic solutions and digital workflow options, the team at Modern Dental Pacific work alongside dental professionals just like you to help them evolve with the demands of modern dentistry.

To help make your ambitions a reality, the dentists and technicians within our clinical team have put together this handbook for people working in the dental profession. It provides key information about the latest materials, techniques and developments in dentistry, all from an evidence-based perspective. Of course, it's not a comprehensive textbook, nor does it replace manufacturer guidelines and recommended use applications.

The transforming world of dentistry is complex, challenging and exciting. We hope you will use this handbook as a quick reference guide to navigate it!

Contributing Authors:

Dr Brenda Baker

Dr Ian Jacobi

Dr David Reaney

Dr Simon Parsons

Dr Philip Newsome

Dr David Penn

SIX LABORATORIES. ONE CORE VISION.

Modern Dental Pacific consists of six unique laboratories, each focusing on a specific range of quality products and services. While they differ in range, our laboratories share one vital common ingredient – an unwavering commitment to our customers. Modern Dental Pacific's laboratories are built around this dedicated customer focus.

Every day, we do this by providing full laboratory services, expert guidance, access to peer-to-peer support and product specific guidelines and advice. Our vision is to support you and your patients, today and into the future.



ANDENT

Founded as a family-owned business, Andent is our Melbourne-based laboratory with generations of experience in the Australian dental industry and state-of-the-art milling facilities. Pioneers of digital laboratory services in Australia, Andent specialises in advanced workflow solutions, implant, ceramic, crown and bridge restorations. Whether designed and produced through CAD/CAM or handcrafted with an eye for detail, Andent's combination of local technicians and production ensures easy communication and fast and efficient turnaround of your cases.



GOLD & CERAMICS

Gold & Ceramics is our Brisbane-based dental laboratory. They have over 35 years of experience in providing comprehensive laboratory services to dental practices and, further 25 years of experience in dental ceramics and alloys. Gold & Ceramics uses only the most sophisticated techniques and the finest materials to create premium pieces that stand the test of time.



PRECISION DENTAL LABORATORY

Precision Dental Laboratory is our New Zealand-based dental laboratory, proudly delivering on the promise of being 100% NZ made. At Precision, locally based technicians work in a consultative manner, using a mix of traditional crown and bridge methods, as well as the latest CAD/CAM and pressing technologies. Precision shares the belief that quality and value comes from the right technology in the hands of the right people.



PROFORM

PROFORM AUSTRALIA

Proform is our specialist Australian laboratory offering state-of-the-art thermoformed dental products. From mouthguards and nightguards to anti-snoring devices, our extensive knowledge and advanced design techniques ensure that we can guarantee you and your patient a unique product, every time.



SOUTHERN CROSS DENTAL

AUSTRALIA, NEW ZEALAND & IRELAND

Southern Cross Dental has been serving the Australian, New Zealand and Irish dental industries for more than 35 years. This experience, coupled with the blend of local and international laboratory expertise, means that Southern Cross Dental has the ability to provide the most comprehensive range of services, along with the industry knowledge, to help you manage your practice as a dental professional into the future: reliable, high quality products and services that help you give your patients the best possible results, all at highly affordable prices.

CONTENTS

Chapter 1	The Oral Physician	10
	The Role of the Oral Physician	12
	Evidence-Based Treatment Planning	13
	Successful Practice – Stay Out of Trouble	22
Chapter 2	Treatment Modalities with Oral Appliances	24
	Neuromuscular Disorders	26
	Splint Types and Functions	27
	Materials Used	28
	Laboratory Instructions	29
	Sleep Bruxism	30
	Obstructive Sleep Apnoea	32
	The Role of the Dentist	34
	Xerostomia	39
	Diagnosis	39
	Management of Hyposalivation and Xerostomia	40
Chapter 3	Digital Dentistry	42
	Advantages of Digital Workflow	44
	Limitations and Disadvantages of Digital Workflow	45
	Digital Scanner Systems	45
	Workflows in Digital Dentistry	47
	The Digital Workflow Processes Connecting the Dentist and the Laboratory	50
Chapter 4	The Taking Of Records	52
	Soft Tissue Control	54
	Tooth Preparation Margins	55
	Gingival Retraction	55
	Taking Records – Conventional Impressions – Digital Scanning	57
	Analogue Impressions	58
	Summary of Commonly Encountered Problems with Impressions	59
	Digital Scans	60
	Summary of Commonly Encountered Problems with Digital Scans	61
	Occlusal Records	63
	Digital Occlusal Records	65
	Sending Analogue and Digital Records to the Laboratory	66
	Digital Photography	66
	Aesthetic Diagnostic Considerations and Checklist	67
	Shade Selection	68
	Diagnostic Wax-Up	71

Chapter 5 Materials in Dentistry 72

Evolutionary Change.....	74
Ceramic Restorations Quick Guide	75
Ceramics – Overview of Materials	76
Metals in Dentistry	84
Alloys – Properties and Indications.....	84
Posts and Cores.....	87
Metal-Ceramics.....	88
Hybrid Ceramics.....	90

Chapter 6 Aesthetic Dentistry 92

Digital Smile Design.....	94
Principles of Smile Design	95
Practice–Laboratory Partnership in Digital Workflow	98
Bleaching and Orthodontics	99
Aesthetic Recontouring	101
Veneers	102
The Treatment Planning Process.....	104
Clinical Procedures.....	106

Chapter 7 Crown and Bridgework 110

Tooth Preparation Concepts.....	112
All-Ceramic Crown Preparations	116
Suggested Burs and Preparation Features	119
Common Errors to Avoid	121
Resin-Bonded Bridges	123
Inlays and Onlays	126
Cementation	128
Restoration Cementation Guide	131
Preventing Tooth Sensitivity.....	132
Chairside Finishing and Polishing.....	132

Chapter 8 Implants 134

Treatment Planning for Implants	136
Treatment Planning and Imaging	139
Implant Occlusion Recommendations	141
Achieving Successful Outcomes: What to Consider	142
Impressions for Implants	146
Prosthodontic Management of Implant Therapy.....	148
Screw-Retained and Cement-Retained Restorations	149

Abutment Selection and Options.....	150
Overdentures.....	152
Material Selection of Implants	155
Final Fit Check and Issue	157
Complications in Restorations	159
Other Complications.....	162
Implant Maintenance Protocols.....	162

Chapter 9 Removable Prosthodontics 164

Removable Partial Dentures (RPDs).....	166
Design.....	167
Tooth-Coloured Clasps	168
Denture Base Material	169
Steps for Successful RPDs.....	170
Implant-Supported RPDs	170
Digital Removable Prosthodontics	171
Digital Design	172
Flowchart of CAD/CAM Denture Production	173
Precision Attachments	174
Immediate Dentures	176
Full-Acrylic Dentures/Flexible Dentures	177
Comparison of Denture Base Materials	177

Bibliography 178



01

THE ORAL PHYSICIAN



Overview

The only thing that is constant is change – Heraclitus c 400 BC

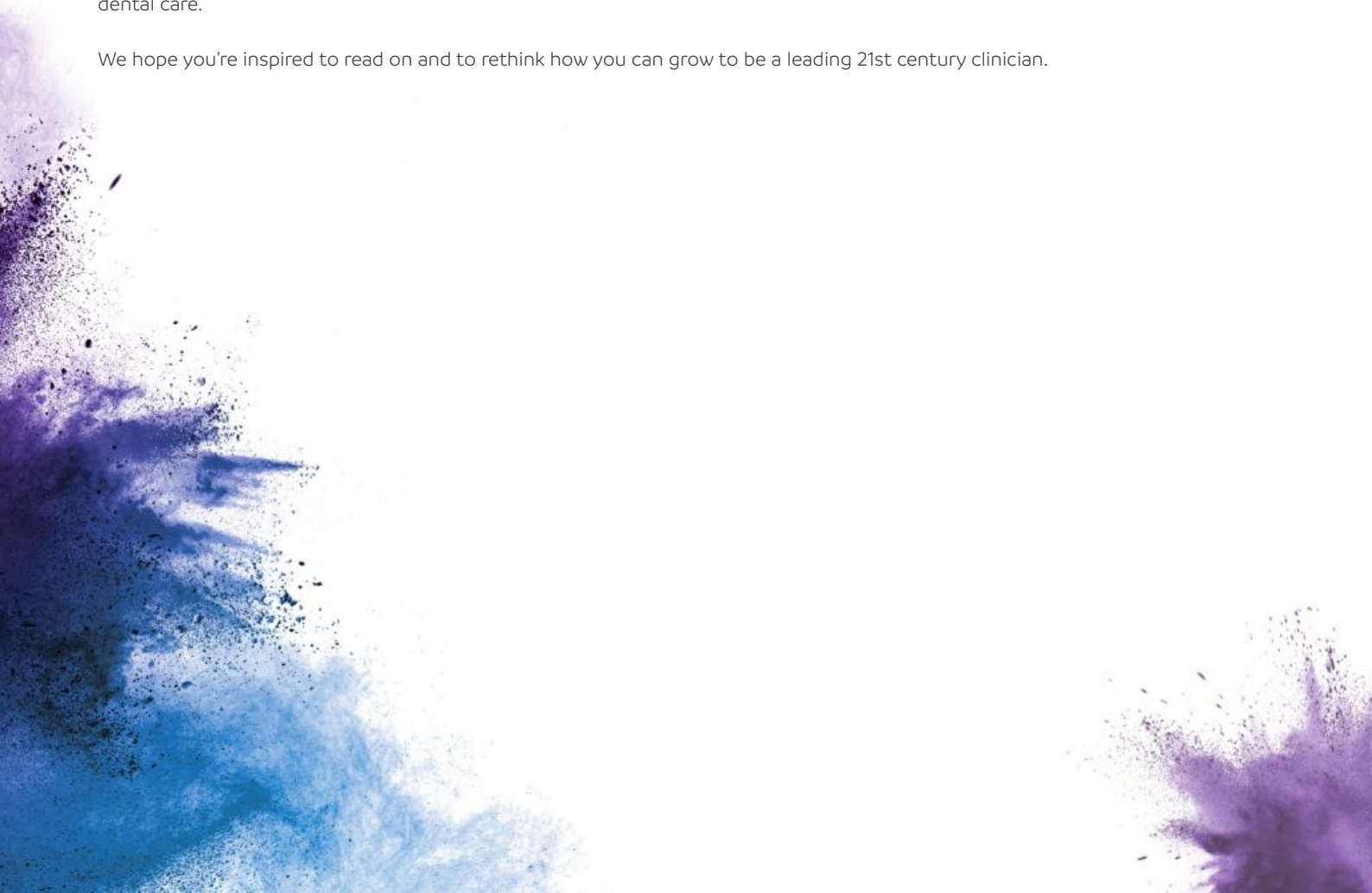
Are you struggling with the rapid rate of change within the dental industry? With so many new materials, technologies, and approaches to consider, it can be hard to appropriately manage the diverse needs and expectations of your patients.

As modern health professionals, today's dentists are responsible for far more than just great oral care. We are now part of the front line of modern healthcare, and our patients rely on us to be educators and preventers of disease. This requires us to work with other health professionals, and to stay up to date with issues of patient safety and efficacy of care.

Today's patients are more demanding than ever before. They want to know what's new, and they want to be informed. They also want us to look out for issues that will affect their overall health. Far from being "just a dentist", today's oral physicians are expected to be skilled healers, collaborators and communicators.

In this chapter we explore what these changes to modern dentistry mean for you. We also think about how to deal with important issues such as maintaining oral health in patients, and managing worn teeth that no longer necessarily fail because of cavities or periodontal disease. Most importantly, we think about how you can excel in your practice by doing what you've been taught to do; diagnosing, treatment planning and delivering expert dental care.

We hope you're inspired to read on and to rethink how you can grow to be a leading 21st century clinician.



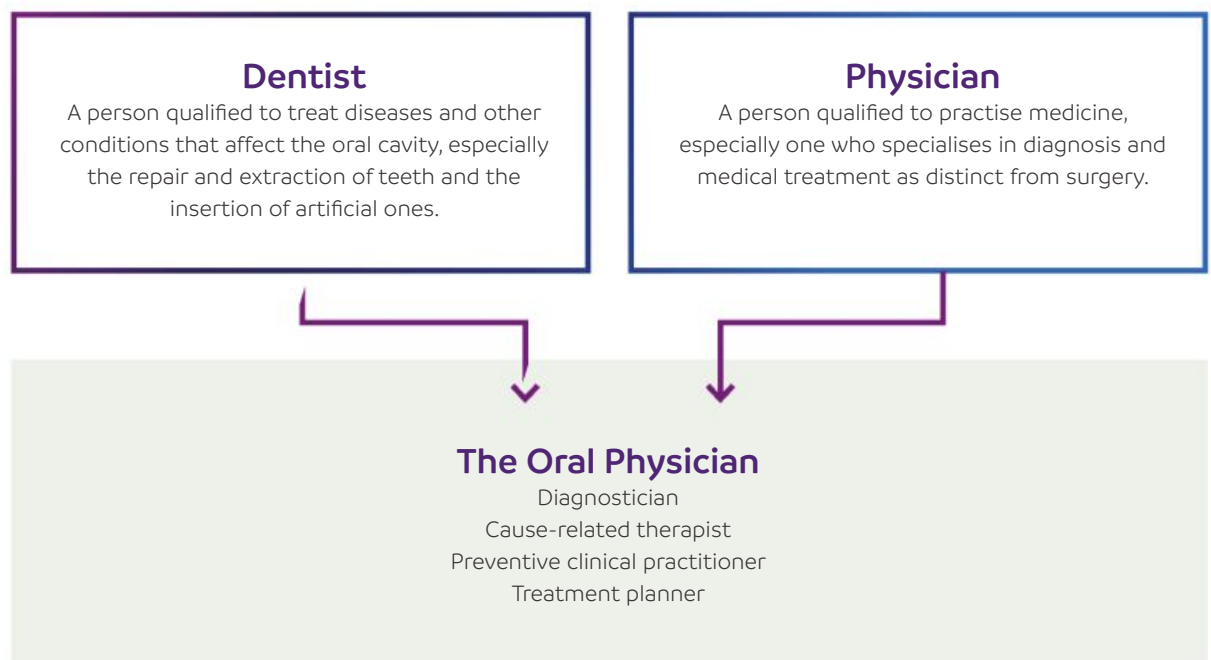
01

THE ORAL PHYSICIAN

Providing patient management in the oral health arena requires interdisciplinary and multidisciplinary professional care. This brings together the medical, oral health and dental technical teams to achieve this goal.

The Role of the Oral Physician

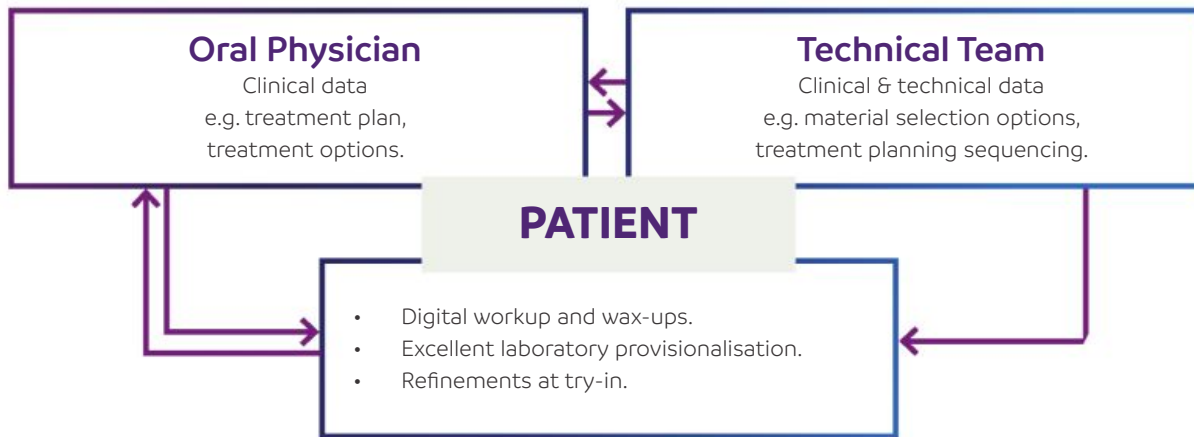
As practitioners of oral health and its maintenance, dentists are compelled to lead the profession in clinical delivery to patients. Globally, the scope of responsibilities and care for the dentist has increased. The dentist is no longer an isolated professional but a synergistic part of a healthcare team that provides risk assessment and disease prevention. "We should shed the historically limiting term of dentist referring only to the teeth. We are now much more than that and therefore should welcome the change to oral physician, which better describes what we can and should do" (Giddon, D. B., 2015). "Dentists may need to monitor chronic disease and control the risk factors in order to provide primary care for their own dental patients" (Greenberg, B. L., et al., 2010). For example, studies show that up to 50% of heart attacks are triggered by oral bacteria as well as other serious systemic complications (Go, A.S., et al., 2013).



THE PATIENT-ORAL PHYSICIAN-TECHNICAL TEAM COMMUNICATION CHAIN

(Modified from Sawhney, S., et al., 2014)

Establishing the best communication and teamwork with the dental technical team builds confidence and ensures consistent and successful results.



The patient should feel a sense of commitment from the team. Knowing and understanding the patient will enhance communication and trust, thus allowing the clinician to tailor appropriate treatment plans. The adage, “never treat a stranger” (Sir William Osler) has never been more apt. Causation-based treatment generates case acceptance.

Evidence-Based Treatment Planning

The Australian Dental Association’s Policy Statement 6.8 – Evidence-Based Dentistry defines Evidence-Based Dentistry as “an approach to oral health care which requires the judicious integration of systematic assessments of the best clinically relevant scientific evidence, relating to the patient’s oral and medical condition and history, with the dentist’s clinical expertise and patient’s treatment needs, values and circumstances”. (Australian Dental Association n.d.)

Any treatment plan must include short-term, medium-term and long-term goals (Newsome, P., et al., 2012). History taking and clinical examination are two of the most important considerations of the assessment process. Multidisciplinary comprehensive treatment plans are now commonplace, which can be time-consuming, and patient motivation is the key (Arroyo, J.G., et al., 2012. Gurrea, J. and Bollain, I.G., 2016).

A. HISTORY

Growing collaboration between healthcare professionals means that dentists can no longer be isolated or separated from mainstream healthcare and must increase their awareness of underlying medical conditions that can influence treatment plans.

An overview of the history and examination appointment would include:

1. Health history form – dental, medical, social.
2. Implication of systemic conditions and the medications used to treat them (Malamed, S.F., 2015).
3. Xerostomia.
4. Sleep bruxism and obstructive sleep apnoea.

Obtain fully informed consent with written records before any treatment is commenced (Kalsi, J.S. and Hemmings, K., 2013).

B. EXAMINATION

Clinical examination to detect abnormalities of soft/hard tissues.

Magnification in Operative Dentistry

When choosing loupes several parameters need consideration (Christensen, G.J., 2003):

- Most dentists use magnifications of 2x to 4x.
- Lower power systems of 2x to 2.5x provide a view of up to a quadrant with good depth of field, whereas higher power systems of 3x to 4x enable viewing of several teeth or a single tooth. Use of small, LED headlamps improve illumination.

Clinical Examination of Teeth and Restorations

Generally, a restoration should not be replaced unless (Anusavice, K.J., 1988):

- There are significant marginal discrepancies.
- The tooth is at risk for caries or fracture.
- The restoration is an aetiological factor to adjacent teeth or tissue.

(Also, consider replacing unaesthetic existing restorations in the appearance zone.)

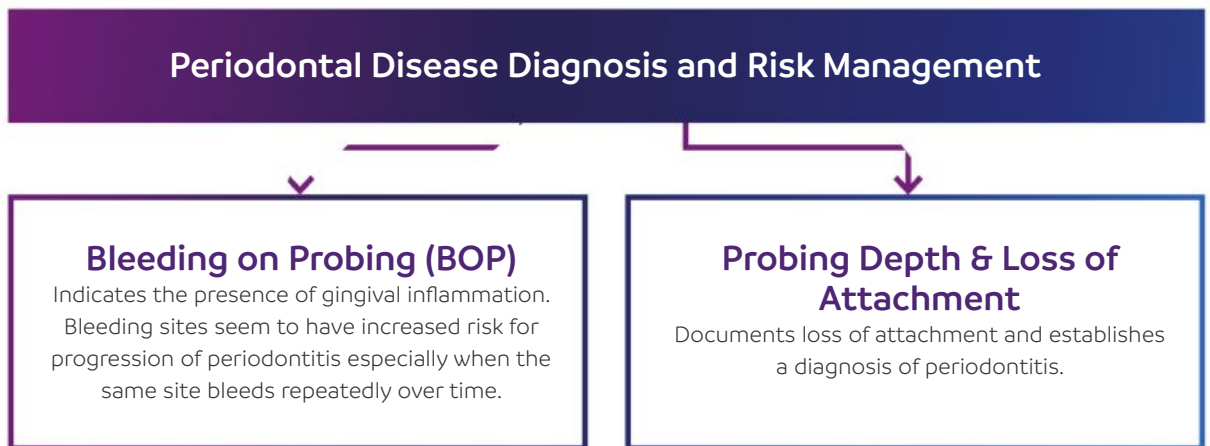
Radiographic Evaluation:

(American Dental Association Council on Scientific Affairs, 2006)

- Perioral and intraoral photographs provide valuable information about local conditions to augment treatment planning and hence provision of successful prostheses (Harris, D., et al., 2002).
- Periapical radiographs utilising a long-cone paralleling technique (Floyd, P., et al., 1999) are still important to help evaluate adjacent tooth connective tissue attachment and bone levels in the anterior maxillary aesthetic zone. Radiopaque millimetre grids can be superimposed over the film before it is exposed (Misch, C.E., 2007).
- Orthopantomogram (OPG).
- Volumetric assessment of available bone is best achieved with Cone Beam Computed Tomography (CBCT) (Harris, D., et al., 2012). A CBCT image offers measurement of mesiodistal, buccolingual and occlusogingival osseous dimensions and the topography of the edentulous space and is the gold standard for implants.

Periodontal Evaluation

(Wong, R., et al., 2012)



Periodontal Record Keeping – baseline measurements:

- The basic periodontal examination (BPE) and periodontal screening and recording index (PSR) identifies the presence/absence of disease and screens for periodontal treatment needs.
- If BPE/PSR and/or initial visual assessment indicate a severe periodontal condition, a complete charted recording of periodontal findings should be documented:
 - » Clinical loss of attachment (six points per tooth)
 - » BOP
 - » Furcation involvement
 - » Tooth mobility/drift
 - » Suppuration on probing
 - » Periodontal probing depth
 - » Recession

Goal Setting for Periodontal Therapy (Corbet, E. F., and Davies, W.I.R., 1993)

Parameter	Outcome
Plaque Level	Attain a high level of plaque control – full mouth bleeding on probingscores below 20-25%. The absence of bleeding on probing over repeated examinations is the best indicator of periodontal stability currently available.
Probing Pocket Depth	Not greater than 5mm including horizontal probing in furcations of less than 5mm.

C. IDENTIFICATION OF UNDERLYING CONDITIONS AND RISK FACTORS

Determine any sources of acute pain, bleeding, hard and soft tissue infections.

Caries management – **Caries Management by Risk Assessment (CAMBRA)** identifies the causes of dental disease by assessing the degree of risk that an individual faces and targets the cause of caries, periodontal disease, recession and xerostomia for the prevention of tooth loss for the primary and secondary dentition (Yanase, R.T. and Le, H.H., 2014).

Radiographic Risk Assessment

Type of Patient	<ul style="list-style-type: none"> • New. • Recall with: <ul style="list-style-type: none"> » Clinical caries or increased risk for caries » No clinical caries and no risk for increased risk of caries » Periodontal disease • Monitor growth and development. • Other including but not limited to: <ul style="list-style-type: none"> » Existing implants, pathology, restorative/endodontic needs, treated periodontal disease and caries remineralisation
Age of Patient	<ul style="list-style-type: none"> • Primary dentition (before eruption of first permanent tooth). • Transitional dentition (after eruption of first permanent tooth). • Adolescent permanent dentition (before eruption of wisdom teeth). Adult, dentate/partially edentulous. • Adult edentulous.

Caries Risk Assessment (Yip, K. and Smales, R., 2012)

Conditions	<ul style="list-style-type: none"> • Contributing – fluoride exposure, diet, caries experience of family, lifestyle. • General health – special care needs, chemotherapy, radiation therapy. • Clinical – visible plaque, overhangs, cavitated/non-cavitated carious lesions.
Diagnosis	<ul style="list-style-type: none"> • Visual, tactile (International Caries Detection and Assessment System [ICDAS]), transillumination, laser and blue light, radiographs, chemical examination.

Tooth Wear

(Mehta, S.B., et al., 2012) (Ranjitkar, S., et al., 2012)

Tooth wear describes the surface loss of dental hard tissues from causes other than dental caries, trauma or as a result of developmental disorders (Hattab, F.N., et al., 1999). Normal vertical loss of enamel from physiologic wear is about 20-38µm/annum (Lambrechts, P., et al., 1989). "Tooth surface loss" embraces all the aetiological factors regardless of whether or not the exact cause of wear has been identified.

Sub-Classification of Tooth Wear Lesions

Erosion	<ul style="list-style-type: none"> Chemical dissolution of tooth structure without plaque. Sources of acids start from inside the body as gastric acid (intrinsic or endogenous erosion) or outside the body (extrinsic or exogenous erosion).
Attrition	<ul style="list-style-type: none"> Occurs from tooth-to-tooth contact without the presence of food. Occurs from tooth grinding either nocturnally while asleep or diurnally.
Abrasion	<ul style="list-style-type: none"> Occurs by friction of anything foreign to the tooth forced over the tooth surfaces. Wear from food abrasion is usually distributed throughout the arch. Overzealous tooth brushing – rounded or "V" shaped ditches on buccal/labial surfaces – canines and premolar teeth are commonly affected.

Aetiology

Erosion	<ul style="list-style-type: none"> Vomiting. Gastroesophageal reflux disease (GORD) - usually affects palatal surfaces of upper posterior teeth. Rumination – refluxate enters the mouth and is chewed. Generalised pattern especially occlusal tooth surfaces. Burping – most "acidic air" enters the oral cavity. Dietary – frequency of exposure determines severity or extent of problem.
Attrition	<ul style="list-style-type: none"> Symptoms of various craniomandibular disorders.
Abrasion	<ul style="list-style-type: none"> Parafunctional activity – chewing end of pen, chewing pipe stem, etc.

Clinical Signs

Erosion	<ul style="list-style-type: none"> As erosion progresses, teeth lose their normal contours. Curved enamel areas flatten and eventually become "dished out" especially buccal and labial surfaces of tooth crowns.
Attrition	<ul style="list-style-type: none"> Enamel flaking on labial/incisal edges of upper teeth and lingual/incisal edges of lower teeth. Buccal cusps of upper and lingual cusps of lower posterior teeth often fracture. Facet – flat surface with well-circumscribed border and will have matching surface in the opposing arch.
Abrasion	<ul style="list-style-type: none"> Abrasion from foreign objects – tobacco pipe stems, bobby hairpins, hard foods (pumpkin seeds, watermelon seeds) is often identified by asymmetric wear as a notch on the anterior teeth. Scooped dentine on incisal and occlusal surfaces, especially if exposed dentine is not sensitive, may be caused by abrasion.

Occlusal Assessment

Extraoral

- Place patient semi-supine.
- Get patient to slowly open/close mouth.
- Note centre-line mandibular deviations, restricted movements and Temporomandibular Joint (TMJ) noises.
- Ask patient to make non-guided lateral and protrusive movements. Is there fremitus/muscle tremor?

Intraoral

- Check for occlusal instability and adverse responses to increased occlusal mechanical stresses (cracked/chipped teeth and restorations, split cusps, heavy tooth and restoration wear facets, mobile teeth, tooth migration).
- Occlusal discrepancies are a predictor for deeper pocket depths and greater tooth mobility in the presence of existing inflammatory periodontal disease.

Orthodontic and/or orthognathic assessment may be required to address functional and/or aesthetic needs.

Planning for Implants (Boyce, R.A. and Klemons, G., 2015).

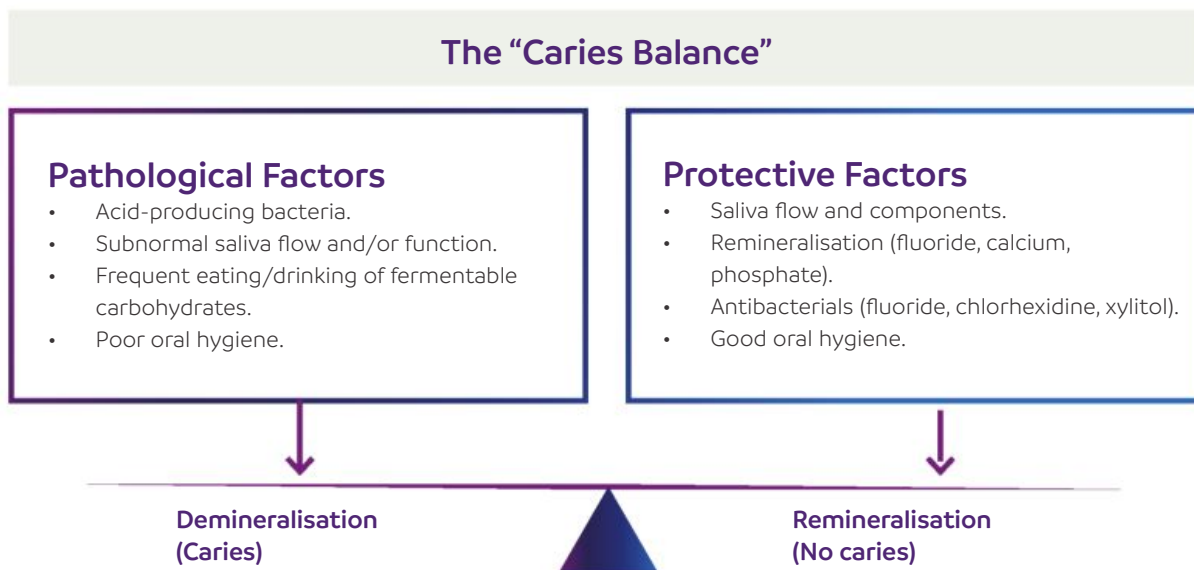
"Treatment planning for restorative implantology should be looked at in four sections using these four concepts of treatment planning along with proper surgical placement of implant(s) results in successful cases:

- Review of past medical history.
- Oral examination and occlusion.
- Dental imaging.
- Fixed vs removable prosthodontics."

D. PREVENTION AND DISEASE CONTROL

Understanding Caries Management

Remineralisation therapy as well as sealants in the case of pits and fissures are the preferred methods of managing coronal lesions that are neither cavitated nor have penetrated into dentine. Understanding the balance between demineralisation and remineralisation is the **KEY** to caries management (Featherstone, J.D., 1999).



Prevention of Primary Caries and Periodontal Disease:

- Fluoridation of domestic water.
- Bacterial biofilm control – correct brushing/floss/interdental brushes/0.2% chlorhexidine.
- Establishment of adequate salivary flow.
- Dietary counselling.
- Fluoride-toothpaste/mouthrinse/varnish/gels/foams/casein-derived remineralisation pastes (CPP-ACP).
- Resin-based/GIC pit and fissure sealants.

Smooth Surface Lesions:

- Change dietary habits.
- Increase use of topical fluorides and CPP-ACP.

The above measures can tip the balance towards remineralisation and arrest.

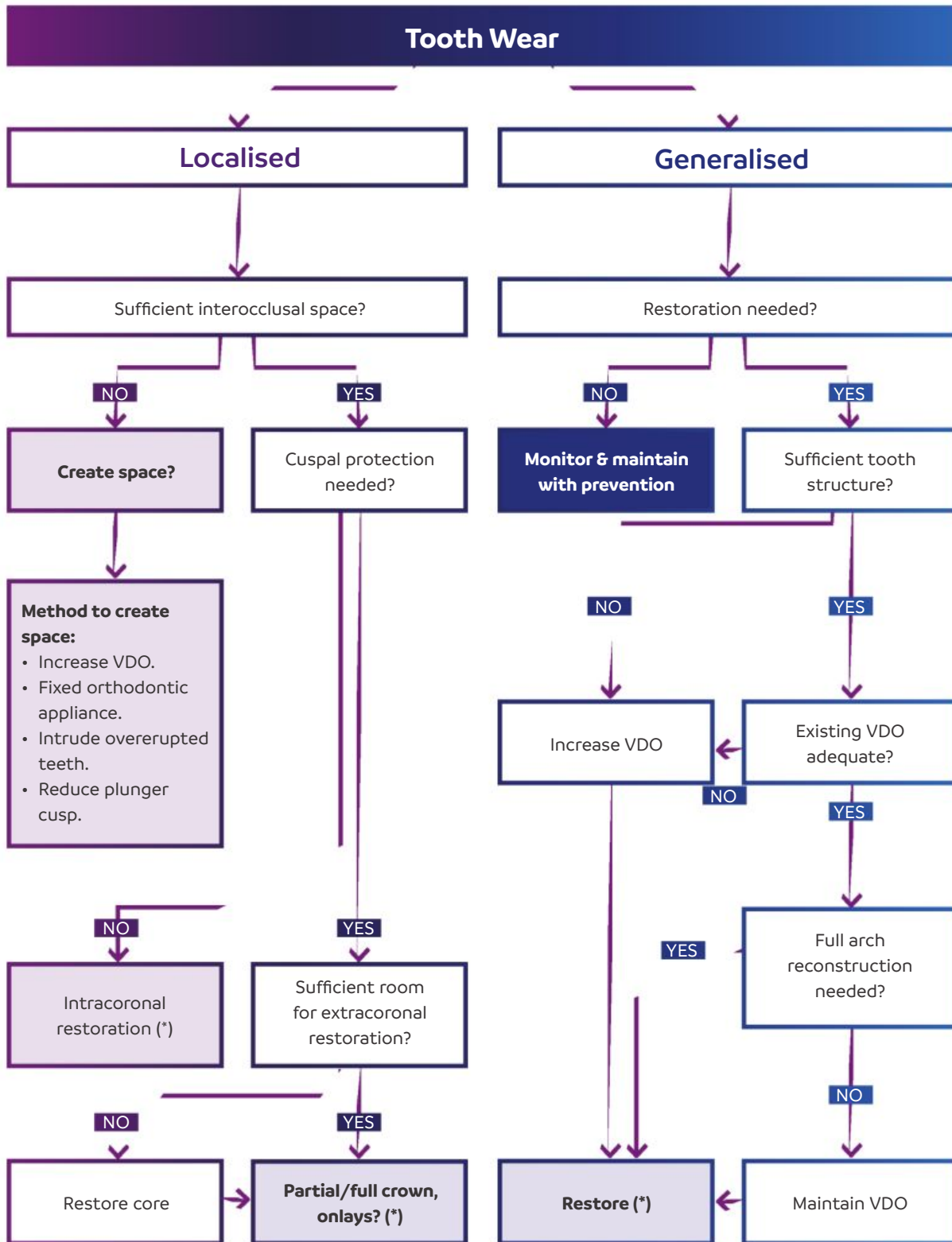
E. INITIAL TREATMENT:

- Consider exodontia for irreversible root fracture, hopeless prognosis for periodontally involved teeth, retained roots.
- Replacement of failed restorations.
- Relevant interdisciplinary consultations.
- Provisionalisation (if appropriate).
- Conservative orthodontics (sequential aligner therapy).

Treatment of Wear (Conservative)

Erosion	<ul style="list-style-type: none">• Eliminate acidic aetiological agent – soft drink, fruit juice, wine, pickled vegetable.• Rinse with water during times of acid exposure e.g. after bulimic episode.• Use remineralising products – fluorides, casein-derived pastes with Recaldent™ (CPP-ACP).• Recommend regular low dose fluoride mouthrinse used 3x/day. Or recommend regular placement of fluoridated toothpaste on the tongue and spread around the mouth without rinsing. Do not swallow.
Attrition	<ul style="list-style-type: none">• Night splint.• Stress management.• Apply Tooth Mousse™ as a lubricant over occlusal enamel and dentine.
Abrasion	<ul style="list-style-type: none">• Identify abrasive dentrifices, foods, foreign objects, habits. Make patient aware.• Restore full complement of occluding teeth.

Protocol for Tooth Wear Management



Note: (*) All-Ceramic / Metal-Ceramic / Metal
VDO: Vertical Dimension of Occlusion

F. RE-EVALUATION FOR COMPREHENSIVE DEFINITIVE TREATMENT

General principles have been outlined for the planning of treatment (Garavaglia, G., et al., 2012):

- Improve the tooth (abutment) prognosis – retreatment options, treatment reversibility and conservation of tooth structure must be included in the context of tooth prognosis.
- Utilise adhesive restorative procedures that can assist with compromised retention and resistance forms and may avoid possible endodontic treatment for prosthodontic needs.
- Aim to segment prosthetic structures into single units and short fixed bridges e.g. a 3-unit implant-supported fixed prosthesis can be redone if problems occur without compromising the entire case (Pjetursson, B.E., et al., 2004, Jung, R.E., et al., 2008).
- A tooth-supported bridge, particularly on non-vital abutments, is usually a less desirable treatment option than a single implant to replace a missing tooth (Randow, K., et al., 1986).

G. AESTHETIC DIAGNOSTIC CONSIDERATIONS:

- Dental aesthetics (e.g. tooth size, form, colour, alignment, gingival display).
- Shade evaluation.
- Occlusal analysis.
- Diagnostic wax-up (including Digital Smile Design).

H. CASE PRESENTATION APPOINTMENT

“The correct presentation of a treatment plan is an essential component of fostering a good dentist-patient relationship” (Bain, C.A., 2004).

- The case presentation appointment should occur in a dedicated consultation room.
- Review all data prior to the appointment to ensure that all required information and resources are accessible.
- Radiographs can be viewed digitally and are an invaluable visual aid in case presentation.
- Pre-treatment study models and diagnostic wax-ups should be well trimmed and mounted on an articulator.
- Outline warranties and life expectancy of restorations provided by the dentist, laboratories, implant companies or other manufacturers.
- Obtain informed consent with written and signed documentation. This should provide information about all the alternatives for treatment, advantages, disadvantages, risks and relative costs of each treatment alternative, maintenance requirements, payment arrangements and a summary of what happens if no treatment is provided. Provide one copy for patient and file other copy in patient’s clinical records for medico-legal purposes.
- Various patient-mediated concerns – finances, treatment time, anticipated morbidity, surgical exposure, hygiene access and maintenance will all have an impact on the final treatment plan and various options should be presented.

I. COMPREHENSIVE DEFINITIVE TREATMENT

Integration of Interdisciplinary Treatment Plans - multidisciplinary comprehensive treatment plans are now commonplace, which can be time-consuming, and patient motivation is the key (Gurrea, J. and Bollain, I.G., 2016).

This typically may involve:

- Fixed or removable prosthodontics.
- Orthodontic treatment.
- Temporomandibular disorders management.
- Obstructive sleep apnoea management.
- Surgical management.
- Endodontics.

Keep copies of materials used and warranties issued:

- The clinician and the laboratory should each have its own internal processes to track which materials have been used if ever the information were required. Safety Data Sheets (SDS) are available as needed from manufacturers' websites.

J. MONITOR AND MAINTENANCE/RECALL

Customise review appointments in line with risk assessment for caries, periodontal disease and ability to maintain hygiene levels.

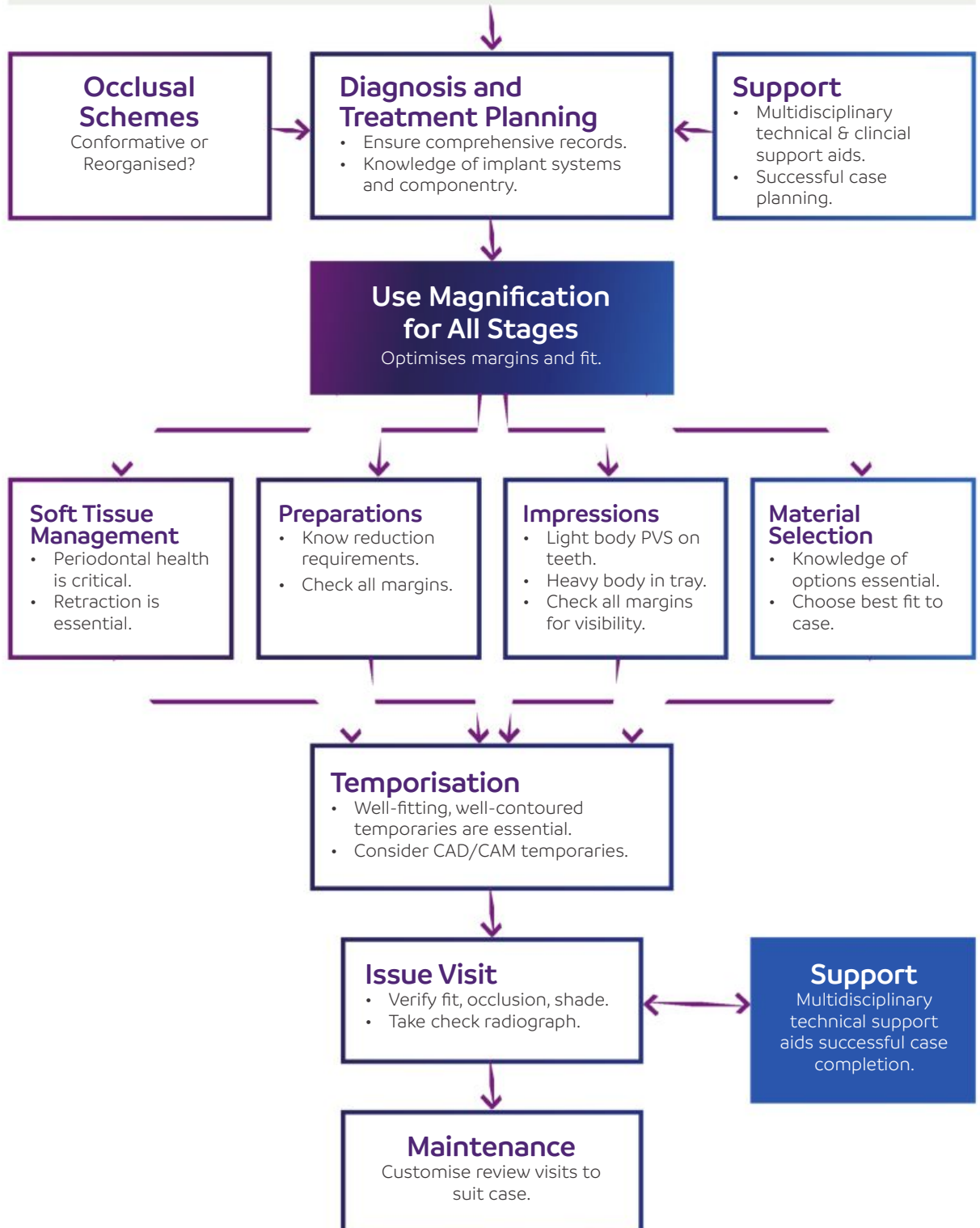
The following patients should be reviewed more frequently (Yip, K. and Smales, R., 2012):

- Children and adolescents.
- Medically compromised patients when general health is at risk.
- Patients at risk of developing dental disease – diabetes mellitus, hyposalivation.
- Lifestyle concerns – excessive smoking, alcohol, cariogenic/low pH diets, acid reflux and GORD, psychosocial stress and anxiety predisposing to bruxing and reduced salivation.
- Challenged patients – physical, mental.
- Extensive restorative work, removable prostheses, implants and orthodontic appliances.

SUCCESSFUL PRACTICE – STAY OUT OF TROUBLE

Case Selection and Patient Assessment

- Know your patient and their expectations.
- Assess patient compliance.
- Remember: Aesthetic dentistry is COSMETIC dentistry.
- Get informed consent and explain treatment options and outcomes.
- Refer psychologically difficult patients for second opinions from specialists.
- Hasten slowly if 'red flags' appear during the consultation.



02

TREATMENT MODALITIES WITH ORAL APPLIANCES




Overview

Do your patients complain of having a fitful or restless sleep? Perhaps they tell you that their family members complain about their snoring? Getting a good night's sleep is a key ingredient to good health, yet it is often overlooked in today's fast-paced world of fitness trackers and vitamin supplements.

As a dentist, you probably also see your fair share of painful cracked teeth. With so many patients living stressful and caffeine-boosted lives, it's little wonder that more and more patients are turning to dental professionals for help.

In this section you'll learn about a range of appliances that are available to help you manage your patients' often complex dental needs. There are now so many ways to provide relief from disorders such as sleep apnoea and bruxism, and new developments in custom-made mouthguards.

Remember, winners are grinners. Knowing which oral appliances and devices are available to you will help you deliver superior care for your patients now and into the future. Now that's news you can use.



TREATMENT MODALITIES WITH ORAL APPLIANCES

Neuromuscular Disorders

Myofascial pain is the most common form of temporomandibular disorder accounting for almost 50% of cases (Manfredini, D., et al., 2011). Commonly, facial pain manifests as multiple symptoms or poorly localised pain that may originate from multiple causes. Possible sources of facial pain are odontogenic, muscular, intracapsular, neuropathic, migraine and referred pain. Complicating accurate diagnosis are patient-specific factors such as an inherent higher sensitivity to pain, psychological and psychosocial disorders, and the patient's ability to describe his or her symptoms accurately (Kotiranta, U., et al., 2014). Treatment success depends on the ability to diagnose the correct cause of the pain or compartmentalise multifactorial pain and treat each component.

Historically, clinicians have treated masticatory myalgia symptoms by using pharmacologic intervention, such as nonsteroidal anti-inflammatory drugs and muscle relaxants, as well as behaviour modification (Baker, J.S., and Nolan, P.J., 2017).

Botulinum toxin is a biological neuromuscular blocking agent. By inhibiting the release of acetylcholine, it causes chemical denervation at the nerve junction and leaves the innervated structure paralysed. It causes a reduction in muscle tone and improved blood flow to muscles (Reilich, P., et al., 2004).

Patients who are suffering Temporomandibular Joint (TMJ) pain and symptoms often experience "clicking", "locking" or internal derangement of the disc and condyle of one or both TMJ joints. The patient can experience pain from the joint areas, along with the muscles of mastication. It is a normal reaction of the muscles to go into painful spasm to help protect an injured joint or joints.

Splint therapy aims to create neuromuscular harmony in the masticatory system and reduce parafunctional forces with removable appliances. The function of a splint is to create harmony in the stomatognathic system. Splints and appliances are used to alleviate the symptoms of Temporomandibular Disorder (TMD). Many splints are used primarily in the first phase of treatment to restore functional harmony. Splints can be made on either arch and provide skeletal support for the mandible and its musculature.

Accurate models of the mouth are needed with a proper jaw registration so the mandible can function and rest in a pain-free position. The appliance is fabricated to a therapeutically constructed jaw registration, which will generally allow remission of pain and symptoms, along with proper joint healing.

Aims of a Splint

Relax the muscles.

Allow the condyles to seat in centric relation.

Provide diagnostic information – if a patient quickly becomes comfortable wearing a splint, then the disorder may indicate a muscular problem. If the symptoms get worse with splint wear, there may be an internal derangement (disc) problem.

Protect teeth and associated structures from bruxism-related damage.

Interrupt periodontal ligament proprioception.

Reduce cellular hypoxia levels.

Alleviate the pain of many types of temporomandibular disorders and bruxism.

ACHIEVING MUSCLE RELAXATION:

- Tooth interferences to the centric relation arc of closure hyperactivate the lateral pterygoids. Posterior tooth interferences during excursive mandibular movements cause hyperactivity of the closing muscles. The elimination of posterior excursive contacts by anterior guidance significantly reduces elevator muscle hyperactivity.
- When a splint has bilateral contacts on all the teeth with immediate posterior disclusion by the anterior teeth and condylar guidance in all movements, then elevator and positioning muscles will relax. Small occlusal interferences of 50µm can cause changes in coordinated muscle activity.

Occlusal splints reversibly alter the occlusion by reducing muscle activity. There is reduced nocturnal electromyograph masseter activity in patients with TMD. Acute or chronic symptoms of muscle hyperactivity were reduced significantly when worn for 24 hours.

Splint Types and Functions

All splints can be classified as either permissive or non-permissive.

Permissive

Can let the teeth move on the splint unimpeded, which then allows the condylar head and disc to function anatomically.

Includes:

- Bite planes.
- Anterior jigs.
- Lucia jig (Dr Victor Lucia).
- Anterior deprogrammer.
- Stabilisation splints (flat plane – i.e. Michigan [Michigan University USA] and Gelb [Dr Harold Gelb], Tanner [Dr Henry Tanner]).

Non-permissive

Has a ramp or “indentations” that places the mandible inferiorly and anteriorly and keeps it there – e.g. anterior repositioning appliance.

Anterior repositioning splints aim to “recapture” the discs by protruding the mandible forward until the condyle has popped back and “locked” into position.

This may be an appropriate treatment for short-term use (no more than 10 days) in trauma cases.

Materials Used

Occlusal splints are traditionally constructed of hard acrylic resin. Cushion-like polymer materials are now available that may be suitable in appropriately selected patients. Splints can be made of all acrylic or a combination of a hard exterior and internal soft lining.

OCCLUSAL SPLINTS

Splint Type	Characteristics
<p>NTI-TSS® Splint (Nociceptive Trigeminal Inhibition Tension Suppression System)</p> 	<ul style="list-style-type: none"> • Fits on the upper front teeth and aims to prevent tooth clenching and grinding. • Fits on only a few teeth, placing a great deal of stress on them. • Poses a risk of being aspirated or swallowed if it dislodges from the teeth, due to its small size. • Useful as a diagnostic splint and recommended for short-term use only.
<p>Gelb Splint</p> 	<ul style="list-style-type: none"> • Popular mandibular splint with acrylic coverage over the posteriors. A metal lingual bar is usually the major connector, which allows for plenty of tongue room. • Occlusion on the Gelb splint involves upper lingual cusps touching a lower flat or indented occlusal pad. The Gelb splint should be made to a centric occlusion (CO) jaw registration. • Designed for closed-lock cases, it is often used in conjunction with muscle relaxers or anti-inflammatory medication. The patient needs to relax the disc before moving to a mandibular advancement splint. Patients should be seen every 30 days to check the range of motion. • A modified design covers the lower anterior teeth to prevent movement or shifting of lower anteriors (flat plane splint).
<p>Michigan Splint</p> 	<ul style="list-style-type: none"> • The standard hard Michigan appliance has an anterior ramp for posterior disclusion and canine guidance. • Soft or hard/soft versions are also available for increased patient comfort.
<p>Cushion Splint</p> 	<ul style="list-style-type: none"> • New designs ensure comfort and patient compliance by fabricating all of the classic designs of TMD splints in a patented cushion-like polymer that is hard wearing, totally elastic and kind to the periodontal ligament. • Soft or hard/soft versions are also available for increased patient comfort. Soft splints and hydrostatic splints (Aqualizer®, Jumar Corp.) can be thought of as pseudo-permissive splints. They function differently from permissive splints.

Laboratory Instructions

Ensure the laboratory is provided with any special instructions specific to the manufacture of the intraoral appliance.

TYPES OF OCCLUSAL SPLINTS

	Flat Plane	Michigan	NTI-TSS®	Gelb
Comfort	✓	✓	✓ ✓ ✓ (small)	✓ ✓ (lingual bars – more tongue space)
Longevity	✓ ✓ ✓	✓ ✓ ✓	✓ ✓	✓ ✓ ✓
Cost	low	low	low	low
Anterior Deprogramming	limited	✓ ✓	✓ ✓ ✓	limited
Term of Use	any	any	short	any
Material Options	hard/soft hard soft	hard/soft hard soft	hard/soft	generally hard
Cushion Splint	✓	✓	limited	limited
Ease of Fit	✓ (easy for elastomer and hard/soft) ✓ (harder for all hard)	easy for elastomer and hard/soft	easy	medium

MATERIAL SELECTION FOR OCCLUSAL SPLINTS

	Hard	Hard/Soft	Elastomer
Comfort	✓	✓ ✓	✓ ✓ ✓
Longevity	✓ ✓ ✓	✓ ✓	✓ ✓
Cost	✓	✓	✓ ✓
Ease of Fit	✓	✓ ✓	✓ ✓ ✓ (easiest)
Cushioning	✓	✓ ✓	✓ ✓ ✓
Staining	✓	✓ ✓	✓ ✓ ✓
Effectiveness	✓ ✓ ✓	✓ ✓ ✓	✓ ✓ ✓
Ability to be Repaired	✓ ✓	limited	limited

Sleep Bruxism

Sleep bruxism (SB) is considered a common sleep-related motor movement disorder. The electromyography (EMG) pattern of SB is associated with repetitive and recurrent episodes of rhythmic masticatory muscle activity (RMMA) of the masseter and temporalis muscles that are usually associated with sleep arousals.

American Academy of Sleep Medicine (AASM) Clinical Diagnostic Criteria for Sleep Bruxism

Patient History	Recent patient, bed partner, parent, or sibling reports of tooth-grinding sounds occurring during sleep for at least 3–5 nights per week in the last 3–6 months.
Signs and Symptoms	<ul style="list-style-type: none"> • Abnormal tooth wear. • Hypertrophy of the masseter muscles on voluntary forceful clenching. • Discomfort, fatigue or pain in the jaw muscles and transient, morning jaw-muscle pain. • Jaw-muscle activity unable to be better explained by another current sleep disorder, medical or neurologic disorder, medication use or substance use disorder. <p>None of these signs and symptoms constitute direct proof of current SB activity.</p>
Diagnosis	<ul style="list-style-type: none"> • Full-night polysomnogram with audio-video recording remains the Gold Standard for SB diagnosis.
Epidemiology of SB	<ul style="list-style-type: none"> • Largely determined by questionnaires, self-reports or clinical findings.
Prevalence	<ul style="list-style-type: none"> • Reported by 8% of the general adult population. • Peaks during childhood (with prevalence approaching 40% in children aged less than 11 years) and tends to decrease after adulthood. • No gender difference observed.
SB	<ul style="list-style-type: none"> • When associated with excessive rhythmic masticatory muscle activity and clenching during sleep, can lead to headaches.
Sleep-Disordered Breathing	<ul style="list-style-type: none"> • Has been associated with sleep bruxism. • Can lead to headaches in the presence of hypoxia and sleep fragmentation.

LINK BETWEEN SLEEP BRUXISM, SLEEP-DISORDERED BREATHING AND TEMPOROMANDIBULAR DISORDERS

Possible* Clinical Consequences Associated with Sleep Bruxism (Balasubramaniam, R., et al., 2014)

Dental	Temporomandibular Disorder	Other
Severe occlusal and incisal wear (chipping), tooth fracture and attrition.	Masticatory muscle hypertrophy* (probably secondary to clenching, awake bruxism, habit or tic).	Lateral border of tongue indentations, scalloping.*
Tooth mobility.*	Masticatory muscle discomfort due to fatigue (may be with or without pain).	Reduction in salivary flow and/or xerostomia.*
Hypersensitivity of teeth to air and cold or hot foods and beverages.	Pericranial muscle tenderness or pain (considered a morning headache in absence of sleep disorder breathing or neurological condition).	Lip, cheek or tongue biting.
“Cracked tooth syndrome” and the frequent breakage of dental restorations.	Stiff tight mandible with reduced movement and/or difficulty with mastication of food upon awakening.	Glossodynia due to parafunctional habits* (probably secondary to clenching, awake bruxism, habit or tic).
Exacerbation of periodontal disease (controversial issue).*	Temporomandibular joint dysfunction or pain.	Excessive concern or anxiety about tooth wear.
Failure of implants due to excessive forces.	–	–

* These relationships are commonly associated with SB by clinicians, based upon clinical experience, but with little evidence of cause and effect relationships (Lobbezoo, F. and Lavigne, G.J, 1997).

Effect of Treatment on Sleep Bruxism (SB), Sleep-Disordered Breathing and Temporomandibular Disorders* (modified from Balasubramaniam, R., et al., 2014)

Treatment	Outcome
Mandibular advancement appliance (MAA) on SB.	Reduction of SB event in the short term.
MAA on snoring, SB and headache.	Reduction of snoring, SB, and headache in the short term.
Maxillary occlusal splint on snoring and OSA.	Aggravation of Apnoea Hypopnea Index (AHI) and snoring in the short term.
Raising the interincisal vertical dimension of a MAA without mandibular protrusion on OSA.	Aggravation of AHI in the short term.
50% advancement of MAA on patients with morning headache without SB and sleep disordered breathing.	Reduction in morning headache and orofacial pain.
CPAP on SB and OSA.	CPAP for possible reduction in SB and OSA.
Adenotonsillectomy in children with snoring, OSA and SB.	Resolution of snoring and OSA. Reduction of SB.

*Most studies are short-term and limited by sample size and results may need replication before being relied upon.

Obstructive Sleep Apnoea

According to the American Academy of Dental Sleep Medicine®, Dental Sleep Medicine focuses on the management of sleep-related breathing disorders (SBD), which includes snoring and obstructive sleep apnoea (OSA), with oral appliance therapy (OAT) and upper airway surgery.

SLEEP APNOEA:

- In sleep apnoea, the airway collapses when falling asleep as the muscles relax. If the collapse is severe enough it causes an apnoea (absence of breath). If it is a partial collapse it usually causes snoring.
- A person with severe sleep apnoea may have hundreds of these events each night, which results in lack of oxygen to the body's vital organs and disrupted sleep. Long-term consequences are high blood pressure and an increased risk of heart attack or stroke and, of course, sleepiness.

According to the National Sleep Foundation of America

Around 22 million American adults have sleep apnoea. It is very difficult at present to estimate the prevalence of childhood OSA because of widely varying monitoring techniques, but a minimum prevalence of 2-3% is likely, with prevalence as high as 10-20% in habitually snoring children. OSA occurs in all age groups and both sexes.

A number of factors increase the risk. These include:

- Small upper airway (or large tongue, tonsils or uvula).
- Excessive weight/obesity.
- Retrognathic mandible/recessed chin.
- Small mandible or a large overbite.
- Large neck size (43cm or greater in a man, or 41cm or greater in a woman).
- Smoking.
- Alcohol use.
- Age 40 or greater.
- Ethnicity (African-Americans, Pacific Islanders and Hispanics).
- Genetic or other inherited/familial factors.

The American Sleep Apnoea Association states:

"It is estimated that 22 million Americans suffer from sleep apnoea. 80 percent of the cases of moderate and severe OSA are undiagnosed.

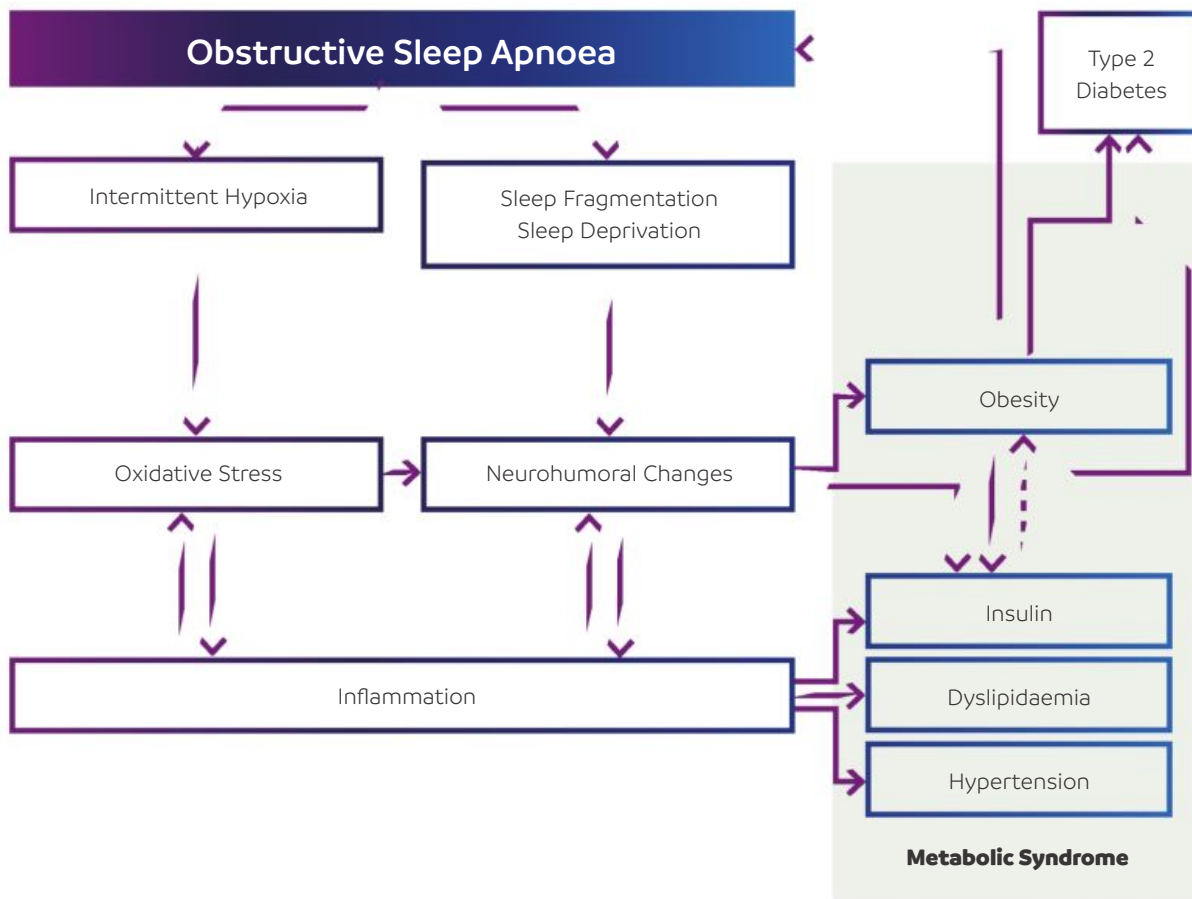
OSA, representing most cases, when left untreated can lead to:

- High blood pressure.
- Chronic heart failure.
- Atrial fibrillation.
- Stroke.
- Other cardiovascular problems.
- Association with type 2 diabetes and depression.
- Many traffic accidents and accidents with heavy machinery, owing to the persistent drowsiness suffered by many OSA patients before the disease is recognised and treated.

Increasing obesity is related to the increase in sleep apnoea. Sleep medicine communities are aware that too little good sleep is as much a factor in obesity as too much food and too little exercise.

OSA can strike people of any age, including infants and children. It is most frequently seen in men over 40, especially those who are overweight or obese".

The chart below details the mechanistic links between Obstructive Sleep Apnoea, type 2 diabetes and Metabolic Syndrome (modified from Tasali, E., et al., 2008).



Until recently, the only management protocol for these patients involved dentists sending their patient to a sleep laboratory or a hospital for diagnosis. This posed a problem for many “sleep dentists,” as patients frequently refused to follow through with this referral. Although a formal sleep study is considered best practice, an option now exists to have this assessment carried out in the patient’s own bed in their own home.

Additionally, those who did go to the sleep laboratory frequently ended up being put on continuous positive airway pressure (CPAP), leaving few, if any, patients for the dentist to treat with oral appliances.

The Role of the Dentist

- Patients now require collaborative input from dentists, sleep specialists, and ear, nose and throat (ENT) physicians. The dentist must work in conjunction with a sleep physician and those other parties involved in the patient’s care.
- Patients typically visit dentists more frequently, and they tend to have more direct contact with their dentists than with primary care physicians.
- Dentists are being urged to play a more central role in screening patients for OSA and related sleep disorders. Teeth show many attributes that identify patients as having an SBD – bruxism, erosion (which may be evidence of GORD), scalloped tongue and other intraoral changes.
- According to Bailey, D.R. and Attanasio, R., 2012, there are five basic questions that can be asked when a dentist takes a health history to help identify the presence of a sleep disorder:
 1. Is there difficulty falling asleep or staying asleep?
 2. Does the patient snore?
 3. Is the patient tired during the day?
 4. Has the patient been aware or told that they stop breathing during sleep?
 5. Is the sleep refreshing?

If there are positive responses to these questions, further evaluation is recommended. Patients should complete the Epworth Sleepiness Scale (ESS), which is a questionnaire commonly used in sleep medicine to assess a patient’s risk for daytime sleepiness and other risk factors, and STOP-BANG questionnaires.

The STOP-BANG Questionnaire	
First four questions	Additional four questions
S: Snore loudly?	B: Body mass index > 28?
T: Feel tired during the day?	A: Age > 50 years?
O: Observed/witnessed to have stopped breathing?	N: Neck size: male ≥ 43cm female ≥ 41cm
P: High blood pressure?	G: Gender: are you male?
YES to two or more of the above: At risk for sleep apnoea.	YES to one or more from above: Increased risk for moderate to severe sleep apnoea.

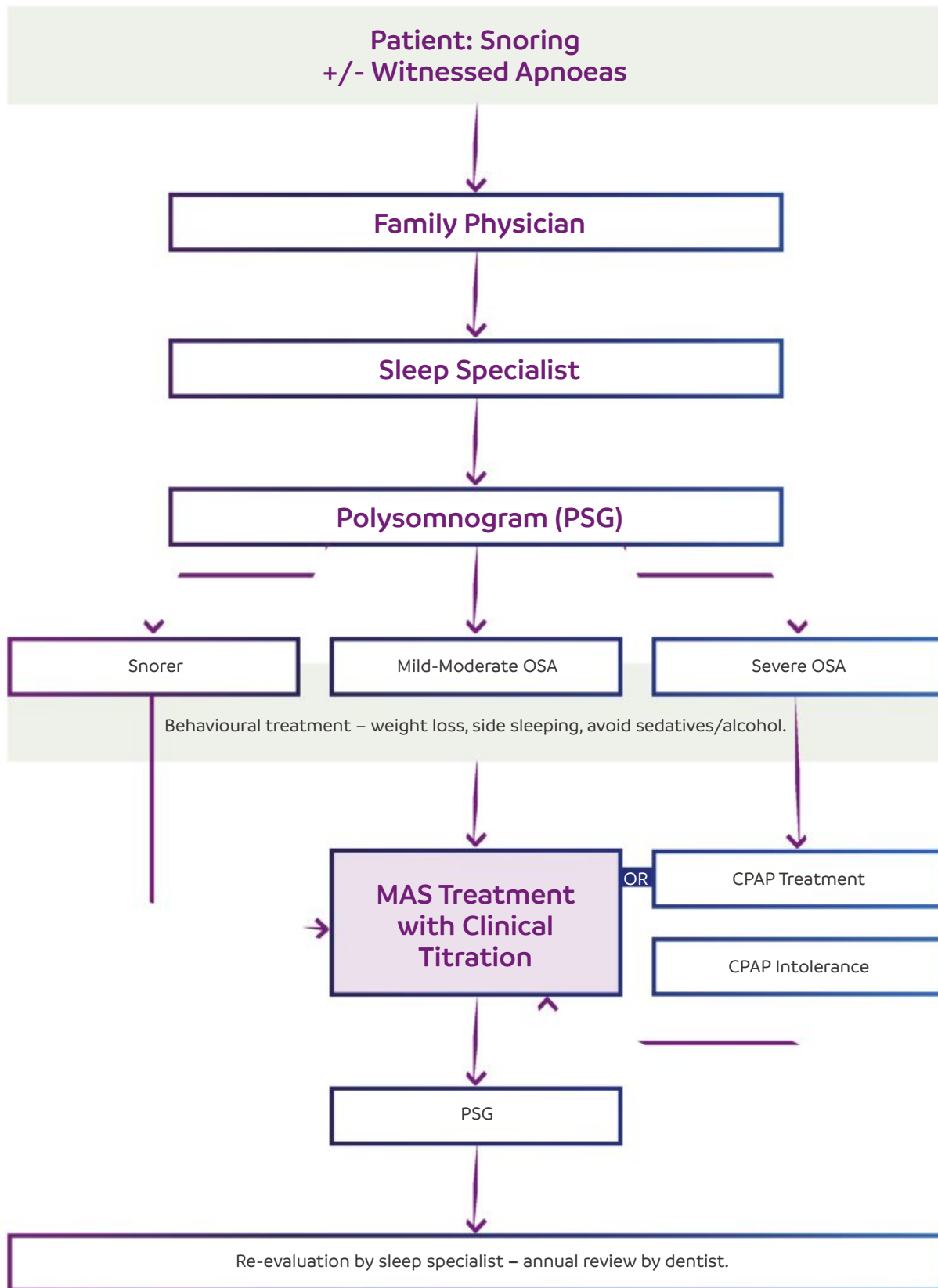
It has been noted by Wright, E.F., 2013 that poor sleep and temporomandibular dysfunction are well-known to often coexist.

TREATMENT OF OSA:

- For mild-to-moderate OSA patients, oral appliances are believed to have equivalent efficacy as CPAP. Compliance for appliances is much higher than with CPAP. Appliances can be used for any OSA patient diagnosed at any severity level, even if the patient refuses to use CPAP.
- CPAP remains the most effective treatment modality for OSA management.
- Some patients with sleep apnoea do not tolerate CPAP and choose surgery to the airway or an oral appliance.

Treatment Algorithm for Sleep Apnoea

(Modified from Pliska, B.T. and Almeida, F., 2012; Ramar, K., et al., 2015)



ORAL APPLIANCES:

- Oral appliances are also referred to as mandibular advancement splints (MAS) or mandibular advancement devices (MAD). Mandibular protrusion opens the airway and prevents collapse through alteration of jaw and tongue position (Sutherland, K., et al., 2014). This in turn helps to reduce either the number and/or the severity of apnoeic events.
- A systematic review by Ferguson (Ferguson, K.A., et al., 2006) found randomised controlled studies comparing Mandibular Repositioning Appliances to CPAP, placebo, other appliances and surgery as well as large case series with comprehensive long-term follow-up. The studies included patients mostly with mild or moderate OSA but some Anti-Snoring Devices studies did include patients with severe OSA. The efficacy of oral appliances was established for controlling OSA in some but not all patients with treatment success (API \leq 10) achieved on average in 52% of patients.

Considerations when Making a Sleep Appliance

1. Degree of Mandibular Advancement:

- Generally, the greater the level of advancement, the better the treatment effect, although this must be balanced against potential increase in side effects.

A study of three levels of advancement (2.0, 4.0, and 6.0mm) found dose dependence in improvement of overnight oximetry (25%, 48% and 65% of patients showing improvement (> 50%) in desaturation, respectively) (Kato, J., et al., 2000).

- In severe OSA, more patients achieved treatment success with 75% compared with 50% maximum advancement (Walker-Engstrom M.L., et al., 2003), suggesting maximising advancement may be more important in managing severe disease.
- A titration approach to determine optimal level of advancement with gradual increments over time is thought to optimise treatment outcome (Fleury, B., et al., 2004).

2. Degree of Vertical Opening:

- Opening of the bite occurs during oral appliance treatment as all appliances have a given thickness causing vertical jaw displacement.
- The amount of bite opening should be kept to the minimum necessary to improve symptoms.

3. Side Effects of Oral Appliance Treatment

In initial acclimatisation to oral appliance therapy, adverse side effects are commonly experienced:

- Salivary fluctuations.
- Tooth pain.
- Headaches and TMD discomfort.
- Occlusal changes.

Adverse symptoms are usually transient, lasting around two months (Giannasi, L. C., et al., 2009). TMD pain and discomfort in the initial treatment period tend to decrease over time and resolve after six to twelve months in most patients (Doff, M.H., et al., 2012).

Long-term persistence of side effects such as mouth dryness and tooth or jaw discomfort may contribute to the need to discontinue treatment (de Almeida, F.R., et al., 2005).

Positive Effects of Oral Appliance Therapy

Studies have demonstrated the following benefits of appliance therapy:

- Improved quality of life such as increased energy level, physical mobility, improved social interaction, enhanced emotional functionality, and quality of sleep (Gagnadoux, F., et al., 2009).
- Reduction of subjective and objective daytime sleepiness in patients with OSA as compared with placebo. This reduction is to the same degree as with CPAP (Lim, J., et al., 2006, Johal, A., et al., 2011).
- Reduction in blood pressure, apnoea-hypopnea index (AHI), snoring index, and sleep apnoea within a short period (three months) which is sustained in the long run (one year) (Bhushan et al. 2015).
- Improved blood pressure levels for at least three years with continued MAS therapy (Andrén, A., et al., 2009).
- A correlated improvement in AHI and a decrease in blood pressure after MAS treatment has also been found when biomarkers of oxidative stress and inflammation were checked. The endothelial function in a MAS treatment group normalised compared with a reference non-OSA group of patients (Itzhaki, S., et al., 2007).
- A slightly higher reduction in AHI by CPAP compared to MAS during a 12-months study following titration for patients with mild to moderate OSA. The improvements in AHI slightly better than MAS. The improvements in AHI were stable over the 12 month time period (Van Haesendonck, G., et al., 2015).

Assessment of Dental Changes with Oral Appliance Therapy:

(de Almeida, F.R., et al., 2005, Doff, M.H., et al., 2012, Martínez-Gomis, J., et al., 2010, Hammond, R.J., et al., 2007)

- Decreases in overbite and overjet – evident six months after initiation of treatment.
- Retroclination of upper incisors.
- Proclination of lower incisors.
- Changes in anterior-posterior occlusion.
Generally occlusal changes are negligible and in over half of patients actually represent an improvement on baseline occlusion.
- Reduction in number of occlusal contacts.

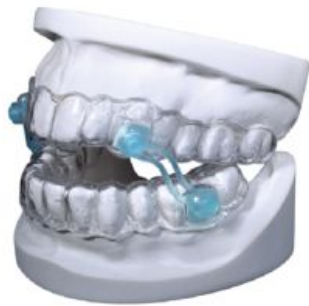The Australian Dental Association (ADA) endorses the AASM protocol as stated in the “Australian Schedule of Dental Services and Glossary, Twelfth Edition 2017”.

Remember:

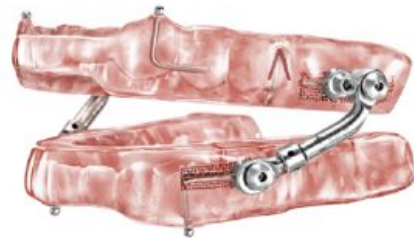The Australasian Sleep Association states:

“Oral appliances of various designs have been used increasingly over the past 15 years to effectively treat snoring and OSA” (Australasian Sleep Association, 2018).

Anti-Snoring Devices		
	Silensor® SL	Respire Medical®
Comfort	✓ ✓ ✓	✓ ✓
Longevity	✓ ✓	✓ ✓ ✓
Effectiveness for Snoring	✓ ✓ ✓	✓ ✓ ✓
Effectiveness for Sleep Apnoea	✓	✓ ✓ ✓
Adjustability/Able to be Titrated	✓ ✓	✓ ✓ ✓
Ability to be Repaired	✓	✓ ✓
Ease of Fit	✓ ✓ ✓	✓ ✓
Suitable for Bruxers	limited	stronger
Potential Mandibular Protrusion	✓ ✓	✓ ✓ ✓
Control of Vertical Opening	✓ (limited)	✓ ✓ ✓



Silensor® SL appliance (Erkodent Erich Kopp GmbH)



The Respire Medical® appliance

O₂VENT™ DEVICES

This is a unique alternative for snorers and sufferers of mild to moderate obstructive sleep apnoea and may offer a suitable treatment to those who cannot tolerate CPAP therapy. Oral devices are not generally accepted as the first line treatment for sleep apnoea. Recent studies have shown that oral devices and CPAP have similar long-term health outcomes (Sutherland, K., et al., 2014).

The O₂Vent™ is a comfortable customised oral device manufactured by CAD/CAM. Using CAD software to create a 3D drawing of the patient's mouth and bite, Oventus then uses 3D printing technology to manufacture a custom-made medical-grade mouthguard from titanium.

The O₂Vent's unique design directs the air flow through to the back of the throat, alleviating multiple sites of obstruction including the nose, soft palate and tongue. The device incorporates a 'duckbill' which extends from the mouth like a whistle and creates a separate airway that allows air to flow directly to the back of the mouth. The device is effective as a stand-alone technology or can be connected to a CPAP machine for more advanced treatment.



This innovative treatment platform is based around an oral appliance featuring the Oventus Airway technology. An Oventus clinical trial showed that 100% of patients experienced a significant reduction in snoring with 82% of patients eliminating snoring completely and 76% of patients reducing their AHI by more than 50% (Lavery, D., et al., 2016).

Xerostomia

Xerostomia is defined as “the subjective symptom of oral dryness whilst salivary gland hypofunction is an objective situation characterised by reduced salivary flow” (Fox, P.C. and Eversole, R., 2001).

It is estimated that 12-47% of the elderly and 10-19.3% of people in their early 30s have been suffering from dry mouth (Guggenheimer, J. and Moore, P.A., 2003). Xerostomia is more common in women than men.

Symptoms of a lack of saliva or oral dryness may be precipitated by dehydration of the oral mucosa (Ghezzi, E.M., et al., 2000), which occurs when output by the major and/or minor salivary glands decrease and the layer of saliva that covers the oral mucosa is reduced (Wolff, M. and Kleinberg, I., 1998, Bretz, W.A., et al., 2000). For further discussion of clinical signs and symptoms of hyposalivation and etiology of xerostomia, refer to Baker, B.H. 2015.

Diagnosis

HISTORY AND EXAMINATION

Proper evaluation and patient assessment should include detailed medical and dental history in order to diagnose salivary gland hypofunction.

The clinical examination should also include extraoral and intraoral findings. The clinician should check and palpate major salivary glands to identify masses, swelling or tenderness.

A positive response to the following questions indicates a link to diminished saliva even with patients who have not expressed concerns of xerostomia:

1. Does the amount of saliva in the mouth appear to be too little?
2. Does the mouth feel dry when eating a meal?
3. Is it necessary to sip liquids to help swallow dry food?
4. Is it difficult to swallow?

DIAGNOSTIC TESTS

Salivary Assessment

Salivary flow should be measured. It can be defined as unstimulated or resting, and stimulated, which occurs when an exogenous factor acts on the secretory mechanisms (Dawes, C., 1987).

Blood Tests

A complete blood cell count can be informative when xerostomia is thought to be associated with systemic disease. Autoantibody screening may be helpful if xerostomia is associated with xerophthalmia, a feature of Sjögren's Syndrome (Fox, R.I. and Liu, A.Y., 2006).

Biopsy

Minor salivary gland biopsy can be used to identify underlying pathological changes associated with salivary gland dysfunction. Histologic changes are one of the criteria used to diagnose Sjögren's Syndrome.

Management of Hyposalivation and Xerostomia

(Guggenheimer, J. and Moore, P.A., 2003)

A multidisciplinary model of care for xerostomia and salivary gland hypofunction should include the following considerations:

PATIENT EDUCATION

A patient-centric regime should highlight preventive measures including daily oral hygiene, regular dental visits, use of topical fluoride, and daily alcohol-free mouthrinse. Toothpastes and gels containing 1.1% neutral sodium fluoride are well tolerated by patients with increased dental hypersensitivity (Bartold, P.M., et al., 2006). Patients with hyposalivation commonly need more frequent maintenance visits (usually three to six months) (Vissink, A., et al., 2010).

COLLABORATIVE PROFESSIONAL INPUT:

- The systemic conditions and medications used should be discussed with the treating physician, oncologist or other health care provider.
- Patients with dry mouth, dry eyes and salivary gland enlargement should be checked for Sjögren's Syndrome as there is a 16-fold increased prevalence of experiencing lymphoma compared with the general population (Kassan, S.S. and Moutsopoulos, H.M., 2004).

CONSERVATIVE MANAGEMENT:

- Maintain adequate hydration – 8-10 glasses of water daily. This should include use of a water-filled spray bottle during the day especially when exercising (Baker, B.H., 2015).
- Use salivary flow stimulants – sugarless chewing gum, sugarless hard candies.

SALIVA SUBSTITUTES/ORAL LUBRICANTS:

- These are non-prescription agents and are available as solutions, dentrifices, sprays or gels.

PHARMACOLOGICAL TREATMENT WITH SALIVARY STIMULANTS:

- Drug therapy uses medications that are cholinergic in their action.
- The drugs most often employed are Cevimeline and Pilocarpine and are approved by US Food and Drug Administration to treat dry mouth due primarily to Sjögren's Syndrome or radiation therapy.

ACUPUNCTURE:

- Patients receive a subjective benefit from acupuncture (O'Sullivan, E.M. and Higginson, I.J., 2010). MRI evidence suggests that neurological responses are elicited by acupuncture (Deng, G., et al., 2008).

FULL DENTURE WEARERS:

- Patients with complete dentures who experience xerostomia are more likely to develop other complications, including pain from denture irritation and loss of retention (Malladi, A.S., et al., 2012). The greater risk of developing candidiasis in edentulous patients may contribute to their discomfort. Soft denture liners or incorporation of metal in the palate of the maxillary denture have been shown to be beneficial treatment options for some patients.

RADIOTHERAPEUTIC INTERVENTIONS:

(Vissink, A., et al., 2015)

- Intensity modulated radiation therapy (IMRT) allows radiation treatment beams of non-uniform intensity to be delivered to the central bulk of disease whilst sparing normal surrounding tissue.

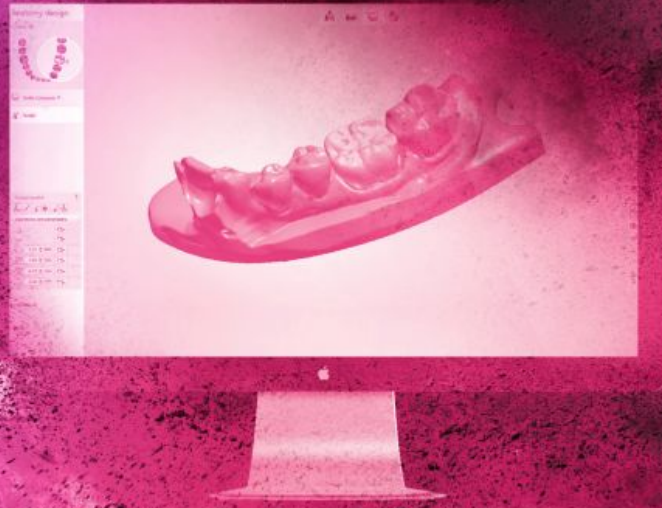ELECTROSTIMULATION:

(Lafaurie, G., et al., 2009)

- An intraoral device for electrostimulation of salivary glands has been developed to treat dry mouth.
- The Saliwell GenNarino® device (Saliwell Ltd., Harutzim, Israel.) is a removable intraoral appliance similar to a nightguard, combining microelectronics, software and wireless communication.

03

DIGITAL DENTISTRY




Overview

Modern dentistry allows you to rethink and improve so many aspects of your care. Gone are the days of x-ray films, where each image took minutes to process. Nor do you still need to concern yourself with the messy process of mixing powders and liquids and two-part composites, or accidentally getting fixer on your clothes.

The same goes for impressions. While the days of hand-mixing rubber materials on ceramic tiles and filling reusable syringes are behind us, impressions don't always go to plan. Obtaining custom trays or finding air bubbles at a critical margin can still be tedious, and it's important to know that better options are available.

Thanks to new technologies, pouring impressions and waiting for couriers is a thing of the past. Scanning, emailing and milling are all possible, even in remote practice locations. Thanks to new digital workflows, you can now get your crown back faster than ever before. This means fewer broken temporaries, happier patients and better cash flow for your clinic.

Understanding how dental laboratories can support your patient care is essential if you are going to harness the real value that digital dentistry can bring to your work day. The modern era of dentistry brings so many benefits for both dentists and their patients. Read on to discover what it could mean for your practice.



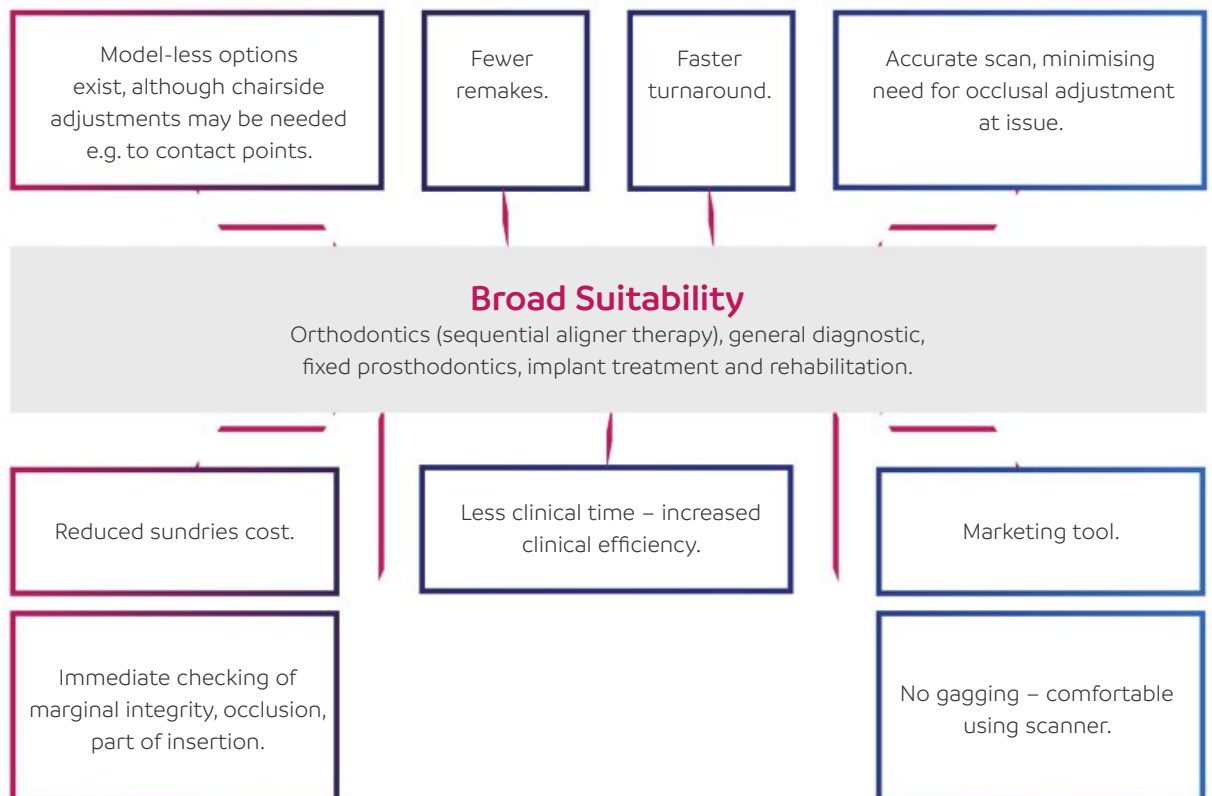
03

DIGITAL DENTISTRY

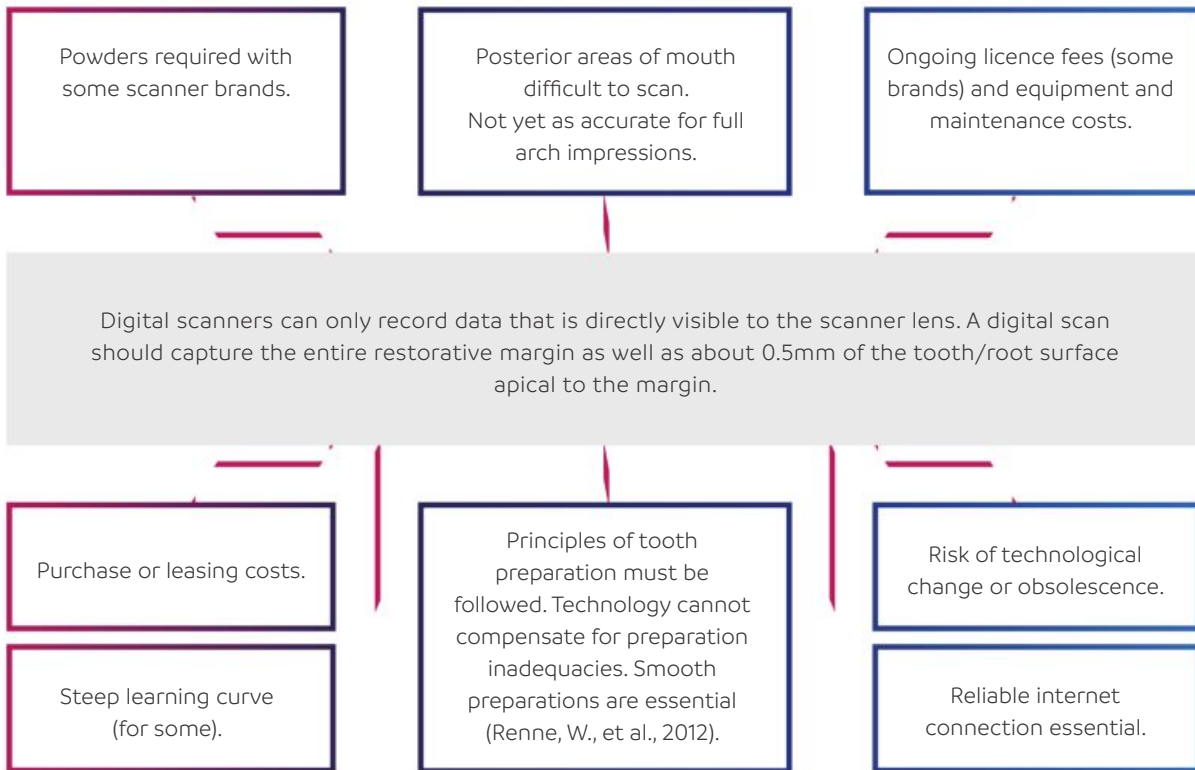
Digital impression units function as a digital replacement for physical impression materials (Schoenbaum, T.R., 2012). Digital scanner systems (intraoral scanners and their associated software) are situated chairside in the surgery and the screen is clearly visible to the clinician.

Digital restorative dentistry is growing in acceptance around the world as clinicians adopt new, more affordable technology that can be used by the entire dental team. Intraoral scanners are integral to digital dentistry. Scanners vary widely in the technology used to produce a digital impression. Many scanners have in-built remote access software (such as Team Viewer or manufacturer-developed programs). Clinicians or other dental consultants can observe the scanning process in real time and offer guidance or troubleshoot/diagnose any issues – so called “teledentistry”. Variability in the accuracy, ease of use, price, file output and application suitability (e.g. sequential aligner therapy) exists between brands. Clinicians should choose the scanner type best suited to the pattern of their clinical practice, their desire to integrate it into their practice workflows (digital or analogue), features, user friendliness and clinical results. The use of digital technology is scalable.

Advantages of Digital Workflow



Limitations and Disadvantages of Digital Workflow



DIGITAL SCANNER SYSTEMS

Digital scanner systems all aim to accurately record the teeth and associated structures, but vary in how they do so and their ease of use. Differences between brands include:

- Type of imaging technology employed e.g. triangulation, parallel confocal imaging, accordion fringe interferometry, or 3D in-motion video.
- The need to use a powder to facilitate scanning.
- Images produced in real colour, colourised images or B&W.
- Size and weight of scanner wand, which can influence accessibility in posterior areas and comfort during use.
- Acquisition time (scanning time).
- Image accuracy (trueness compared to a reference scan, and precision i.e. variability between multiple scans of the same object). The more true and precise, the better.
- Software features, cost and image manipulation options. Clinicians may incur annual licence fees with some brands.
- Type of image file. Some scanners output a file that must first be sent to the scanner manufacturer while others provide a Stereolithography (STL) file that is open source.
- Integration with in-surgery milling systems. Dentists who wish to mill their own restorations will require easy integration to the milling system of their choice.
- Portability – some scanners are mounted on a stand or trolley for easy movement between treatment rooms. Others may connect directly to laptops.

Comparison of Popular Scanners Sending STL Files

(Updated and adapted from Hack, G.D., et al., 2015, Seitz, S.D. and Zimmerman, R.L., 2017)

Scanner	Imaging Technology	Image Type	Wand Size	Measured Trueness* (microns)	Measured Precision# (microns)	Integration Examples	Workstation Type	Other Features
iTero® Element™	Video parallel confocal microscopy.	Coloured	Large	9.8 +/- 2.5	7.0 +/- 1.4	Sequential aligner therapy, Zimmer Biomet, Core3D, Straumann	Cart or tablet and wand	Touchscreen.
3M™ True Definition	LED in-motion video with wavefront sampling.	B&W	Small	10.3 +/- 0.9	6.1 +/- 1.0	Sequential aligner therapy	Tablet-style or cart	<ul style="list-style-type: none"> • Powder needed. • Touchscreen.
Planmeca PlanScan® (E4D)	Real-time laser video streaming.	Coloured	Large	30.9 +/- 10.8	26.4 +/- 5.0	✓ Chairside milling	Built-in dental unit or tablet/PC connection	Easy integration with cone beam.
CareStream Dental CS 3500/3600	Still/video triangulation.	Coloured	Small	9.8 +/- 0.8	7.2 +/- 1.7	✓ Chairside milling	Wand and laptop	
3Shape TRIOS® 3	Ultrafast optical sectioning with confocal laser technology.	Real colour	Medium	6.9 +/- 0.9	4.5 +/- 0.9		Cart or pod to attach to PC	<ul style="list-style-type: none"> • Reads shade of adjacent teeth. • Wireless scanner option. • Touchscreen.
CEREC® AC Omnicam	Full colour video streaming.	Coloured	Large	45.2 +/- 17.1	16.2 +/- 4.0	✓ Chairside milling, sequential aligner therapy	Cart	Battery backup.

* Measured Trueness is the difference compared with an industrial reference scanner – the lower the number the better.

Measured Precision describes reproducibility.

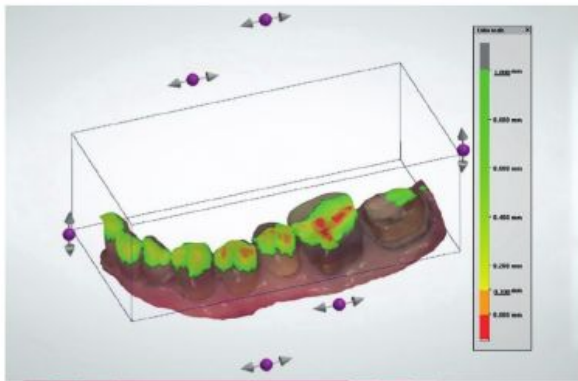
Workflows in Digital Dentistry

Type of Workflow	Process	Considerations
<p>Partial Digital</p>	<p>Clinician pours conventional impressions.</p> <p>Laboratory scans impressions/ model. Restoration made by CAD/CAM.</p>	<ul style="list-style-type: none"> • No added capital expenditure. • Uses familiar materials and techniques. • No increased costs. • Increases access to new restorative materials.
<p>Full Digital (Partner with laboratory)</p>	<ul style="list-style-type: none"> • Intraoral scanner is used to create a digital impression of the patient's teeth. • Digital file is sent to laboratory. • Restoration made via CAD/CAM. 	<ul style="list-style-type: none"> • Capital expenditure needed for intraoral scanner. • Dentist can review scan of preparation, modify and then rescan. • Faster turnaround.
<p>Full Digital In-House (chairside)</p>	<ul style="list-style-type: none"> • Clinician creates digital impression and designs restoration using proprietary software. • Restoration made using mill at practice. 	<ul style="list-style-type: none"> • Capital expenditure needed for scanner, milling unit and associated equipment. • Requires clinical time and expertise to design, mill and characterise – labour intensive for clinician (cost benefit?) • Ongoing maintenance needed for equipment and tool replacement. • Case selection is critical. • Not all materials suitable e.g. zirconia, PFM, PFZ. • Suits demanding patients. • Rapid delivery.

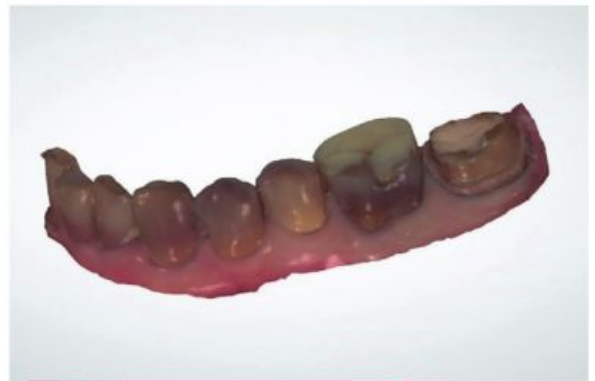FULL DIGITAL WORKFLOW WILL TYPICALLY INVOLVE ACCESS TO:

(Weston, J., 2016)

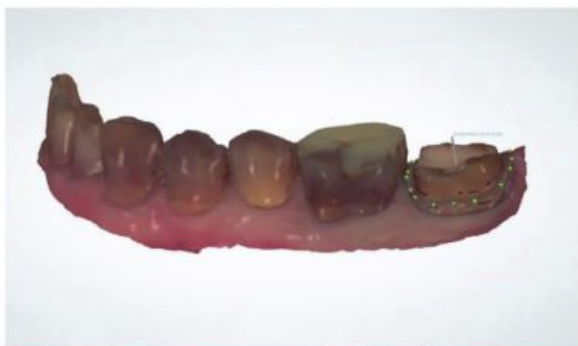- Digital photography.
- Digital radiographs.
- Digital smile design.
- Digital impressions.
- CAD/CAM fabrication.



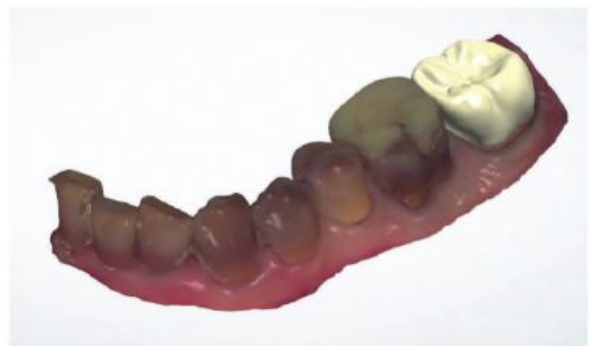Colour scale shows preparation clearance to opposing tooth.



The margin and preparation on tooth 37 are clearly visible.



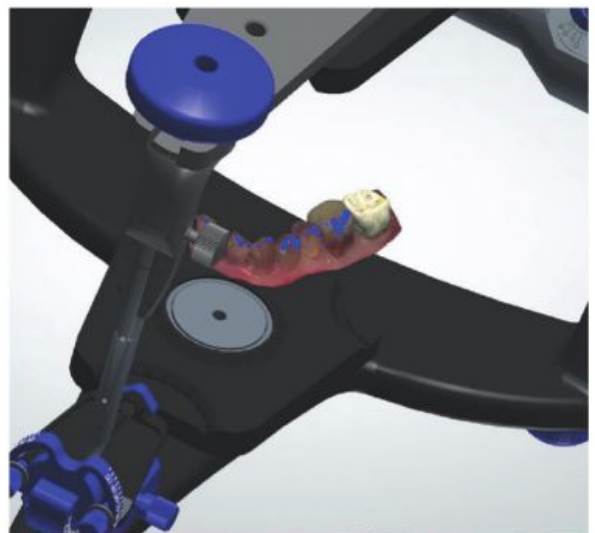
Crown insertion direction is set showing undercuts.

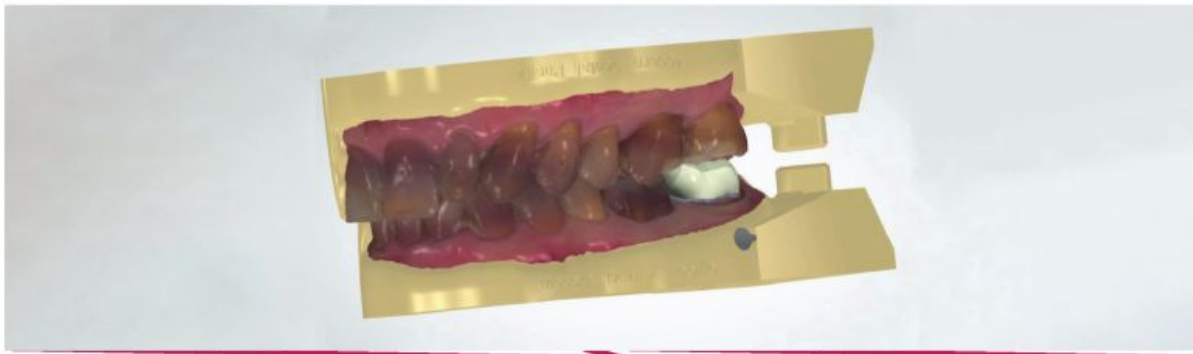

Dental technician designs crown.



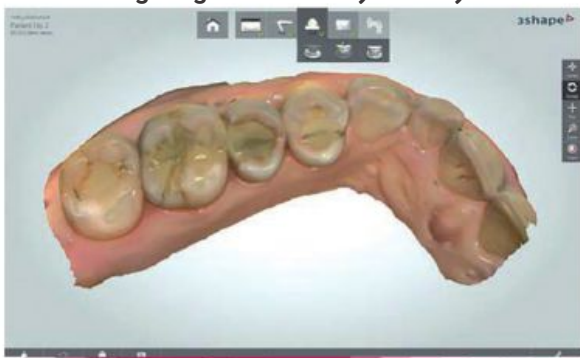Crown design is checked using virtual articulation.



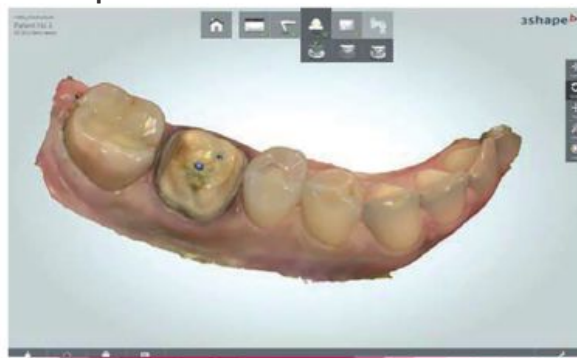

Final crown and model design is ready for fabrication.

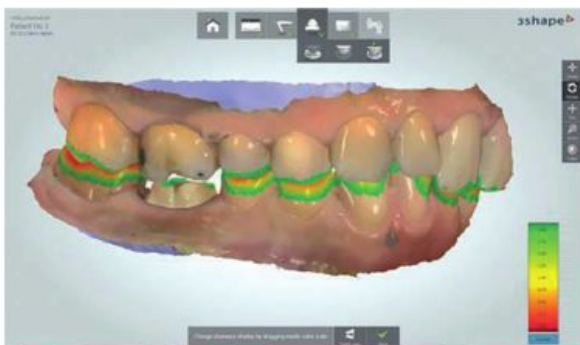
The following images are courtesy of Henry Schein Halas and 3Shape.



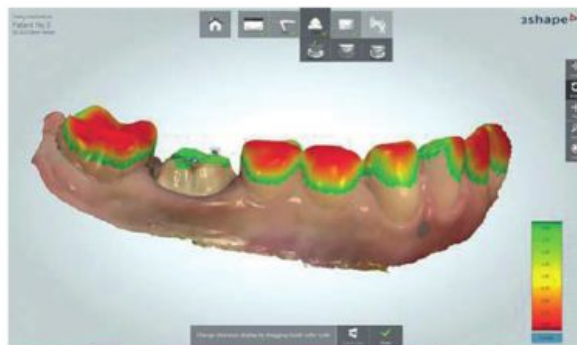
This scan highlights the occlusal scheme on the maxilla.



The margin and preparation on tooth 46 are clearly visible.



The dentist is able to check the occlusal clearance in intercuspal position.

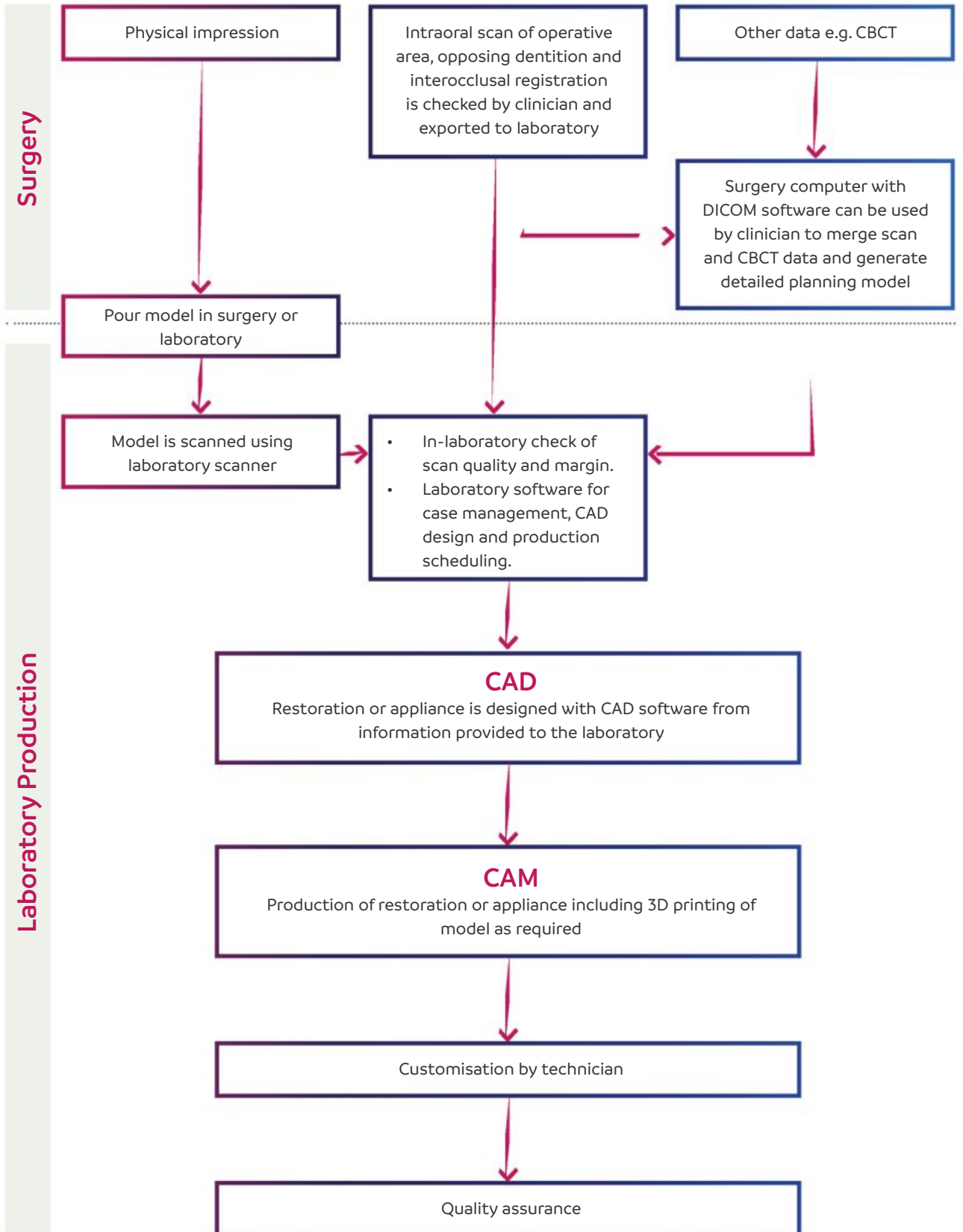


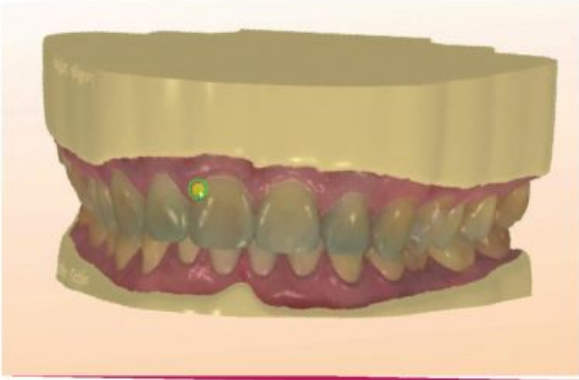
Most systems offer the special benefit of being able to determine the precise occlusal clearance through the use of a digital "colour map". Marking the margins of the proposed restoration can either be done by the dentist or the laboratory.

DIGITAL IMPRESSIONS: AS GOOD AS CONVENTIONAL IMPRESSIONS?

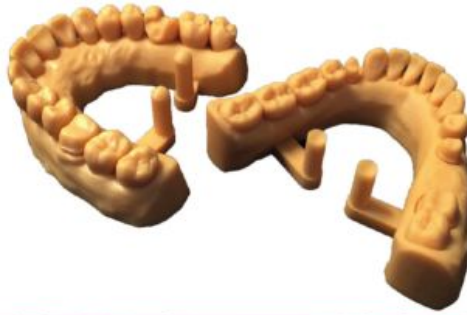
Digital impressions demonstrate the same overall accuracy as conventional impressions for single crowns and bridges but do not yet match conventional impressions for full-arch situations (Ahlholm, P., et al., 2016) (Chochlidakis, K.M., et al., 2016). CAD/CAM bridges made from intraoral scans have been shown to have better internal and marginal fit than those fabricated from conventional impressions (Su, T.S. and Sun, J., 2016). Scanners that do not require the use of scanning powder are considered more convenient to use, as are those that scan in full colour (as this is more effective as a case presentation tool to patients and communication with laboratories).

The Digital Workflow Processes Connecting the Dentist and the Laboratory





Digital model designed using CAD software.



Digital model printed in 3D resin printer.



3D System printer used for printing resin dental models.



Formlabs resin printer used for various dental applications.



This state-of-the-art Rödertec's milling machine routinely delivers superb dimensional accuracy and guarantees consistency.



Precise industrial milling of a zirconia block.



04

THE TAKING OF RECORDS




Overview

Imagine if the only way you could communicate the preparation, shape and margins of a tooth to your technician was through words. It would be a little like someone trying to describe a sunset through letters and numbers. In both cases, we need more information and a better way of communicating to ensure understanding.

Thankfully, today's dental professionals can describe the shape, position, margins and occlusion of a prepared tooth through scans, impressions, study models, bite registrations and photographs. These tools help technicians to understand what is required. Their ability to understand what you require, however, is only going to be as good as the information that you give them. For this reason, the better quality records you send to your lab, the more likely a technician is to deliver what is needed. Similarly, a few shade photographs of a patient's teeth can explain nuances of colour and contour so much better than a little drawing of where different hues may be.

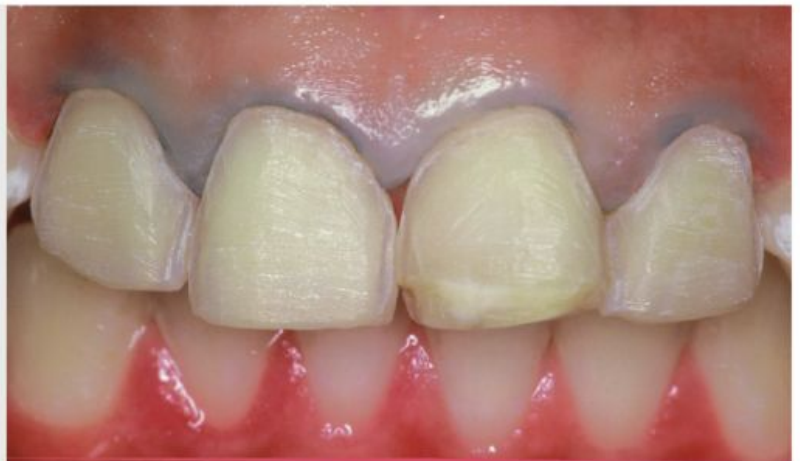Working in partnership with your laboratories and patients is the best way to get the right result first time. As with any relationship, the better you communicate, the more effective you will be. As you delve into the next chapter, we challenge you to consider how you can optimise your communication with your laboratory partners and improve your patient outcomes along the way.



THE TAKING OF RECORDS

The art and science of taking impressions or scans, with their multiple interrelated steps, has many areas where potential discrepancies may be introduced.

A lack of fit most often results from inaccuracies in the impression or scan, some of which may be difficult to detect chairside at the time of record taking.



Veneer preparations.

Soft Tissue Control

A thorough periodontal lead-up should be performed on and around the abutment tooth prior to the preparation and record-taking stages. Many patients present for anterior reconstructive treatment with less than optimal tissue health, varying between mild gingivitis and chronic periodontitis. The use of dental floss, interdental massagers and interproximal brushes is essential to restore and maintain gingival and periodontal health, thereby ensuring:

- Accurate recordings of the abutment and soft tissues.
- Minimal bleeding and the seepage of crevicular fluids.
- Good healing around the temporary restoration.
- A stable gingival height after the final restoration has been cemented.

When soft tissue surgery is required, sufficient time should be allowed for healing. It usually takes six to eight weeks for the tissues to heal and the gingival height to stabilise, but may be longer. Long-term temporaries placed during this time should be removed, cleansed and recemented regularly. This will avoid leakage and sensitivity for the patient and will maintain marginal integrity for the healing soft tissues. Meticulous attention at this time results in good healing and a better patient outcome. The use of mild chlorhexidine gluconate may assist tissue healing.

CLINICAL TIP

Leaving the treatment of unhealthy soft tissues until after the restoration is placed may result in apical movement of the tissues during healing, exposure of the restoration margin and an unaesthetic appearance.

The basics of tooth preparation and soft tissue control apply to both conventional impression taking and to digital scanning.


Tooth Preparation Margins

Where restoration margins are planned to be equigingival or subgingival, tooth preparations should be finished within the gingival sulcus while avoiding damage to the soft tissue in the process. The most atraumatic way to do this is by using end-cutting burs at the tooth margin. Ideally, anterior restorative margins should be at the gingival margin level and both the smile line and the amount of soft tissue visible should be taken into account when planning the margin location.

CLINICAL TIP

Follow the gingival anatomical architecture and do not place interproximal margins in close proximity to the attachment.

Gingival Retraction



CLINICAL TIP

Utilise a quality minimal thickness retraction cord packer at all times. The use of flat plastics can cause irreversible damage to the periodontal attachment.

Good impressions/scans start with good retraction. The cord should be moistened with water prior to removal from the sulcus as removal of dry cord can tear the inner epithelial lining, initiate bleeding and may cause irreversible recession. All retraction techniques should be gentle to maintain the integrity of the gingival attachment.

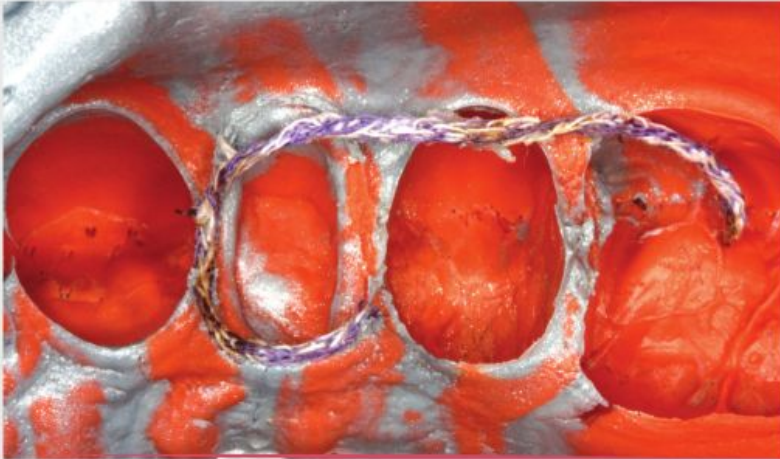
SINGLE-CORD TECHNIQUE

This technique is the most common, but is often insufficient. It is best used when preparing margins at, or above, the gingival margin height. If gingival tissues are healthy and there is no bleeding when the retraction cord is packed, then this is an acceptable method to use. A retraction cord of the appropriate diameter is placed into the gingival sulcus for eight to ten minutes prior to the taking of impressions/scans.

DOUBLE-CORD TECHNIQUE

This technique is best used when tooth preparation margins are subgingival and/or tissue health is less than ideal.

First, gently place an extra-thin retraction cord, such as #000, into the sulcus to provide a slight tissue deflection. This will allow for determination of the sulcus depth, and enable the clinician to check the margins of the preparation and make any adjustments. Then the clinician should pack in braided retraction cord of a size sufficient to adequately displace the tissues and fully expose the margins of the preparation. After a minimum of five minutes the upper braided retraction cord is gently removed, leaving the initial cord in place while the impressions or scans are taken.



CLINICAL TIP

It is easier to respect gingival tissues whilst preparing a tooth than it is to stop iatrogenically induced gingival tissue bleeding.

Retraction cord embedded in the impression needs to be carefully removed to avoid damage to the margins.

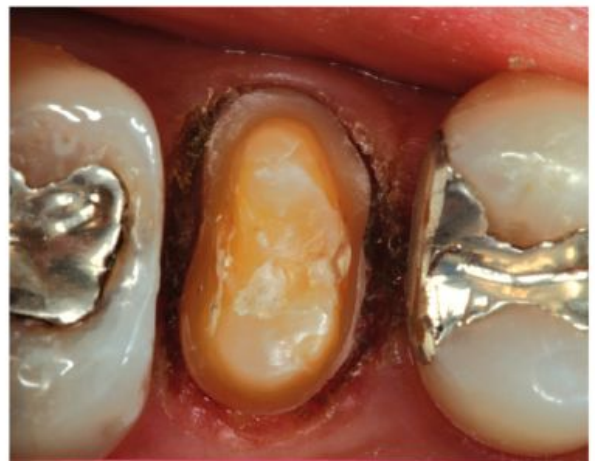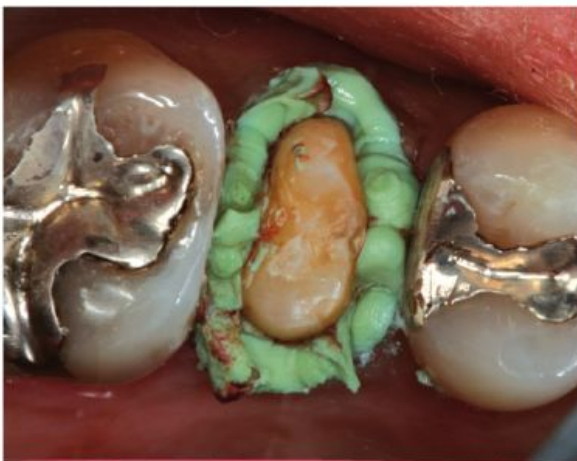HAEMOSTATIC AGENTS

Common products currently used in clinical practice include aluminium sulphate gels, ferric sulphate, aqueous iron chloride, aluminium chloride and zinc chloride. Aluminium and zinc chloride should be used with caution as they are caustic to gingival tissues, especially at higher concentrations, and may also interfere with the surface detail of impression materials.

All astringents negatively affect the bond strengths of adhesives to dentine, and also affect the setting of PVS impression material. Cleaning the preparation with a cavity cleanser such as chlorhexidine slurry, 2% glycolic acid or an EDTA-based gel may help return the bond strength to more normal values and create a cleaner surface for accurate capture of preparation detail in the impression or scan.

The gingival retraction system known as Traxodent™ (Premier Dental) stops crevicular seepage. It contains aluminium chloride and a clay base that attracts and absorbs oral fluids and blood. As this product also displaces the gingival tissues away from the preparation margin, it may allow for a single-cord technique only.

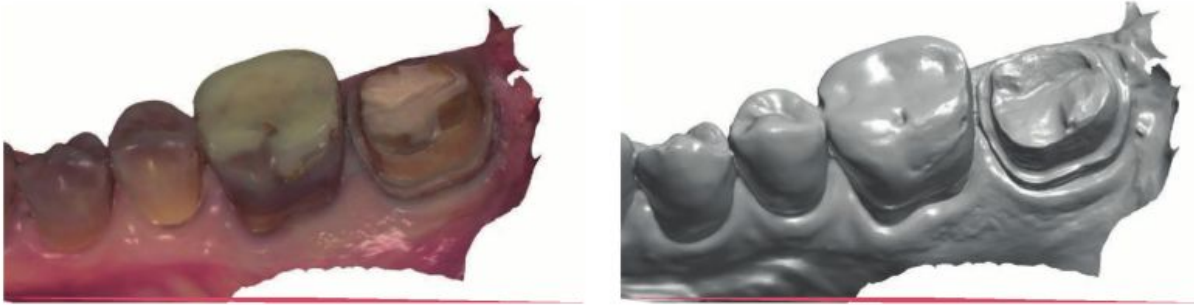
Expasyl™ (Aceton Group) is a fast and painless alternative to packing retraction cord, which may be appropriate for some cases. It has a kaolin (clay) base that is impregnated with aluminium chloride. It is gently introduced into the sulcus around the prepared tooth using a syringe technique, which displaces the gingival tissue. It is left in place for approximately two minutes then rinsed off with a gentle flow of water, then the preparation is dried and the impression/scan is taken. It is a gentle process that eliminates the risk of rupturing the gingival attachment as no instrument packing occurs.



Expasyl™ used prior to taking an impression.

CLINICAL TIP

Haemostatic agents and anaesthetics containing adrenaline can exacerbate undiagnosed cardiovascular conditions. Validating the patient's medical history is important prior to using these products.



Digital impression scan showing clear margins, shown in true colour and grey.

Taking Records – Conventional Impressions – Digital Scanning

Analogue

- Physical impression is taken conventionally in the surgery.
- Dentist sends impression, opposing model and interocclusal records to laboratory.
- Dentist completes laboratory information either digitally or manually.

- Laboratory pours impression then scans model.
- Restoration manufactured.

Digital

- Dentist scans tooth preparation(s) or scan body.
- Dentist ensures sufficient digital information is sent for occlusal registration and prosthesis manufacture.

Digital information sent to laboratory for restoration manufacture.

Analogue Impressions

SELECTION OF IMPRESSION TRAYS

Perforated full-arch metal, rigid plastic or custom trays are recommended for fixed or removable prosthetic restorations involving three or more units, especially for veneers and long-span bridges.

Some Factors to Note:

- Ensure stock or custom tray allow for a minimum material thickness of 5.0mm surrounding the preparation.
- Ensure adequate space between the equatorial line of the tooth and the side of the tray.
- Ensure stock trays align with the arch shape of the patient.
- If a plastic tray is used, ensure the lingual flange is not flexed by the tongue, which would cause distortion by inducing a spring-back effect when the impression is removed.
- Ensure the tray is held in place with constant pressure for the whole setting time.
- Remove the tray in one sharp action once the impression material is set.
- Check all impressions under magnification before dismissing the patient.
- Ensure there are no voids between the impression material and the tray, as unsupported impression material could distort under the weight of die stone when the impression is poured up in the laboratory.

DUAL-ARCH IMPRESSION TECHNIQUE

Studies vary on the accuracy of dual-arch impressions:

- The average occlusal error for articulated casts using dual-arch trays was 5.0 microns compared with an average error of 72.0 microns for mounted casts made from separate full-arch impressions (Parker, M.H., et al., 1997).
- Kaplowitz, G.J., 1997 stated that the use of a flexible tray and flexible impression material had the lowest chance of success.
- Barzilay, I. and Myers, M.L., 1987 showed a clinical case where the alveolar structure displaced the side of a plastic tray and when the side rebounded after removal from the mouth, the die was undersized buccolingually.
- Cox, J.R., et al., 2002 reported that the use of dual-arch impressions with heavy-body material may not be clinically reliable for indirect restorations.
- Shillingburg, H.T., et al., 2012 stated that the technique is best used for patients with:
 - » An intact, mutually protected Angle Class I occlusion
 - » Single tooth restorations, with intact adjacent and opposing teeth, with no arc-of-closure interference into maximum interdigitation.

IMPRESSION MATERIALS

PVS impression material is easy to use and produces excellent results as the dimensional change during the setting reaction is essentially zero. It has good tear strength and wettability. It is provided in a cartridge and syringe system where the base and catalyst are automatically mixed and dispensed when required. Most manufacturers provide heavy-, medium- and light-body materials along with a very heavy-bodied putty. The putty is used to convert a stock tray into a customised tray. The addition polymerising silicones can be used as single-mix, double-mix or putty-wash, depending on each case.

Some Factors to Note:

- Impression material is best stored in a refrigerator (follow manufacturer's instructions).
- Utilising a cooled impression material can extend the working time by about one minute without adversely affecting the material's accuracy (important in warm environments).
- The field must be as free of moisture as possible to capture the most accurate record.
- Dimensional stability varies from brand to brand, with shrinkage over 24 hours being in the vicinity of 0.05%.
- It is best to avoid the use of latex gloves to mix the putty as this can affect the setting of the material.

Features of a Good Impression:

Rigid sturdy impression tray.

Tray adhesive applied thoroughly (when required).

Uniform homogenous mix.

Strong bond between impression material and tray.

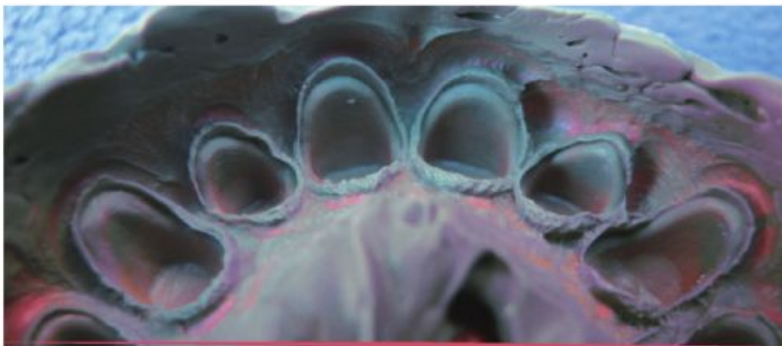
No tooth contact with the tray.

String bond between heavy-body and light-body materials.

No voids or pulls on margin, axial walls or occlusal table.

All margins and axial walls are in light-body material - no 'burn-through' of the heavy-body material.

All margins show clear detail with no tears, voids or rough surfaces.



This impression shows clear margins in light-body material for all prepared teeth.

Summary of Commonly Encountered Problems with Impressions

	Cause	Solution
Surface Inhibition Slow Set for PVS Materials	Sulphur in latex gloves or rubber dam inhibits the setting reaction of PVS.	Wear nitrile gloves or vinyl gloves.
	Touching prepared teeth or surrounding tissue with latex glove.	If contamination suspected, scrub area with diluted hydrogen peroxide.
	Exposure to residues from custom temporary materials.	Fabricate the temporary crown or bridge after final impression has been made.

	Cause	Solution
Lack of Impression Detail	Blood/saliva contamination around preparation.	Rinse and dry preparation before impression.
	Inadequate retraction of sulcus around preparation.	Use good retraction technique with proper moisture control. Use two-cord technique.
	Exceeding the working time of the impression material.	Follow manufacturer's specifications.

	Cause	Solution
Improper Tray Seating	Prepared teeth contacting the sides or bottom of impression tray.	Alter position of tray and pressure to avoid contact of teeth with any surface of the tray.
	Tray seated too quickly or forcefully.	Slowly and gently position tray.
	Tray movement or rocking during the impression.	Use passive pressure to immobilise the tray. Do not let the patient hold the tray in position.

	Cause	Solution
Voids on Margin	Improper syringe technique.	Keep tip immersed in light body (not wash) to avoid trapping air.
	Retraction cord not left in situ for enough time to control bleeding and seepage.	Consider two-cord retraction. Leave cord in sulcus until no blood or saliva is present.
	Air incorporated in intraoral syringe or while filling impression tray.	Keep mix tip immersed in impression materials while filling the tray.
	Blood or saliva contamination around the preparation.	Good retraction technique. Rinse and dry preparation area.
	Poor retraction around preparation.	Consider two-cord retraction.

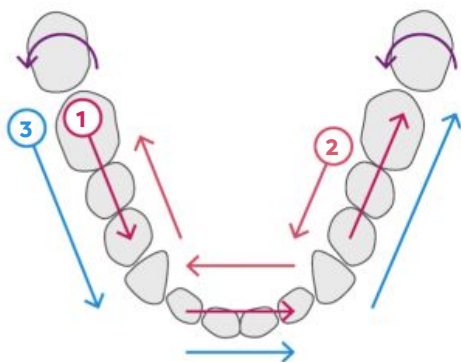
	Cause	Solution
Tearing at Margin	Poor retraction technique.	Consider two-cord retraction.
	Slow-setting material.	Follow manufacturer's specifications.
	Early removal from mouth.	Follow manufacturer's specifications.

Digital Scans

PROPER TECHNIQUE FOR SCANNING

(Weinstein, G.M. and Zientz, M.T., 2017)

- Avoid redundancy whilst scanning.**
This will increase accuracy and reduces file size.




Scanning Technique (Modified from Seitz, S.D. and Zimmermann, R.L., 2017)

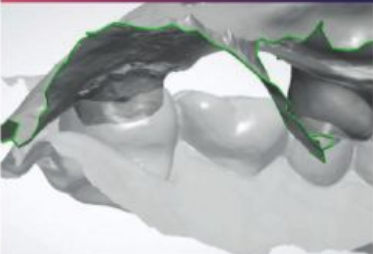
- Start by scanning the occlusal surfaces of the most posterior tooth.
- Move anteriorly.
- Rotate to capture lingual surfaces.
- Move from anterior to posterior.
- Rotate over tooth to capture buccal surfaces.

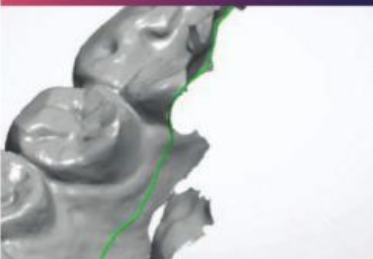
Always complete the scan on the occlusal surface.

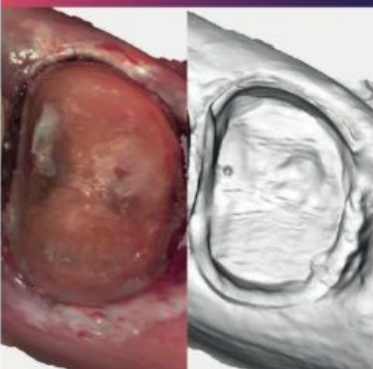
- Tissue retraction is required.**
Ensure that the entire gingival margin is visible.
- Moisture control is essential.**
Ensure the area to be scanned has no blood or saliva present.
- Some scanners require a powder coating on the teeth prior to scanning.**


Summary of Commonly Encountered Problems with Digital Scans


Open Occlusion	Cause	Solution
	Incorrect occlusal records scan.	Check stitching of scan. Extra scanning may be needed.
	Implant scan body left in mouth when completing occlusal records scan.	Remove implant scan body before occlusal records scan.
	Patient biting incorrectly.	Check patient is in correct position.


Superimposed Occlusion	Cause	Solution
	Incorrect occlusal records scan.	Check stitching of scan. Extra scanning maybe needed.


Scan Detail Missing	Cause	Solution
	Insufficient scan.	Scan more of the area needed.
	Saliva contamination.	Rinse and dry before scanning.
	Metallic surface.	<ul style="list-style-type: none"> No overhead light. Apply scan spray (scanning powder). Dry.

Lack of Preparation Detail	Cause	Solution
	Blood/saliva contamination around preparation.	Rinse and dry preparation before scanning.
	Inadequate retraction around preparation.	Ensure adequate retraction technique with proper moisture control. Use two-cord technique.
	No scan spray (powder) used.	Check if surface spray needs to be used in conjunction with the scanner.
	Tissue obscuring margin.	Ensure there is a clear margin.

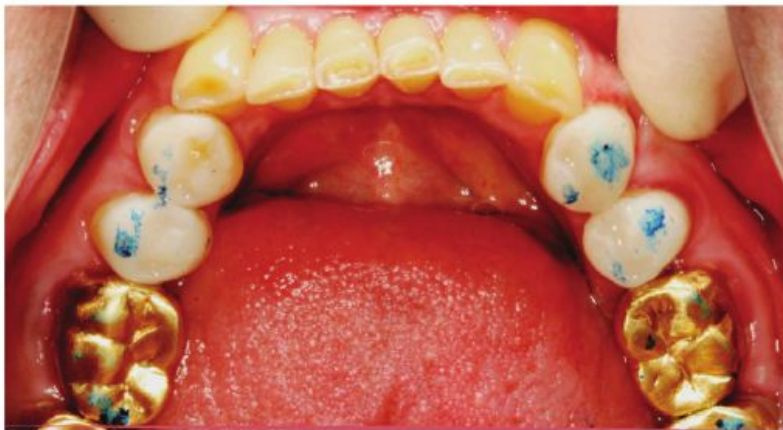Double Scan	Cause	Solution
	<p>Incorrect stitching of scan information.</p>	<p>Delete and rescan affected area.</p>

Digital Scan with Rough Surface and Objects Protruding	Cause	Solution
	<p>Saliva contamination.</p>	<p>Rinse and dry before scanning.</p>
	<p>Cheek or tongue picked up by scanner.</p>	<p>Delete area affected and rescan.</p>
	<p>Scan spray build-up or displacement.</p>	<p>Clean scan spray off and rescan.</p>

Digital Scan with Rough Surface and Some Tooth Structure Missing	Cause	Solution
	<p>Scan spray build-up or displacement.</p>	<p>Clean scan spray off and rescan.</p>
	<p>Saliva contamination.</p>	<p>Rinse and dry before scanning.</p>
	<p>Metallic surface.</p>	<ul style="list-style-type: none"> • No overhead light. • Scan spray. • Dry.
	<p>Faulty scanner calibration</p>	<p>Calibrate scanner.</p>

Scan Body Issues	Cause	Solution
	<p>Scan body too large.</p>	<p>Trim area touching adjacent tooth. Use smaller scan body if available.</p>
	<p>Incorrect scan body used.</p>	<p>Check with supplier of scan body.</p>
	<p>Scan body not fully seated.</p>	<p>Check that scan body has been seated properly by taking a radiograph.</p>

Occlusal Records



Poor interocclusal records almost inevitably translate into some form of occlusal discrepancy in the final restoration(s). The restoration may be too high and require adjustment, although the opposite may occur and the restoration can be out of occlusion. Such errors are magnified the greater the number of prepared units and/or whenever the most distal tooth in the arch is prepared.

Marking the occlusal contacts.

OCCLUSAL ERRORS CAN ARISE DUE TO:

- Distorted impressions.
- Blowing air on the surface of the impression.
- Improper use of facebows and articulators.
- Incorrect/inappropriate use of occlusal records.

INTEROCCLUSAL RECORDS

Restorative procedures that require the mounting of casts need accurate interocclusal records. Casts can be mounted on the articulator so that the relationship between the casts corresponds to the jaw relationship in the patient's mouth in lateral, anteroposterior and vertical dimensions. These relationships are recorded by means of interocclusal records.

Basic "Static" Types of Interocclusal Records

Centric Relation (CR)

This is a "tooth-apart" recording of the retruded arc of closure normally used to carry out a preoperative occlusal analysis. Centric relation is a position determined by the temporomandibular joint. No muscular activity should interfere with the mandibular position.

It can be difficult to record the correct condylar position (usually on the terminal hinge axis) due to loss of proprioception and the musculature may resist manipulation. Consider using a "deprogrammer".

Lateral and Protrusive

Use whenever specific articulator condylar angles need to be set.

Centric Occlusion (CO)

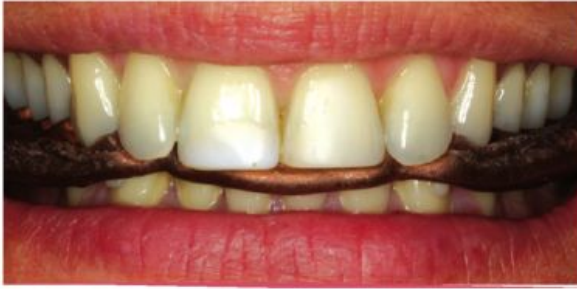Used for mounting preoperative and master models for a conformative occlusion. This is the most commonly taken occlusal record.

If there are disturbances of the natural occlusion such that freehand articulation is not possible, an occlusal record is required.

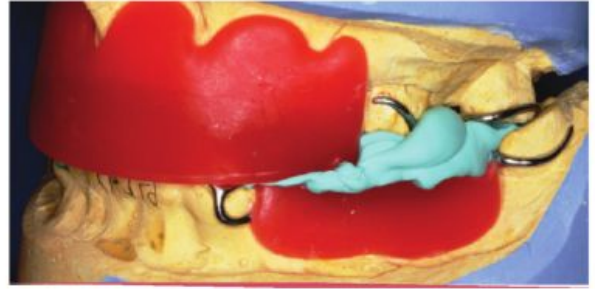
OCCLUSAL RECORD MATERIALS SHOULD:

- Be easy to handle.
- Have low initial viscosity to avoid displacing the teeth/mandible during closure.
- Record sufficient detail to allow accurate orientation of the casts.
- Be rigid when set to stabilise the models during mounting on an articulator.

Examples of Occlusal Records:



Wax squash bite.



Wax rim with polymeric impression record.

More Commonly Used Materials for Occlusal Records

Wax

Often used to record centric relation and for lateral and protrusive records. Pink wax is softened in a flame/hot water and shaped to the approximate size of the occlusal arches.

Wax Squash Bite

- Interferes with the path of closure.
- Easily distorts as wax is thermoplastic and unstable.
- Firm pressure needed to seat the casts, easily leading to distortion, especially if all the teeth have been prepared or are missing on one side of the arch.

Hard Wax

e.g. Moyco Beauty Wax.

Hard wax is preferred and softened in a water bath as this will heat the wax more uniformly. After taking an initial registration, the wax can be cooled thoroughly outside the mouth and relined with either a temporary crown and bridge cement or zinc oxide-eugenol paste to produce a more resilient and reliable record.

Zinc Oxide-Eugenol

ZnOE – refines wax records.

A special hard-setting zinc oxide-eugenol occlusal registration paste is used by spreading the mix onto a gauze mesh in a plastic frame.

Acrylic Resin

e.g. DuraLay™ – Reliance Dental Manufacturing Company.

- Used to make simple interocclusal “stop” records.
- Rigid, so minimal distortion once set.
- Can be used as a vehicle for a more fluid recording material such as ZnOE.

Polymeric Impression

Predominantly polyvinylsiloxanes, e.g. Blu-Mousse® Classic (2-minute set) (Parkell) and SAM – BR Bite Registration (1122Corp).

- Preferred for most clinical situations – especially centric occlusion records.
- Accurate – dimensionally stable.
- Exhibits minimal resistance to mandibular closure.
- Does not require a carrier vehicle.

Polyether

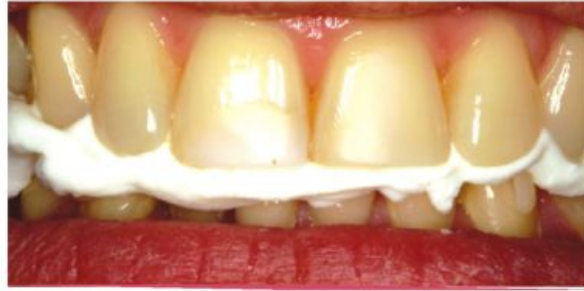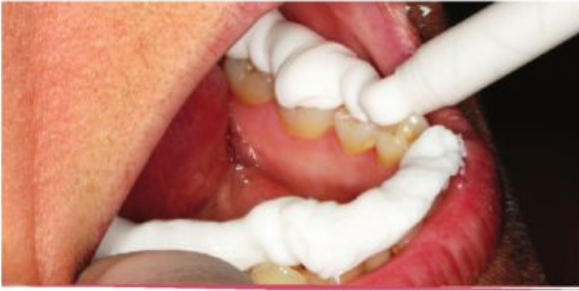e.g. Ramitec™ Polyether Bite registration material (3M ESPE).

Automixing gun with a flat nozzle allows broad band of material to be laid over the occlusal surfaces of the lower teeth.

A SIMPLE METHOD FOR USE WITH POLYMERIC MATERIALS:

(Castellanos, M. and Echeto, L.F., 2017)

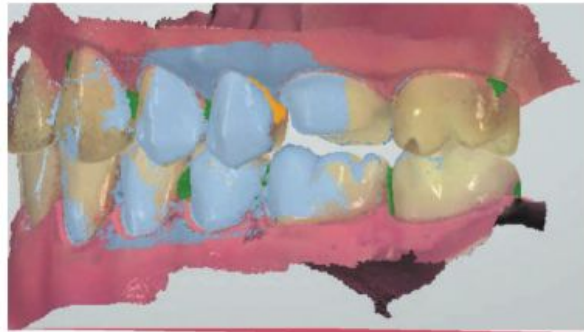
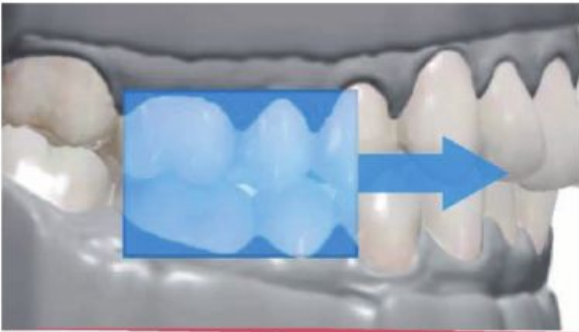
- Place the interocclusal record material on the teeth.
- Close the patient’s jaw into the preferred position (usually centric occlusion).
- Allow the material to set.
- Trim any excess material that touches soft tissue.
- Try the interocclusal record in the mouth to verify its accuracy.
- Ensure the opposing casts are accurate and that they do not have bubbles or other defects on their occlusal surfaces.



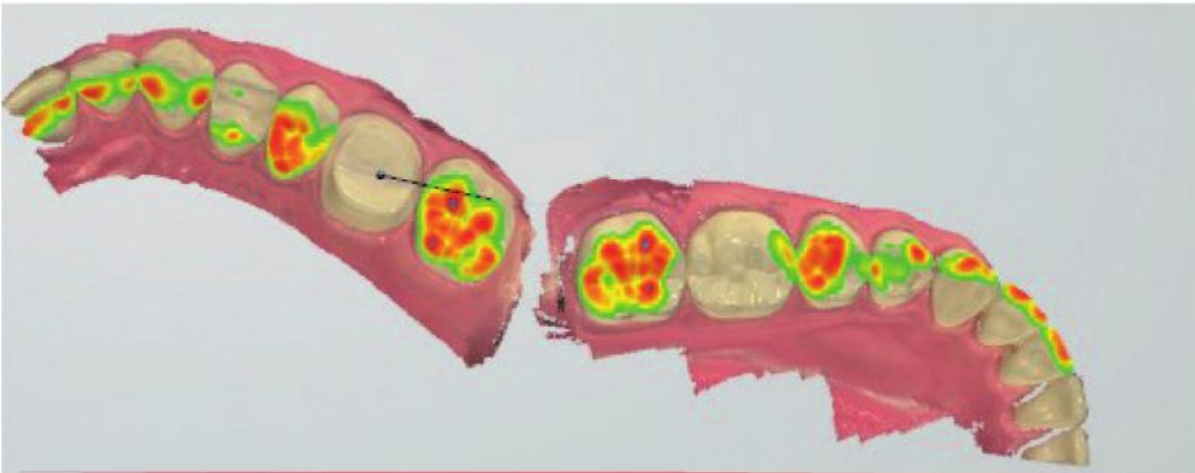
Polyvinylsiloxanes as bite-recording materials are easy to handle.

Digital Occlusal Records

- Follow the recommended scan strategy.
- Establish the occlusion by scanning the buccal surface.
- Start in the posterior region and move anteriorly.



When the scan is correct, the upper and lower scans will be articulated and show the correct interdigitation. Scan a minimum of four teeth per quadrant.



Mark the occlusal contacts using distance map.

Sending Analogue Records to the Laboratory

- Complete all details on laboratory sheet or online.
- Decontaminate all records prior to sending – impressions, occlusal registrations, etc. – ensuring that infection control guidelines have been strictly followed.
- If alginates must be used, pour up impressions within 20 minutes as a two-stage pour. Do not evert alginate and pour a base at the same time, as distortion will occur. Once the stone has set, separate the models. Do not leave alginate in contact with set stone overnight. Ensure models that are sent are securely wrapped to minimise risk of damage in transit.
- As an alternative to alginates, consider use of alginate-like materials e.g. AlginoTM.

Sending Digital Records to the Laboratory

- Complete all details in software or on an online form.
- Ensure all required scans have been captured, including an adequate interocclusal record showing interdigitation of adjacent teeth.

Digital Photography

“Digital dental photography is the standard of care, the standard of practice and the best practice in aesthetic dentistry” (Goodlin, R., 2011).

ADVANTAGES OF DIGITAL PHOTOGRAPHY:

- Images can be transferred anywhere over the internet.
- Images can be added directly to practice management programs as part of the patient record to document case progression and each surgery visit (“before” and “after”).
- Enables more comprehensive communication and description of a case to the technician.
- Illustrates shade tab information and shade of the abutment and adjacent teeth.

PHOTOGRAPHS FOR A COMPLETE ASSESSMENT

Full face.	Full smile.
Right and left lateral smile.	1:1 right and left lateral.
Anterior retracted closed.	1:1 anterior retracted.
Right and left retracted.	Maxillary and mandibular occlusal (mirror required).

Dental imaging software can be used both to present a case to the laboratory and to show a patient’s potential results via computer imaging.

Aesthetic Diagnostic Considerations

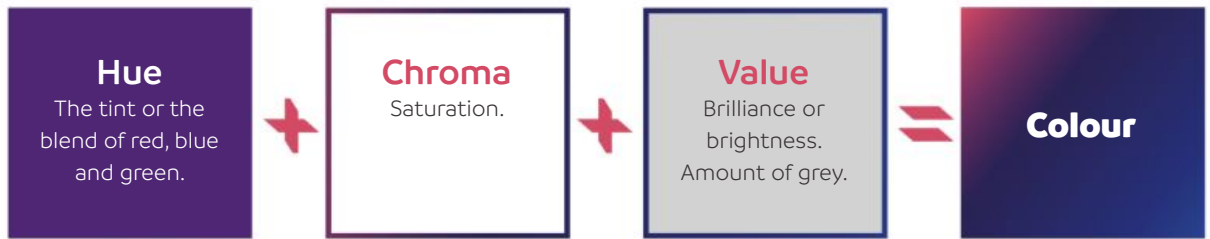
Aesthetics has now entered the arena of interdisciplinary dentistry (Ali, J., et al., 2013). The liaison of a dentist working closely with a quality-conscious ceramicist will enable the dentist to achieve tangible aesthetic success on a predictable and regular basis (Weston, J.F. and Haupt, E., 2011).

Dental Aesthetic Checklist

(Greenberg, J.R. and Bogert, M.C., 2010)

Facial Midline (FM) = Dental Midline	The dental midline should be perpendicular to the incisal and occlusal plane and parallel to the facial midline. The facial midline requires two reference points – nasion and the base of the philtrum. A line that connects these two landmarks should illustrate the FM and the direction of the FM (facial vertical axis).
Facial Vertical (FV) = Dental Vertical	The dental vertical axis should be parallel to the facial vertical axis.
Facial Horizontal (FH) = Dental Horizontal	The interpupillary line, eyebrows and commissural line define the facial horizontal. The incisal edge line (incisal plane) of the upper anterior teeth and the buccal cusps of the posterior teeth visible in a wide smile should be symmetrical to the facial horizontal.
Check if Both Maxillary Central Incisors are Equal in Position, Symmetry, Colour and Shade	<ul style="list-style-type: none"> • Width/length ratio (ideal is between 0.75-0.8). • Chu's Aesthetic Gauge™ (Hu-Friedy) can be used to establish the 78% width/length proportion of maxillary central incisors. • Review mesiodistal width of incisors and mesial aspect of canine (based on Golden Proportions of 0.618). Are both maxillary central incisors located at FM/FV/FH?
Incisal Edge Line of Upper Anteriors to Edge of the Lower Lip	Does the incisal edge line of the upper anteriors follow the upper contour edge of the lower lip?
Assess the Incisal Edge Line Form – Convex, Gull-Wing or Straight?	<p>Evaluate the relationship of the lip space to the dentition in a “broad smile” and get patient to bite tightly and say “E”:</p> <ul style="list-style-type: none"> • High lip line – >4.0mm gingival display apical to cervical gingival margins. • Normal lip line – 0.0-3.0mm of gingival display. • Low lip line – lip covers all the gingiva and/or maxillary anteriors.
Profile	Check relationship of anterior teeth to patient's facial outline profile.
Phonetic Screening	<p>Ask patient to:</p> <ul style="list-style-type: none"> • Repeat “F” and then “V” to test position of maxillary incisal edges. • Say “S” whilst upright to check occlusal vertical dimension and freeway space. • Say “E”, which shows the widest smile. • Say “M”, to view the physiologic rest position. The minimum facial display of anterior teeth for a youthful smile is between 2.0mm and 4.0mm.
Shade Selection	Staining? Discolouration?
Evaluate Tooth Surface Loss	Wear facets, erosion and vertical enamel fractures.
Check Alignment	Overbite, convergence of long axes mesially from incisors to canines and crowding/rotations/crossbite.
Assess Soft Tissue	Gingival shape, symmetry, black triangles, biotype, contact point position.

Three Definitions Describe Colour:

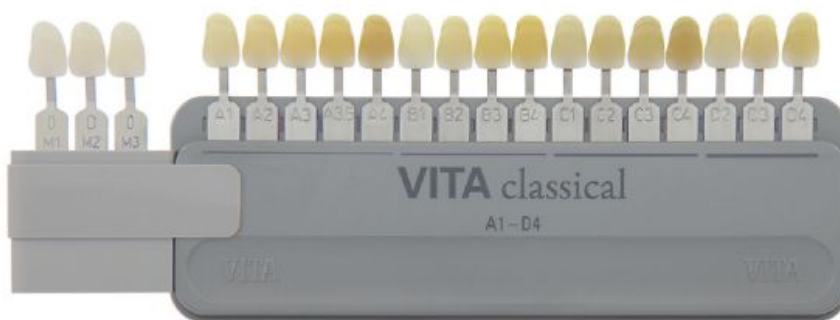

Shade Selection

- Avoid brightly coloured neck napkins or bibs – use a light blue neck cloth.
- Ask patients to remove lipstick or obstacles (hats or scarves) that may affect the light.
- Schedule ceramic restoration appointments early in the morning to avoid eye fatigue.
- Take the shade before preparing the teeth.
- Pick the value first and then pick the hue range.
- Fan the shade guide past the patient's mouth and pick the closest tab. Do not stare. Rest your eyes occasionally.
- Compare shades in more than one light, preferably one of them being natural light. Errors in value are most easily noticed in sunlight. Avoid fluorescent lights, which throw off the hue.
- Specify characterisation clearly with a drawing and/or digital image.
- For all-ceramic anterior restorations, record the stump shade using a guide specifically designed for that purpose. This greatly helps the technician to determine the opacity/translucency of the ceramic required.
- Take photographs of the nearest-matching shade tabs with the tabs held in the same plane as the incisal edge/buccal surface of the tooth.
- Seek a second opinion. Ask your nurse or receptionist to take a shade.

CLINICAL TIP

Always disinfect shade guides to minimise the risk of cross-infection.



Vita Classic shade guide showing bleach shade tabs.

AESTHETIC ANALYSIS

(ALI, Z., et al., 2013)

Assessment

Extraoral

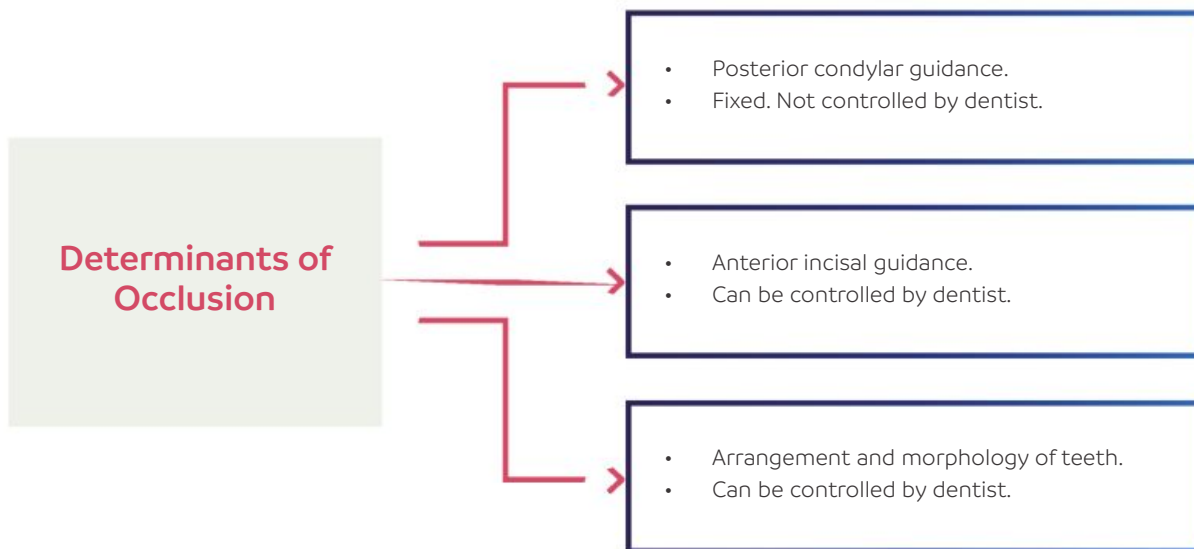
- Dentofacial.
- Lips – incisal display.
- Smiling position – midline, incisal lines.

Intraoral

- Shade – staining, discolouration.
- Evidence of tooth surface loss – wear facets, erosive wear, abrasion, enamel fracture.
- Tooth shape proportions – width/length ratio, labial tooth anatomy.
- Alignment – amount of overbite, axial inclination, crowding, rotation, cross bite.
- Gingival aesthetics – symmetry, black triangles, position free gingival margin, biotype.
- Bony anatomy.

OCCLUSAL ANALYSIS

Occlusion refers to the functional and dysfunctional relationships between all components of the masticatory system.



OCCLUSAL ASSESSMENT OF MOUNTED CASTS:

- Casts are mounted on semi-adjustable articulator with accurate CR record.
- Check firmness of the individual opposing tooth contacts with Shim Stock or articulating foil.
- Locate and mark any interfering contacts during mandibular movement.
- Vertical dimension evaluation.
- Accurate and easy measurement of residual alveolar ridges and interproximal spaces.
- Assessment of available interocclusal space/space in the implant receptor site.
- Aesthetic analysis as it impacts on occlusion.

Occlusal Considerations (Wang, Y.L., et al., 2011):

Centric Relationship	The relationship of the mandible to the maxilla when the condyles are in the most anterosuperior position in their respective glenoid fossae with the articular discs properly interposed.
Centric Occlusion	The position of the mandible that results in maximal interdigitation of the maxillary and mandibular teeth.
Eccentric Occlusion	Lateral working side occlusion (two patterns of contact may occur): <ul style="list-style-type: none"> • Canine-guided. • Group function. <ul style="list-style-type: none"> • Non-working side occlusion. • Lateral non-working side occlusion involves the posterior teeth on the side away from which the mandible moves.

TWO DIFFERENT OCCLUSAL SCHEMES ARE POSSIBLE (Chu, F.C., et al., 2002)

Conformative	Reorganised
Sufficient teeth and/or tooth substance to provide satisfactory function, aesthetics, comfort and phonetics after restorative treatment.	Insufficient teeth and/or tooth substance are present to provide satisfactory function, aesthetics, comfort and phonetics.
Tooth wear slight or moderate and the OVD does not need changing.	OVD and/or occlusal plane may need changing and CR registration is essential.
May need some occlusal adjustments before placing the restorations or prostheses – recontour plunger cusps.	Extensive restoration work may be required when many teeth are retained. If the Dahl principle is used for creating interocclusal space for anterior restorations, selected posterior teeth may be allowed to erupt passively following the increase in OVD.

Diagnostic Wax-Up

Communication between the dentist and the laboratory has always been the key to obtaining a superior result in both the aesthetic and functional aspects of restorative dentistry. An essential yet overlooked part of this communication is the diagnostic wax-up, helping the patient, dentist and technician to visualise the final aesthetic and functional treatment outcome.

Advantages of Precise Diagnostic Wax-Up

Powerful Patient Communication Tool

The patient is presented with a natural-looking 3D representation of the final case. It helps contrast the current situation with the possibility of a more aesthetic smile. It facilitates acceptance of the treatment plan and informed consent.

Visual Aid for Adequate Tooth Preparation

The dentist can obtain a visual understanding of tooth reduction requirements, significantly reducing preparation appointment time. Silicone matrices created from the wax-up serve as valuable checks to ensure adequate preparation. The dentist can also pre-plan the location and contour of any gingival tissue recontouring.

Template for Final Restorations

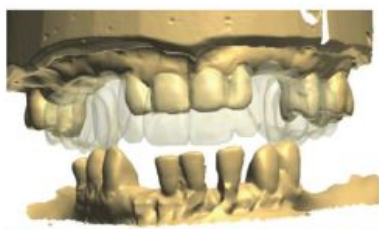A smile design is created, which is a valuable tool to allow the patient and clinician to assess the final outcome. It allows careful evaluation of occlusal function. It is also a vital communication tool for both dentist and technician.

Quick Fabrication of Excellent Provisional Restorations

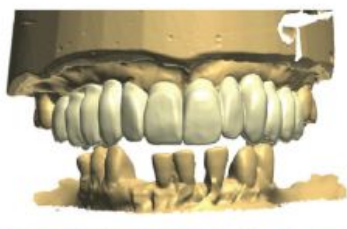Clear stents can be created from the diagnostic wax-up. Fill the stent with temporary material and place it over the prepared teeth for two minutes. Peel off the stent and polish the temporaries to mimic the final restorations. Attractive temporaries can be created promptly. These allow the patient a few days to evaluate the shape and function of their "new teeth".

VIRTUAL CAPABILITIES

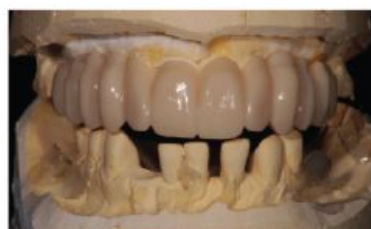Polymethylmethacrylate (PMMA) Try-In Over Existing Teeth:



Severe wear and lack of posterior support.

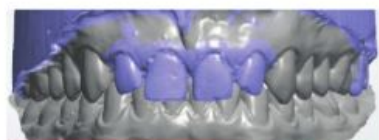

Diagnostic wax-up – function restored.

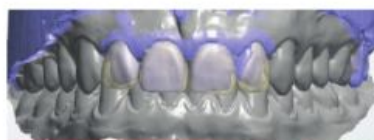

Provisionals from the diagnostic wax-up.

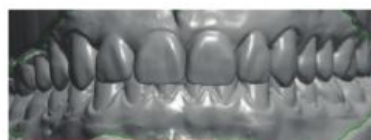Virtual Diagnostic Wax-Up:



Scan showing existing tooth shape.



Shadow of ideal tooth shape.



Final design of tooth shape ready for resin printing model.

05

MATERIALS IN DENTISTRY



Overview


At Modern Dental Pacific, we often get asked the question, "Which material do you recommend for my case?". It's an important question that dentists want to get right, as the choice of a material can greatly affect the quality and longevity of a prosthesis or restoration, as well as greatly influence the aesthetics of the finished result.

The problem, of course, is that the answer depends on what you and your patient want to achieve. Do they value a natural appearance ahead of function and durability? Is fit more important than colour? Is it likely that you will need to modify the restoration or denture later, perhaps as the patient's circumstances change? Or perhaps time and cost are the primary considerations and all you need is a reliable, simple solution that will work consistently well in your hands, especially for patients who may not be easy to treat.

Thankfully, in the era of CAD/CAM dentistry there are several affordable restoration materials that offer different combinations of features to suit the specific needs of your case. This can, however, leave you with too many options and a case of information overload.

At Modern Dental Pacific, we are happy to guide you along the way to finding the solution that best suits you and your patient. We're only a phone call away, and are always happy to act as a sounding board as you think through different options.

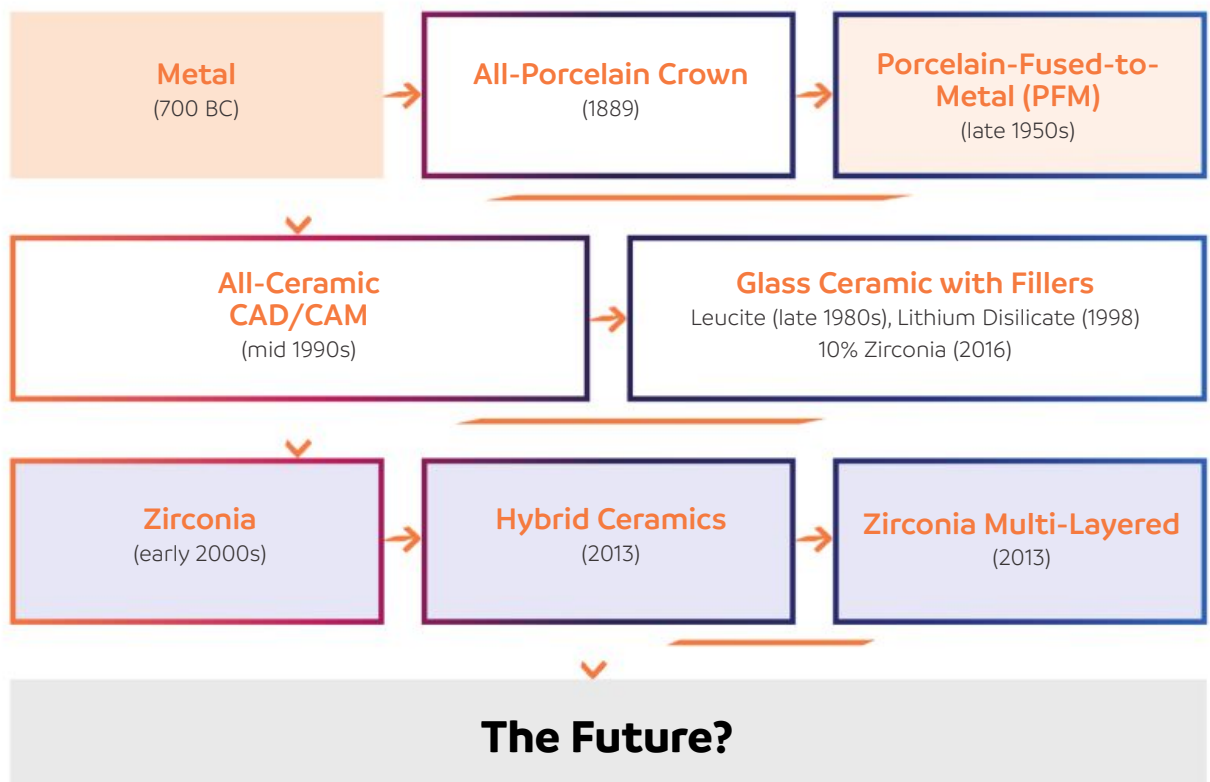
For now, though, we hope you will enjoy reading more about the range of materials that are available to you.



05

MATERIALS IN DENTISTRY

Evolutionary Change





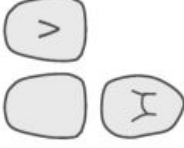

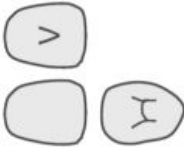
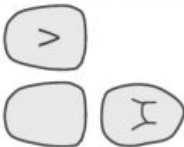
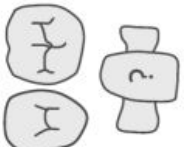


The use of materials to rehabilitate tooth structure is constantly evolving to the benefit of the patient and clinician. Finding predictable approaches for successful restorative procedures has been the goal of clinical and material scientists (Vaderhobli, R.M., 2011).

The availability of the different materials enables the clinician to tailor the case to optimise the restorative outcome.

Broadly, materials employed in dentistry can be classified into the following groups:

1. Ceramics:
 - a. Feldspathic
 - b. Glass-based – leucite, lithium disilicate, lithium silicate
 - c. Polycrystalline – alumina, zirconia (monolithic or layered)
2. Metal
3. Metal-ceramic
4. Hybrid-ceramic

Ceramic Restorations Quick Guide

Material Class	Hybrid Ceramic		Glass Ceramic			Monolithic Zirconia (Zir)		Veneered Zirconia	
	Zirconium Silicate	Inorganic Ceramic Matrix Filled with Organic Polymer	Leucite Glass Ceramic	Lithium Silicate with 10% Zirconia	Lithium Disilicate Glass Ceramic	Zir – Ultra Translucency	Zir – High Strength	Zirconia with Leucite Veneer	Zirconia with IPS e.max® Veneer
Example	Ceramage®	Enamic®	IPS Empress® Esthetic	Vita Suprinity® Celtra® Duo	IPS e.max® (CAD or Press)	U-Zir®	FMZir (Fully Milled Zirconia)	PFZ	IPS e.max® ZirPress/ ZirCAD
Properties	140	150-160	160	360-500	CAD 530 Press 470	557-850	1000-1200	90 Porcelain 1000-1200 Base	120 Porcelain 1000-1200 Base
	Extensive	Extensive	12	8	20	20	12	8 framework shades	8 framework shades
	✓ ✓ ✓	✓ ✓ ✓	✓ ✓ ✓ ✓ (Able to be layered)	✓ ✓ ✓ ✓	✓ ✓ ✓ ✓ (Able to be layered)	✓ ✓ ✓ ✓	✓ ✓ ✓	✓ ✓ ✓	✓ ✓ ✓
Indications									

Legend: ? = Use with caution
 + = Longer spans possible

Overview of Materials

Understanding the basic structure of various dental ceramics is important as their underlying composition determines their physical properties and this, accordingly, dictates their suitability for any given clinical situation. Consider dental ceramics as a spectrum with an unfilled glassy matrix at one end, and a virtually wholly crystalline structure with little if any matrix at the other end.

THE IDEAL DENTAL MATERIAL FOR RESTORATIVE DENTISTRY WOULD HAVE:

- Aesthetic capabilities of IPS e.max®.
- Strength of zirconia.
- Flexibility of reinforced resin.
- Coefficient of thermal expansion similar to tooth structure.
- Ability to withstand occlusal forces.

Feldspathic Ceramics (Glass Matrix)

These are largely vitreous or glass ceramics, with 3D networks of atoms having no regular pattern to the spacing and characterised by an amorphous structure. Dental ceramics in this category come from a group of mined minerals called feldspar and are based on silica (silicon oxide) and alumina (aluminium oxide) and hence belong to a family called aluminosilicate glasses.

Properties of Feldspathic Ceramics

Chemically inert.	Low opacity.
Biocompatible.	High translucency.
Poor mechanical properties (flexural strength 56 MPa).	Low heat conductivity.
High shrinkage during firing – suitable as a veneer over a stronger core.	Hard.

Glass-Based Ceramics (Filled Particles)

EVOLUTION OF MATERIALS

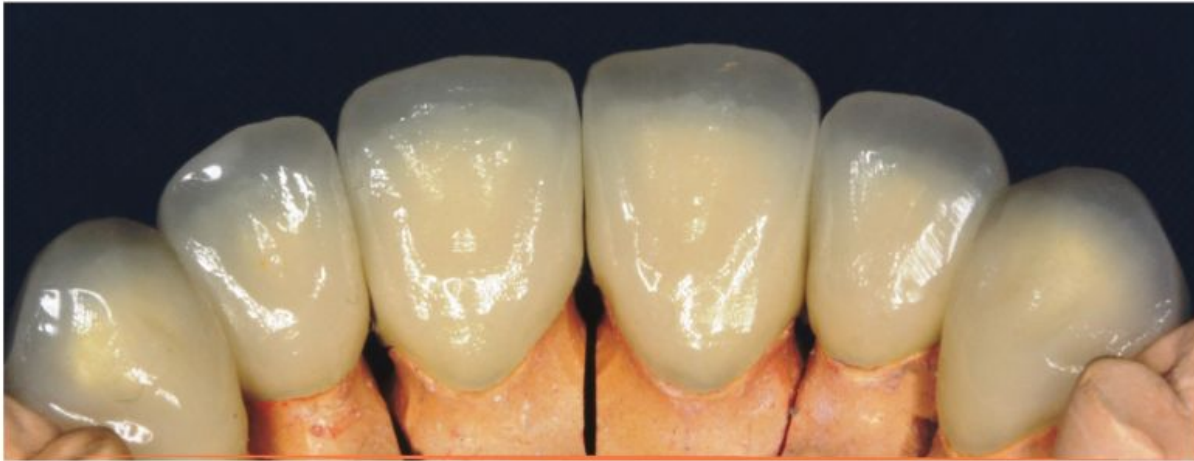As materials have evolved there has been a movement along the continuum from an unfilled glassy matrix to a wholly crystalline structure. Filler particles were added in increasing amounts to the base glass matrix to improve mechanical properties and to control optical effects such as opalescence, colour and opacity. The first fillers to be used contained particles of a crystalline mineral called leucite. This was added by simply mixing in the filler ceramic (between 17-25% mass). The porcelains created could be fired successfully onto metal substructures.

In the 1980s, leucite was used at much higher concentrations (40-55% mass) than those needed for metal-ceramics. In this system the ceramic is pressed into a mould at high temperatures (Wohlwend, A. and Ivoclar Ag. 1988). This resulted in reduced porosity and excellent fit, e.g. IPS Empress® I, now marketed as IPS Empress® Esthetic, OPC® (Zahn Dental, a division of Henry Schein) and Finesse® All-Ceramic (Dentsply).

The Use of Leucite as a Filler in Dental Ceramics:

- It has an index of refraction that is close to that of feldspathic porcelain, thus maintaining some translucency.
- It etches much faster than the base glass, thereby creating a multitude of tiny fissures into which resin cements will flow to create a strong micromechanical bond.

Restorations of this type exhibit much improved flexural strength (160-300 MPa) as compared to basic feldspathic porcelain as a result of the almost perfect distribution of the leucite crystals within the glass matrix, without any significant reduction in translucency.



Incisal translucency in all-ceramic crowns.

Lithium Disilicate

An alternative approach is where the filler particles are grown inside the basic glass restoration after it has been formed. In one approach, the glass is given a special heat treatment (ceraming), causing the precipitation and growth of the crystals within the glass. The fillers are derived chemically from atoms of the glass itself.

The first such glass ceramic was DICOR™ (Dentsply) and is no longer available (Grossman D.G., 1985). This was followed by a glass ceramic containing 70% crystalline lithium disilicate, IPS Empress 2®. The structure of these porcelains increases flexure resistance to 320-450 MPa as a result of the densely distributed elongated crystals, which increase in size after pressing. Such porcelains are used to make the restoration's inner coping, which is then covered with a more aesthetic porcelain.

CLINICAL TIP

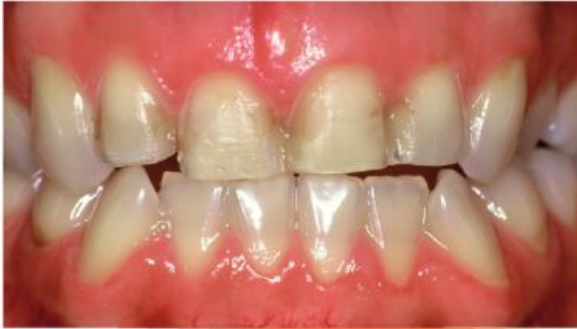Uses for IPS e.max®:

- Crowns – anterior & posterior.
- Inlays/onlays.
- Veneers.
- Anterior implant crowns.
- Anterior 3-unit bridges (include premolar).

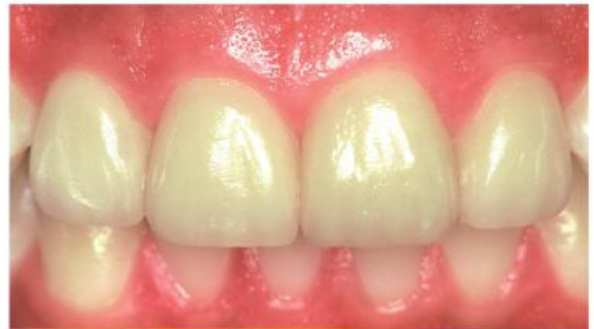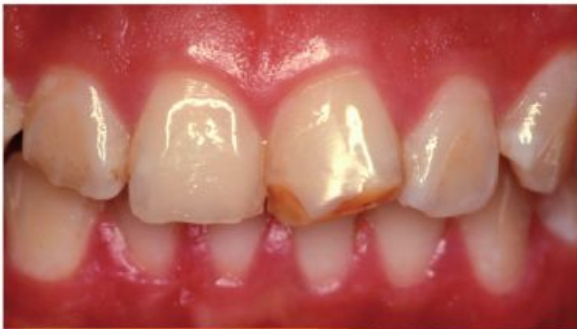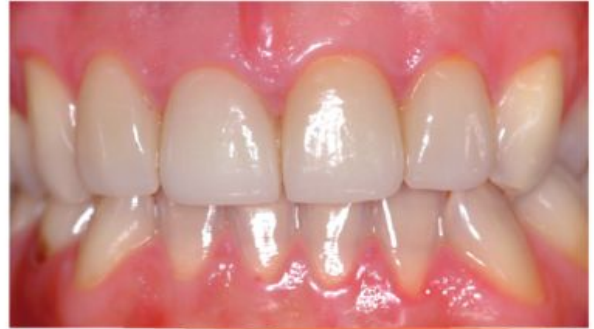IPS e.max® IS A LITHIUM DISILICATE GLASS CERAMIC WHICH OFFERS:

- Optimised translucency – light diffusion properties.
- Pleasing aesthetics.
- Superior durability (470-530 MPa flexural strength).
- Strength for full anatomical restorations.
- Opalescence.
- Option of monolithic (solid) aesthetic restorations using CAD or layered/veneered restorations for optimum aesthetics.

Before



After



Treatment cases that utilise IPS e.max®.

FABRICATION

IPS e.max® Press

IPS e.max® Press is processed in the dental laboratory using the well-known lost-wax technique. Glass ceramic ingots are pressed into a mould.

IPS e.max® CAD

The glass ceramic is milled in a crystalline intermediate phase. It is in a “soft” state with a “bluish” colour. Restorations can be adjusted by hand or cut back quickly with initial strength of at least 130 MPa. Final strength of 530 MPa is achieved during a fast crystallisation process.

IPS e.max® ZirCAD

Zirconia frameworks are milled via CAD/CAM. The frameworks can be veneered with IPS e.max® Ceram or have IPS e.max® ZirPress pressed onto them.

IPS e.max® ZirPress

Ingots combine the Press and CAD/CAM technique and are used to press onto IPS e.max® ZirCAD frameworks.

IPS e.max® Ceram

Nano-fluorapatite layering ceramic. Can be used on either glass ceramics or zirconium oxide.

PROCESSING

Glass ceramics are categorised according to their chemical composition and/or application. IPS e.max® lithium disilicate is composed of quartz, lithium dioxide, phosphorous oxide, alumina, potassium oxide and other components. These powders are mixed to form a glass melt. When the correct viscosity is attained, the glass melt is poured into a separate steel mould of the proper shape. The material then cools in the mould until it reaches a temperature at which no deformations occur. This process produces minimal pores or other internal defects due to the glass flow process. The blocks or ingots are produced in one batch depending on the shade and size of the materials. This composition yields a highly thermal shock-resistant glass ceramic due to the low thermal expansion when it is manufactured.

Opacity is determined by the nanostructure of the material. Scattering of light at the interfaces between the crystals and the glass matrix causes a higher opacity. Due to a similar refractive index of light for the lithium disilicate crystals and the glass matrix, it is possible to achieve a very high translucency. The glass ingots or blocks are then processed using the lost-wax hot pressing techniques (IPS e.max® Press) or state-of-the art CAD/CAM milling procedures (IPS e.max® CAD).

MANUFACTURE OF IPS e.max® CAD

During processing, IPS e.max® CAD has two crystal types and two microstructures that provide its unique properties during each phase of its use.

Intermediate Lithium Metasilicate Crystal Structure, Li_2SiO_3

Allows the material to be easily milled without excessive bur wear.

Has high tolerances and marginal integrity.

In this state, the material will have a deeper blue. The final restoration has more chroma.

The glass ceramic in the “blue” stage contains approximately 40% by volume lithium metasilicate crystals with an approximate crystal size of $0.5\mu\text{m}$.

After milling, heat treating occurs in a porcelain furnace at $840\text{-}850^\circ\text{C}$.

Lithium Disilicate, $\text{Li}_2\text{Si}_2\text{O}_5$

Metasilicate phase is completely dissolved and the lithium disilicate crystallises.

Results in improved mechanical and aesthetic properties.

Glass ceramic contains approximately 70% by volume lithium disilicate crystals with an approximate crystal size of $1.5\mu\text{m}$.

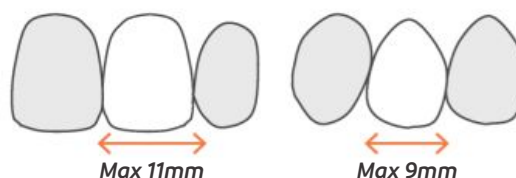
MANUFACTURE OF IPS e.max® PRESS:

- Produced according to a bulk casting method that aims to prevent defect formation.
- Following the glass formation, the ingots are then nucleated and crystallised in one heat treatment to produce the final ingots.
- The ingots are pressed at about 920°C for 5-15 minutes to form a 70% crystalline lithium disilicate restoration.
- The microstructure of the pressable lithium disilicate $\text{Li}_2\text{Si}_2\text{O}_5$ material consists of approximately 70% by volume of lithium disilicate crystals in a glassy matrix with an approximate crystal size of $3\text{-}6\mu\text{m}$.

CLINICAL TIP

IPS e.max® Bridges

- In the anterior region (up to canine) the pontic width should **not exceed** 11mm.
- In the premolar region (canine to second premolar) the pontic width should not exceed 9mm.
- Bridges of more than 3 units or those in the premolar to molar region should instead be fabricated as IPS e.max® ZirPress.



CLINICAL TIP

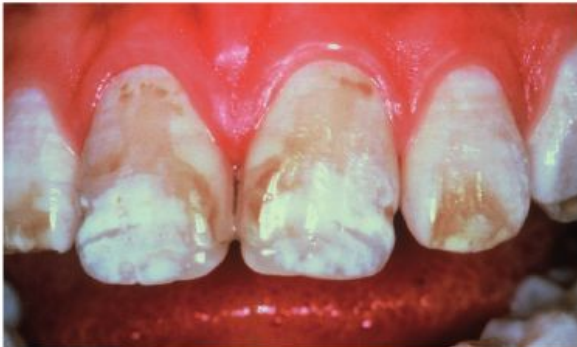IPS e.max® ZirPress

- Consider using IPS e.max® Ceram pressed over zirconium oxide substructures for patients with bruxism or where the span length or tooth size prevents ideal use of IPS e.max®. The porcelain used can be matched to adjacent IPS e.max® crowns. Allow adequate preparation depth for the zirconia structure and overlying porcelain.
- Suitable for single-tooth restorations.
- Bridges in the anterior and posterior region.
- Implant superstructures.

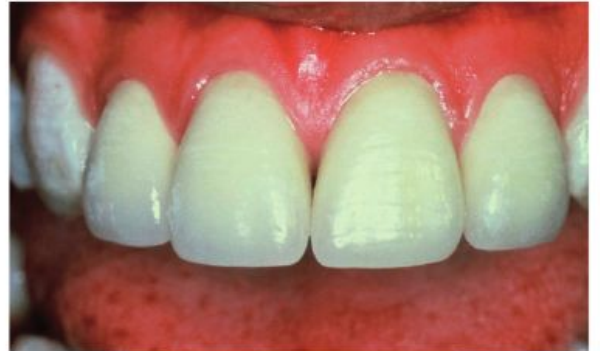Material Properties of Lithium Disilicate

Strength	These materials are almost three times the strength of the original IPS Empress® I.
Fatigue	Monolithic lithium disilicate confers durability to the final restoration.
Colour and Translucency	Available in various opacities/translucencies that allow lifelike aesthetics.
Biocompatibility	Validated by manufacturer (Ivoclar Vivadent).

Before



After



Masking of discoloured anterior teeth by using a more opaque ingot.

CLINICAL TIP

When the stump shade is dark, consider using a more opaque ingot. This image shows differing value and hue of ceramic ingots.



High-Strength Crystalline Ceramics

Polycrystalline ceramics contain densely packed atoms with little or no vitreous glassy “matrix” phase. Polycrystalline ceramics are generally much tougher and stronger than glassy ceramics. Consequently, restorations made with these ceramics are more difficult to drive a crack through compared to the less dense and irregular linkages in glass structures.

Zirconia

Zirconium oxide (the oxidised form of zirconium metal) is a polycrystalline material with a tetragonal structure partially stabilised with yttrium oxide, yielding an almost total absence of structural porosities. Zirconia may exist in several crystal phases that are stabilised at room temperature by the addition of minor components such as magnesia, calcia, ceria or yttria (3wt%-5wt%). The result is partially stabilised zirconia. The tetragonal zirconia phase is stabilised with yttrium oxide but can change to a monoclinic phase under stress. There will be a concomitant 3% volumetric expansion that produces a compressive stress around the fracture that inhibits crack propagation. This dimensional change removes energy from the crack and stops its progression. This is called “transformation toughening”. Transformation toughening gives zirconia excellent mechanical properties of high flexural strength from 550-1200 MPa.

Polycrystalline ceramics are usually more opaque and more difficult to process into complex shapes than glass ceramics. Computer-aided manufacturing (CAM) has enabled production of well-fitting prostheses from polycrystalline ceramics. Zirconia can be either monolithic (unlayered or “fully milled”) or layered with a veneering ceramic, which is called Porcelain-Fused-to-Zirconia (PFZ). There are many different brands of zirconia in the marketplace.

A. MONOLITHIC ZIRCONIA (NO VENEERING CERAMIC):

- Fully Milled Zirconia (FMZ) crowns can readily mask out discoloured, non-vital teeth where sufficient tooth preparation exists of at least 0.6mm.
- Thicknesses greater than that are far too opaque for upper anteriors.
- Overpreparation of teeth is contraindicated when using monolithic zirconia as there is no need to create room for veneering porcelain.
- Base dentine shades are now available to replace former opaque dentine shades.
- FMZ restorations are coloured utilising a three-zone colouring system:
 - » The unsintered restoration is brushed with the final shade around the cervical area
 - » The desired body shade is then applied
 - » Effect shades are finally added to the occlusal aspect of the crown
- Sintered zirconia can now be immersed in a specific-coloured dye, which minimises the high value of the material and more closely matches the abutment colour. Some brands of zirconia have built-in colouring.
- Ageing has been observed in the presence of moisture. This is called low temperature degradation.

Two Milling Systems are Used to Make Zirconia Frameworks

Mill 100% Dense Sintered Zirconia

- Rigid milling unit is required.
- Milling times vary between 2 and 4 hours.

Mill Partially Fired 50% Dense Zirconia Blocks

- Blocks are weak and easy to mill.
- The milled framework is fired for 6-8 hours to make it denser.

Properties of FMZ:

- Once the shade has been developed, sintering occurs in an oven at 1,400-1,550°C.
- This shrinks the zirconia, making it denser and therefore less likely to fracture or break.
- The CAD program increases the crown size during milling to allow for the sintering shrinkage.

CLINICAL TIP

With adequate connector size 3-, 4- and even 6-unit bridges are very dimensionally predictable. Consider “closed” embrasures in the design to allow sufficient connector bulk.

Indications of FMZ:

- Bridges for posterior teeth where exquisite aesthetics are not paramount.
- Where metal-free options are preferred.
- Bruxers where:
 - » Porcelain-Fused-to-Metal (PFM) metal occlusal or full cast crown is not desired
 - » The antagonist is metallic or zirconia
- Limited interocclusal space.

Contraindications of FMZ:

- High aesthetic requirements.
- Exposed dentine on the antagonist preoperatively.
- Short clinical crown (limited bonding surface for micromechanical retention).
- Using a FMZ crown to replace a PFM may result in a high-value crown due to the thickness of the axial walls of the PFM preparation.
- Possible endodontics.
- Post-insertion occlusal adjustment.

Clinical Recommendations

Preparation

- Manufacturer's recommendations for tooth reduction vary from 0.5-1.0mm.
- Full shoulder or heavy chamfer.

Adjusting

- Occlusal adjustments should be meticulously finalised prior to cementation.
- Adjust FMZ with a fine-grit diamond using water and air spray to keep it cool and to avoid microfractures.
- An oval-shaped bur is the most effective for occlusal and lingual surfaces.
- A tapered bur is the ideal choice for buccal and lingual surfaces.

Polishing

- Inadequate polishing leaves a more abrasive finish which is detrimental to the opposing dentition. Use a polishing kit specifically designed for zirconia.

Cementation

- For standard preparations, use resin-reinforced glass ionomer cement e.g., RelyX™ Luting Cement (3M ESPE), Fuji PLUS™ (GC CORP).
- For short or overtapered preparations, use RelyX™ Ultimate Adhesive Resin Cement (3M ESPE), PANA VIA™ F2.0 (Kuraray Noritake Dental Inc.).

CLINICAL TIP

Cementing Zirconia Restorations

1. After trying-in the restoration and checking fit and occlusion, the intaglio surface needs to be disinfected then cleaned to remove all contaminants. This can be achieved with Ivoclean™ although sandblasting with up to 50µm abrasive is also effective (Cavalcanti, A.N., et al., 2009). The restoration should then be rinsed and dried.
2. Zirconia should never be etched as this will impair bonding, especially where phosphoric acid is used.

Ultra Translucent Zirconia

Ultra Translucent is a new formula of zirconia, offering a unique combination of translucency and strength. This product is a breakthrough given that traditionally zirconia is considered a strong but opaque material with questionable aesthetics in anterior regions. The strength of Ultra Translucent Zirconia is higher than more translucent alternatives and so it addresses the market in between glass ceramics and the more opaque crystalline zirconias. Multi-layered blocks enhance aesthetics without compromising strength by layering. Translucency is similar to IPS e.max®.



CLINICAL TIP

Consider Ultra Translucent Zirconia for cases where strength and resistance to chipping are required in combination with good aesthetics. Suitable for anterior crowns, inlays/onlays and other single-unit restorations, and some posterior crowns.

B. PORCELAIN-FUSED-TO-ZIRCONIA (PFZ):

- Used as a more aesthetic option than monolithic zirconia.
- Zirconia forms the framework material for anterior and posterior crowns and bridges, with veneering porcelains applied over all or part of this zirconia core.
- Veneering porcelains have evolved with fine microstructures with improved optical properties and clinical performance.
- More tooth preparation is needed than for FMZ to allow room for veneering porcelain.
- The specifically designed veneering ceramics are more translucent and generally produce excellent aesthetics in 0.6mm thickness (over a 0.6mm zirconia coping), meaning a reduction of at least 1.2mm is critical.

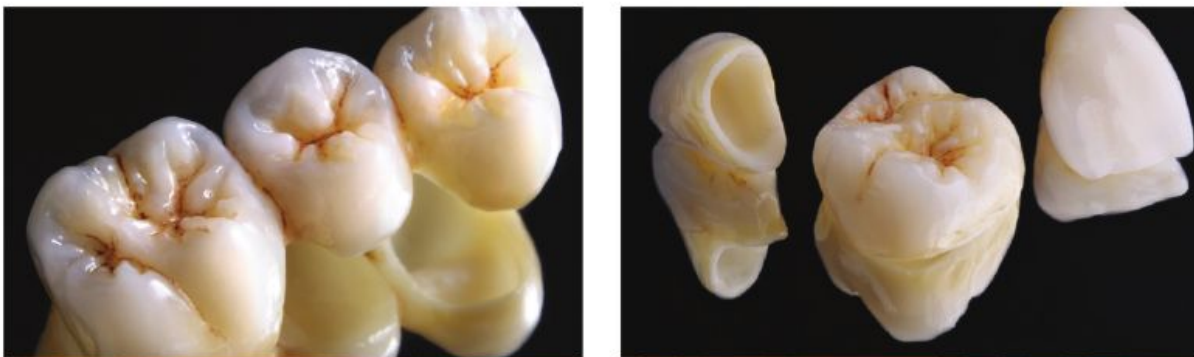
The ideal coping design:

- The ideal coping design allows even porcelain thickness. PFZ needs more support in proximal areas than PFM. The core to veneering porcelain thickness ratio is optimal at 1:1 for aesthetics and function.
- Cohesive fracture within the veneering ceramic has been the most frequent reason for failures.

CLINICAL TIP

Core bulk fractures in bridges with PFZ or monolithic zirconia are most commonly located in the connector region and start from the gingival surface upward where the tensile forces are greatest due to occlusal loading.

Lava™ Classic Zirconia Frame



Lava™ crowns and bridges.

Lava™ is made by 3M ESPE and is a veneered zirconia with 90 MPa porcelain and 1200 MPa for the substructure. It has 8 framework shades and is moderately translucent.

- Uses an yttrium oxide partially stabilised zirconia framework with high flexural strength, high fracture toughness, and exhibits transformation toughening when subjected to tensile stress.
- The cores have a radio-opacity comparable to metal, which enhances radiographic evaluation of marginal integrity, excess cement removal, and recurrent decay.
- Indicated for anterior or posterior crowns and long-span bridges.
- Can be cemented with traditional crown and bridge cements.

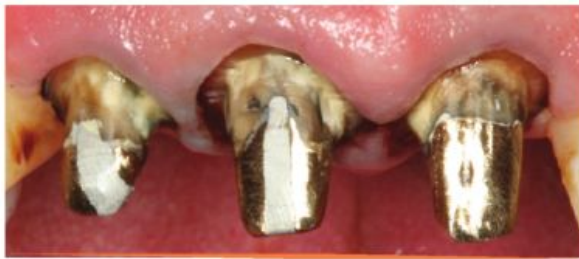CLINICAL TIP

It is suitable for 8 unit bridges with up to four pontics in the anterior region.

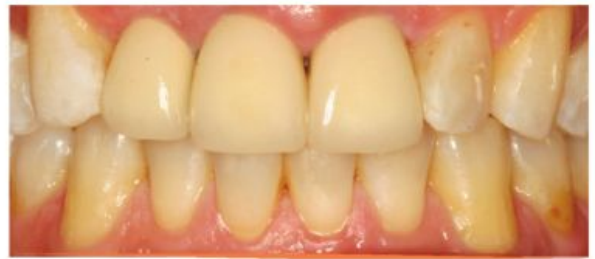Comparisons between Zirconia and PFM Restorations Include the Following:

Aesthetics:

- Life-like translucency is improving for anterior crowns and bridges with UZir.
- If and when gingival recession occurs, the resulting visible margin will be less offensive than the exposed margin of a PFM restoration.
- Behave similarly to PFM in terms of long-term colour stability and opposing tooth wear.



The original gold posts and cores and remaining dentine are difficult to mask.



Cemented crowns demonstrate masking ability of PFZ.

Applications:

- Span recommendations vary with each particular system. Each manufacturer recommends a maximum span for their own material e.g. up to 12 units for IPS e.max® ZirCAD/ZirPress.
- Unsuitable for prostheses requiring precision attachments or stress breakers.

Cementation:

- As with PFM restorations, resin-modified glass ionomer cements are used routinely and resin-based composite cements for compromised retention cases.

Why do restorations fail?:

- Veneering ceramic may be prone to failure at high loads during masticatory function.
- Using veneering ceramic with wrong coefficient of thermal expansion.
- Residual stresses in bilayer restorations due to a thermal gradient between the layers.
- Thick layers of veneering ceramics on zirconia cores may generate high-tensile subsurface residual stresses, ultimately resulting in cracking or chipping.
- Improper coping design meaning insufficient support for porcelain.

Metals in Dentistry

The main role for metals in dentistry has been in the realm of alloys. Fixed prostheses require alloys as the pure metals do not have the needed physical properties to perform in these restorative situations.

CLINICAL SELECTION OF ALLOYS

The physical requirements of the alloy are critical. If there is a long-span restoration, an alloy should be chosen with a high modulus of elasticity particularly with a PFM restoration. The fit depends on the laboratory to manage casting shrinkage effectively, which is most difficult with high-melting alloys. The tensile strength of the alloy becomes important if the final restoration has connectors between several units that are narrow occluso-gingivally. This may be due to short crown height, soft tissue or aesthetic considerations. With PFM restorations, the colour of the alloy's oxide is critical.

Alloys – Properties and Indications

	Bonds to Porcelain				Does Not Bond to Porcelain		
	High Noble	Noble	Base				
	IPS d.SIGN 96®	Degunorm®	IPS d.SIGN 53®	Wirobond®	Academy Gold™	Minigold®	Harmony® 2
Supplier	IVOCLAR VIVADENT	DENTSPLY	IVOCLAR VIVADENT	BEGO	IVOCLAR VIVADENT	IVOCLAR VIVADENT	IVOCLAR VIVADENT
Materials & Metal Content	Au 74%	Au 74%	Pd 54%	Co 64%	Au 77%	Au 40%	Pd 33%
Type	IV	IV	IV	IV	II	IV	III
Indications	Inlays/ Onlays	✓	✓	✓	✓	✓	–
	Partial Crowns	✓	✓	✓	✓	✓	✓
	Single Crowns	✓	✓	✓	✓	✓	✓
	PFM Crowns	✓	✓	✓	✓	–	–
	Telescope & Conus Crowns	✓	✓	✓	✓	–	✓
	Root Canal Posts	✓	✓	–	✓	–	✓
	Short-Span Bridges	✓	✓	✓	✓	✓ (hardened)	✓ (hardened)
	Long-Span Bridges	✓	✓	✓	✓	–	✓
	Implant Super-Structures	✓	✓	✓	✓	–	–
	Partial Dentures	✓	✓	✓	✓	–	–

GUIDELINES FOR SELECTION OF ALLOYS

(Wataha, J.C., 2002)

Develop an Understanding of Alloys:

- Avoid selecting an alloy based on its colour unless all other factors are equal.
- Know the complete composition of alloys, and avoid elements to which the patient is allergic. Know the alloys that the laboratory uses; request a specific alloy in the laboratory prescription. Know your laboratory.
- When possible, use single-phase alloys over multiple-phase alloys.
- Keep track of alloys used. As a minimum, the name of the alloy and manufacturer should be recorded.

Use Clinically Proven Products from Quality Manufacturers:

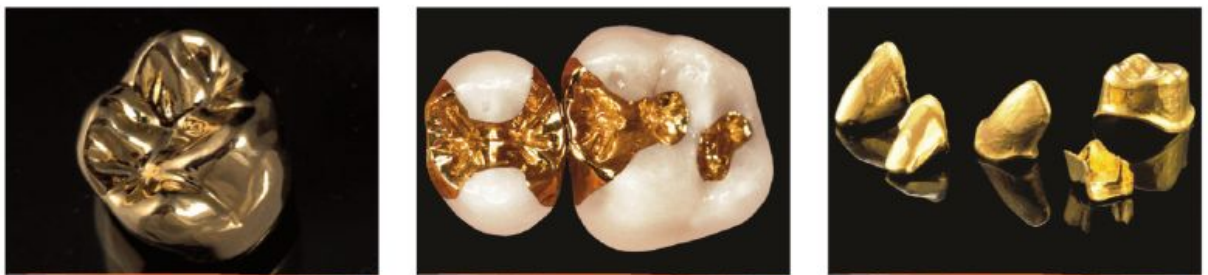- Use alloys from companies that research and manufacture their own alloys.
- Use alloys that have been tested for elemental release and corrosion and that have the lowest possible release of elements.
- Use a dental laboratory that is knowledgeable about its alloys and willing to discuss issues about them. Be comfortable with the alloys that the laboratory uses.

Develop a Clinical Philosophy:

- Focus on long-term clinical performance and long-term costs of restorations rather than on short-term costs.
- Consider the clinical situation when selecting an alloy. Select the alloy that meets the needs of the patient. Avoid a “one-size-fits-all” approach.
- Note that the practitioner is ultimately responsible for the safety and efficacy of the restoration.

Gold Restorations

Gold’s properties of ductility and plasticity, thermal or electrical conductivity highlight its frequent use in indirect restorations (Solow, R.A., 2016). Restorations made of gold provide excellent marginal fit and a low risk of corrosion. Gold is fracture resistant, expands similarly to tooth structure, wears like enamel and supports proper occlusal contact (Solow R.A., 2016). The longevity of gold was researched by Donovan, T.E., 2006, who showed that almost 90% of the restorations had been in service for over 9 years, 72% for over 20 years and 45% from 25 to 52 years.



INDICATIONS FOR USE OF GOLD IN DENTISTRY:

- Inlays/onlays/overlays.
- Dowels, post and cores (Type II, III and IV gold alloys).
- Partial crowns, full crowns, telescopic crowns.
- Bridges.
- Removable dentures.
- Implant-supported overdentures with bar joints.

MAIN CONTRAINDICATIONS FOR USING GOLD ALLOYS AND ONLAYS INCLUDE:

- Aesthetics.
- Extensive cavities.
- Bruxism.
- Short crowns.
- Thin-walled cavities (weak retention of gold restoration).

Posts and Cores

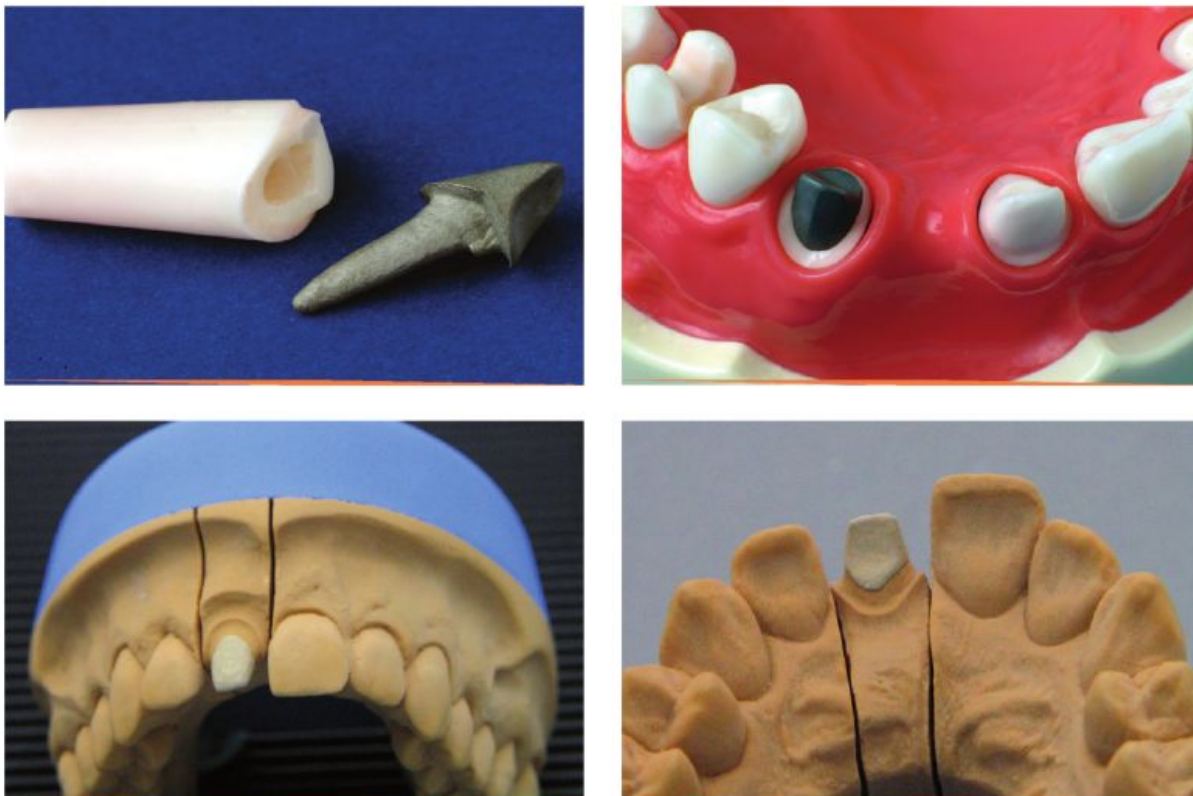The choice of an appropriate restoration for endodontically treated teeth is guided primarily by strength for posterior teeth and a combination of strength and aesthetics for anterior teeth. High-strength post and cores for posterior teeth in both non-precious and precious alloys are available due to their superior mechanical properties and were once used exclusively as foundations for indirect restorations.

However, if an all-ceramic crown is chosen as the final restoration in anterior cases, the colour and opacity of the post may lead to a discolouration and shadowing of the crown. This is particularly significant in IPS e.max® crowns. Tooth-coloured fibre and zirconia post systems were introduced that were deemed to be capable of resisting occlusal loads whilst offering light transmission characteristics. The main advantage of using a fibre post is that the modes of failure are generally more retrievable than those of metal post systems. The use of fibre posts reduces the risk of root fracture significantly as the modulus of elasticity of these posts is closer to that of dentine (Asmussen, E., et al., 1999). The most common causes of failure associated with fibre post systems are post de-cementation and secondary caries (Mannocci, F., et al., 2005).

As far as zirconia posts are concerned, the high incidence of catastrophic root fractures accompanied with post fractures may be attributed to their stiffness and lack of plastic deformation. Zirconia posts cannot be etched; therefore, it is not possible to bond a composite core material to the post, making core retention problematic (Goracci, C. and Ferrari, M., 2011).

Designs are available that reduce the influence of the cast posts and cores to the final aesthetic outcome of all-ceramic restorations, including the application of an opaque porcelain to the metal core and, if space permits, an additional layer of shoulder porcelain in the same shade as the final restoration. Significantly, the porcelain is etched prior to leaving the laboratory with the aim for both the final all-ceramic crown and core ceramic to be silanated to achieve maximum bond strength.

The presence of a ferrule of 1.5-2mm of sound coronal tooth structure between the core and the finish line is critical (Isidor, F., et al., 1999, Jovanovski, S., et al., 2017).



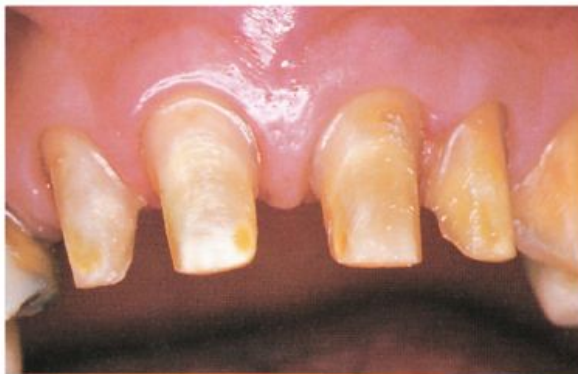Examples of posts and cores.

Metal-Ceramics (Porcelain-Fused-to-Metal)

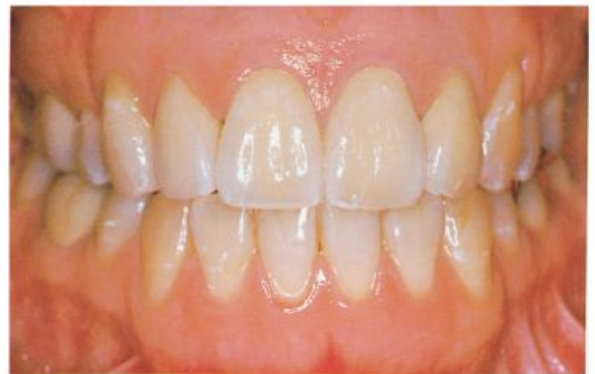PFM restorations were introduced following the development of porcelains that were thermally compatible with dental alloys during firing. This imparts high tensile strength and fracture toughness, wear resistance (low friction coefficients) and corrosion resistance.

Crowns made from the finest porcelain systems (IPS InLine® [Ivoclar Vivadent], Noritake [Noritake Dental], GC Initial™ [GC Corp]) achieve aesthetics, excellent bond strength and are gentle to the antagonists. It is ideal to have margins trimmed and finished under high-powered microscopes and have cases equilibrated on appropriate articulators.

Ideally, tooth reduction must provide sufficient length of the preparation for adequate retention, thickness of the ceramic component for optimal aesthetics (including opaquing porcelain) and sufficient clearance for occlusal function. The aesthetic result can be further enhanced by the incorporation of buccal or 360-degree porcelain margins, staining and characterisation when requested.



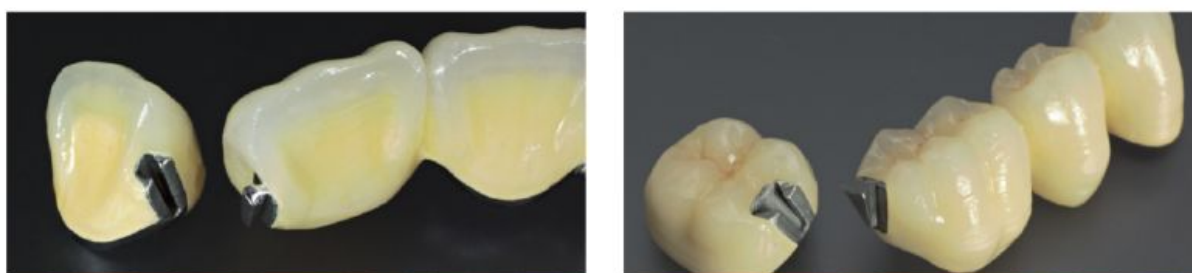
For all-ceramic margins, a shoulder width of at least 1.2mm (1.5mm is ideal).



Completed metal-ceramic crowns.

Advantages of PFM

Strength	Ceramic and metal bonded together is stronger than ceramic alone.
Marginal Integrity	A deep chamfer preparation yields the lowest marginal discrepancy values for PFM restorations – lower than those for lithium disilicate or zirconia restorations.
Aesthetics	Proper selection and placement of the cervical finish line, without encroaching on the biologic width and an extended porcelain labial margin, is essential.
High Bond Strength of Ceramic to Metal	Mechanical entrapment occurs by interlocking ceramic with small abrasions in the surface of the metal coping. Compressive forces within the metal ceramic occur with a properly designed metal coping. There is a slightly higher coefficient of thermal expansion for the metal coping than for the porcelain veneered over it. Chemical bonding is due to the formation of an oxide layer on the metal and is increased by firing in an oxidised atmosphere. Van der Waals forces occur as there is a similar attraction of charged molecules.
Posterior Full-Coverage Cases	Restoration of choice for high-stress bridges e.g. bruxer (metal occlusion). Long spans possible.
Restoration Design	PFM restorations are versatile and have been modified to act as retainers for a variety of designs of “conventional” bridgework. PFM bridges are also adaptable for cases where abutments are not parallel, allowing for different paths of insertion through placement of precision attachments and stress-breakers.



PFM bridges with stress-breaker.

Limitations and Other Considerations in PFMs

Tooth Preparation	PFMs can appear lifeless and unnatural unless 1.5mm is removed to allow for both metal and ceramic, otherwise a dull, opaque appearance and/or an overbuilt contour may result.
Pulpal Health	Removing excessive tooth structure may compromise retention and can lead to pulpal damage.
Colour Stability	Even if PFM margins are placed slightly subgingivally, gingival tissues may recede. Request a buccal porcelain margin for cases where recession is possible, where technicians trim back the margin of the metal coping slightly to create an all-ceramic margin.
Strength and Opacity	Anterior PFM restorations are usually reserved for the following situations: <ul style="list-style-type: none"> In patients exhibiting excessive occlusal loading; tooth wear, bruxism or insufficient interocclusal clearance exists to accommodate porcelain. A palatal metal surface is highly beneficial because of its resistance to fracture. To mask severe tooth discolouration.
Allergies	Hypersensitive or allergic patients can choose from titanium, nickel-free and beryllium-free, or noble or high-noble alloy copings.
Tooth Wear	Older PFM restorations used large particle size ceramics and these are known to cause wear of the opposing dentition that is exacerbated whenever occlusal adjustment of the ceramic occurs and the surface is left unglazed.
Cost	PFMs using noble or high-noble alloys incur costs that may make them more expensive to manufacture than pressed or CAD/CAM restorations.

FORMS OF PFM FAILURE

Primary Failure

Arises when the restoration itself fails, e.g. through complete or partial loss of the veneering porcelain. In many cases, though, the restoration will require replacement.

It may be possible to repair/replace the lost porcelain with products such as the CoJet™ System (3M ESPE) silicate ceramic surface treatment that, if successful, provides an economical alternative to replacing the restoration.

Secondary Failure

Includes the crown coming off, core failure, excessive loading, recurrent caries.

CLINICAL TIP

Removal of a well-retained PFM restoration is best achieved by sectioning the crown using a bur such as Midway's fine crosscut Beaver bur (Dentsply) either alone or in conjunction with a crown remover. When the tooth has been root filled (or the crown is being removed to permit root canal treatment), sectioning is advised in order not to fracture the already weak tooth.

Hybrid Ceramics

These are considered “high-performance polymers”. The materials are composite materials that contain either ceramics, nano-ceramics or glass combined with different resin components.

CERAMAGE®:

- Is suited for durable posterior restorations.
- Is a zirconium silicate indirect restorative material that can be used to create superior anterior and posterior crowns, veneers, implant-supported restorations and inlays and onlays.
- Has a full set of gingival colours that are ideal for copying gingival anatomy. This is particularly important when gingival modification is required and in implant cases.
- Bonds to various substructures, including non-precious and high-noble alloys.
- Can replicate the appearance and light-diffusing properties of dentine and enamel.
- Does not vitrify so there is no milky appearance or greying effect.
- Is colour stable.
- Simulates the wear of the natural dentition.
- Allows for conventional cementation.

RECENT MATERIALS

	VITA SUPRINITY®	VITA ENAMIC®
Characteristics	<ul style="list-style-type: none"> • Lithium silicate ceramic with 10% zirconia. • Fine-grained homogeneous structure. • Excellent translucency, fluorescence and opalescence. 	<ul style="list-style-type: none"> • Hybrid ceramic – inorganic ceramic matrix 86% filled with 14% organic polymer. • Ceramic network provides enamel-like abrasion properties and antagonist protection. • Absorbs masticatory forces.
Contraindications	Parafunction – especially non-vital teeth.	<ul style="list-style-type: none"> • Bridges. • Parafunction.
Shade Selection	Multiple shades available in both: <ul style="list-style-type: none"> • Translucent. • High Translucent. 	Multiple shades available in both: <ul style="list-style-type: none"> • Translucent. • High Translucent.
Bonding	<ul style="list-style-type: none"> • Pretreat restoration with Hydrofluoric acid (HF). Use silane. • Light-cure materials are advised for restorations with thin walls. • Final restoration is adhesively or self adhesively (recommended for crowns only) bonded. • Dual-cure cements are mainly advised for restorations with thick walls. 	<ul style="list-style-type: none"> • Pretreat restoration with HF for 60 secs. Use silane. • Light cure is used only for thin ceramics – i.e. veneers. • Can use self-adhesive composite e.g. RelyX™ Unicem to bond crowns (dentine adhesion). • Dual cure needed for thick ceramic and opaque restorations.
Finishing	Use VITA SUPRINITY® polishing sets.	Use VITA ENAMIC® polishing sets.

INLAYS AND ONLAYS

Main Options for Intracoronar Posterior Aesthetic Restorations

Indirect Ceramics	<ul style="list-style-type: none">• Preserve tooth structure.
Indirect Hybrid Composite	<ul style="list-style-type: none">• Produces quality, durable restorations (Barone, A., et al., 2008).• Are superior to direct composites because the bulk of polymerisation shrinkage takes place extraorally so there is less stress at the tooth-restoration margin.

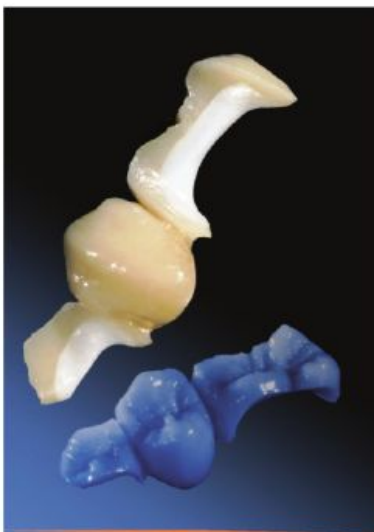
INDIRECT HYBRID COMPOSITES

Advantages:

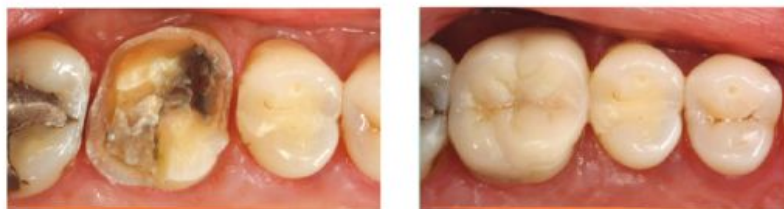- Excellent marginal adaptation and thus low microleakage.
- Ease of adjustment with excellent "polishability".
- Less post-operative sensitivity than direct composite.
- Less marginal staining.

Try-In, Cementation and Finishing:

- Clean preparation with a pumice and water slurry.
- Try in restoration – it should insert without significant resistance. Mark and adjust tight areas.
- Check occlusion at this stage in order to prevent fracture.
- Clean restoration with acetone.
- Cement restoration:
 - » If margins supragingival and in enamel, a dual-cure, resin-based adhesive is recommended. Silanate fitting surface of restoration and allow to dry. Etch enamel. Apply adhesive, seat, tack cure margins, remove gross excess, complete light curing from all directions
 - » If margins subgingival, RMGI cements are recommended (Brackett, M.G., et al., 2002)
 - » Deep subgingival margins pose a considerable problem (Gerdolle, DA., et al., 2005)
- Adjust occlusion. Finish margins. Polish under water spray (Haywood, V.B., et al., 1989).



Inlay-supported bridge (left). The large internal crack (below) will require further treatment and provisionalisation with a material with cushioning capabilities was chosen.



CERAMAGE® onlay crown on the molar.

06

AESTHETIC DENTISTRY




Overview

You've probably heard of the expression, "Beauty is in the eye of the beholder" and this is certainly the case for aesthetics in modern dentistry. Dental Aesthetics is an area which lacks universal agreement on what 'looks good'. In fact, it's likely that you will see possibilities and outcomes very differently from your patient.

Let's face it. We've all seen dentures in elderly patients that shine like beacons, or veneers that are too prominent and showy, yet many patients like the very results we steadfastly seek to avoid. As a dentist, part of your challenge is clearly understanding what your patient thinks is beautiful before you embark on transforming their smile. With so many options available, we believe that the best approach is the "tell, show, do" model.

Educating patients, then showing them how such options might look, is a practical and wise approach to adopt before performing the treatment. In this chapter, we consider some of the ways you might do this.



AESTHETIC DENTISTRY

Digital Smile Design (DSD)

“This technique incorporates digital technology into the smile design process” (McLaren, E.A. and Culp, L., 2013).
 “The DSD protocol is characterised by effective communication between the interdisciplinary dental team including the dental technician (Coachman, C. and Calamita, M.A., 2014)”.

Creation of a smile design allows reliable prediction and communication of aesthetic outcomes, aids in tooth preparation and temporisation, and assists in communication within the multidisciplinary team and the laboratory. Smile aesthetics are related to the colour, shape, texture, dental alignment, gingival contour, and the relationship of these with the face (Meereis, C.T.W., et al., 2016). When planning cosmetic restorations such as veneers on anterior teeth, digital smile design is critical to success.

In developing a digital smile design, the clinician typically uses 12 digital photos to record the patient’s appearance in portrait, smiling, retracted, occlusal and lip-at-rest states, and allow analysis of the facial and dental proportions. These photographs are manipulated to assess midline position, occlusal plane orientation and the length-to-width ratio of incisors. The role of the laboratory in DSD includes:

- Pouring or 3D printing of pre-operative models/scans for treatment planning, diagnostic waxing and medico-legal records.
- Construction of silicone reduction guides for tooth preparation.
- Construction of motivational trial smiles (laboratory-made resin mock-ups of the proposed restorations are able to be placed intraorally to demonstrate the likely outcome to the patient for visualisation and approval).
- Advice on most appropriate materials for case success.
- Construction of laboratory-made temporaries to ensure a “professional” appearance between visits.
- Construction of stents for direct restorative treatment (e.g. Penn Composite Stent™).
- Translation of the DSD prescription into indirect restorations (veneers, crowns, bridges).

Advantages of DSD Protocol

Aesthetic Diagnosis

Digital photography and digital analysis enables the clinician to visualise and analyse issues unseen clinically. Drawing reference lines and shapes over extraoral and intraoral digital photographs can be done with presentation software.

Communication

When the treatment co-ordinator of the restorative team has a good personal relationship with the patient, the patient can take responsibility for the smile design and enhance a successful outcome.

Feedback

The DSD permits evaluation of the results obtained in every treatment phase.

Patient Management

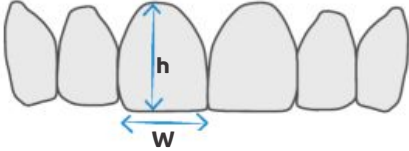
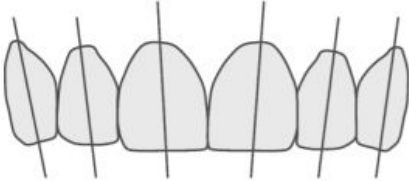
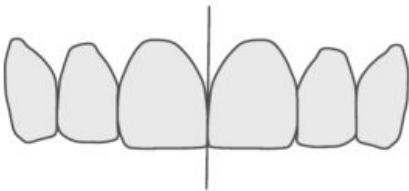

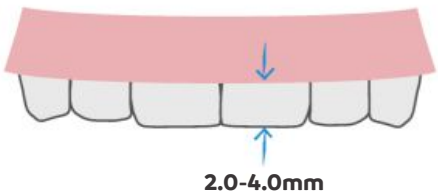
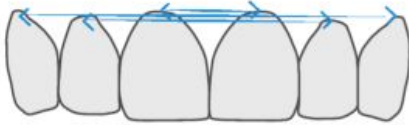
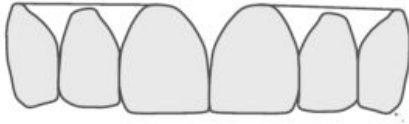
The treatment planning presentation will be enhanced as DSD enables patients to see and understand the multi-factorial nature of their concerns. By digitally altering tooth outlines, position, shade and other aesthetic attributes (e.g. gingival display) both the clinician and the patient can plan and view the projected outcome, allowing expectations to be clearly understood prior to case commencement.

Education

Presentations and lectures are enabled.

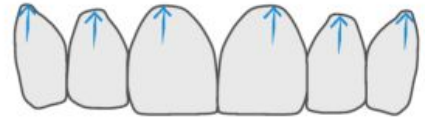
Principles of Smile Design

(Modified from Ostler, L., 2017, McLaren, E. A. and Culp, L., 2013)

Consideration	Explanation	What to Consider
Width:Height Ratio	<ul style="list-style-type: none"> Width:Height ratio percentage should be 75:80 e.g. width 8.0mm then height 10.0mm. 	
Mesial Inclination	<ul style="list-style-type: none"> Each upper tooth should have a tilt towards the midline and converge towards the navel. 	
Midline Placement and Cant	<ul style="list-style-type: none"> The position of the midline between the incisors should be on a line drawn from between the eyes and down through the nose, lips and chin. The angle of the midline should not be tilted to the left or right. It should be straight up and down. 	
Colour, Shading, Stains and Markings	<ul style="list-style-type: none"> Are the teeth a uniform bright colour? Presence of white/dark spots on enamel? 	
Smile at Rest	<ul style="list-style-type: none"> Balance and symmetry are important parts of an attractive smile. Evaluate number of teeth showing at rest or with slight smile. Middle-aged adults should show 2.0-4.0mm of the upper teeth. This amount decreases with age as the "window" of the mouth begins to sag downward showing more of the lower teeth. 	
Gum Margin Symmetry	<ul style="list-style-type: none"> Gum tissue frames the teeth. It forms a "curtain" for the teeth. Check height and scalloping of the gum line is symmetrical or evenly matched between right and left side. 	
Gum Margin Heights	<ul style="list-style-type: none"> Is level of gum line over the lateral incisor lower than the central incisor? The height of the gum line margin over the lateral incisors should be slightly lower than the height of the gums over the adjacent central incisor and canine teeth. 	

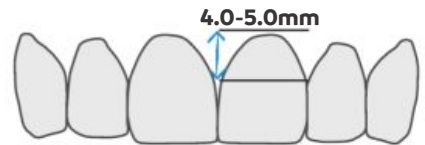
Gingival Zenith

- Check location of uppermost height of the gum line over each tooth.
- The height of the gum line across the face of each tooth varies from tooth to tooth. It should be centred over each lateral incisor.
- It should be two-thirds of the way across the face of the tooth for the central incisors.



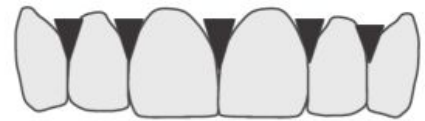Gingival Scalloping

- The ideal aesthetic relationship between gingival tissues and teeth requires 4.0-5.0mm of gingival scallop (the distance from the tip of the papilla to the zenith).



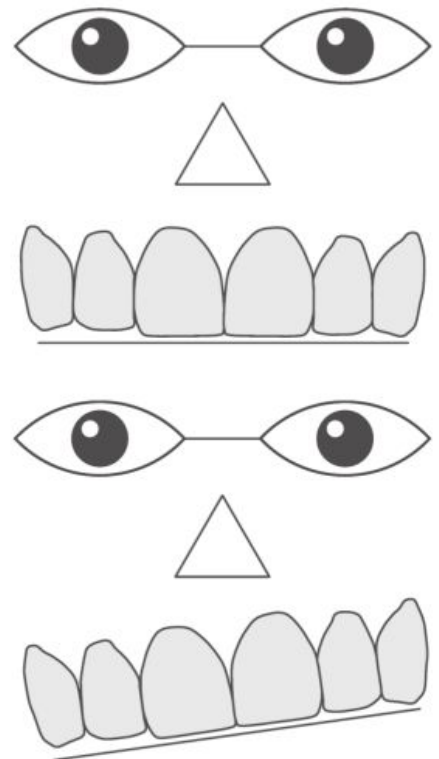
Black Triangle

- Teeth which are too far apart or have underlying bone loss result in papillae shrinkage and darkness in embrasures.
- Management may involve periodontal surgery and/or design of restorations with long contact points to cosmetically fill these voids.



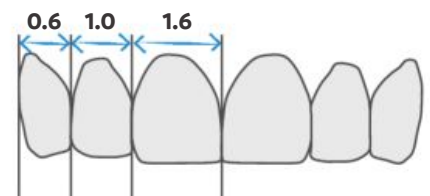
Horizontal Plane

- Are teeth on a parallel horizontal plane with the eyes or with the floor?
- The left to right horizontal plane of the mouth should be parallel to the floor or the horizon when standing and parallel to the interpupillary line.
- The horizontal plane from the front to the back of the mouth should also generally be parallel to the floor.



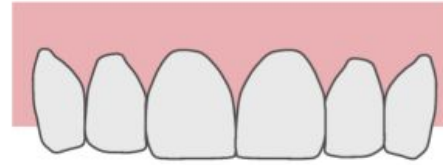
Golden Ratio

- The ratios of the width of the anterior teeth should follow the general principle of a tooth being approximately 2/3 the width of its more medial neighbour when viewed from the front.



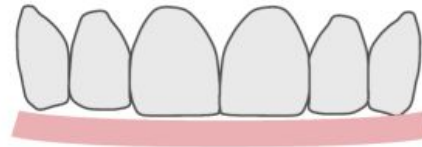
Gingival Display

- Does the patient display excessive amounts of gingival tissue upon smiling? A “gummy” smile compromises aesthetics. An aesthetic smile generally reveals no more than 2.0mm of gingival tissue above the gingival margins of the teeth while smiling.



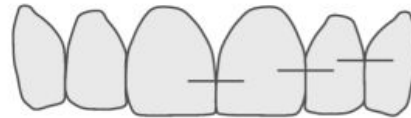
Smile Line Follows Lower Lip Line

- Does the smile line generally follow the lower lip line?
- The incisal edge of the upper teeth should be parallel or follow the contour of the lower lip line in a relaxed or slight smile.
- Upper teeth should be within 2mm of the lower lip when smiling.



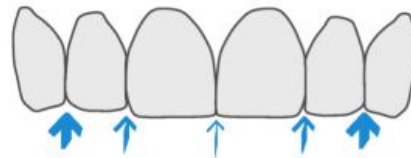
Flossing Contact Point

- The flossing contact point between the teeth should step upward with each tooth.



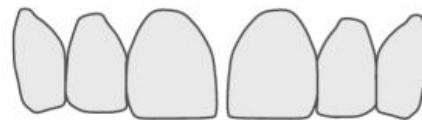
Incisal Embrasure

- Is there good definition and separation between the front teeth on the incisal edge of the teeth?
- The size of the outline shape between the front teeth should symmetrically increase in size moving away from the midline. This is best viewed as a triangular-shaped wedge between the teeth and on the biting edge of the front teeth. This follows the “rule of thirds”.



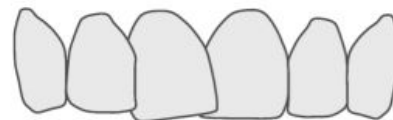Gaps or Diastemas

- Check for presence and size.
- Assess feasibility of closure through widening teeth and consider sequential aligner therapy or other orthodontic intervention if spacing is too large or asymmetrically distributed.



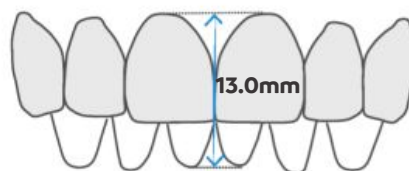
Anterior Crowding

- Crowded and/or rotated and/or tilted anterior teeth compromise dental aesthetics.
- Unless minor in nature, orthodontic intervention is usually required prior to definitive restoration placement, otherwise excessive tooth preparation and/or excessively bulky restorations will be required.



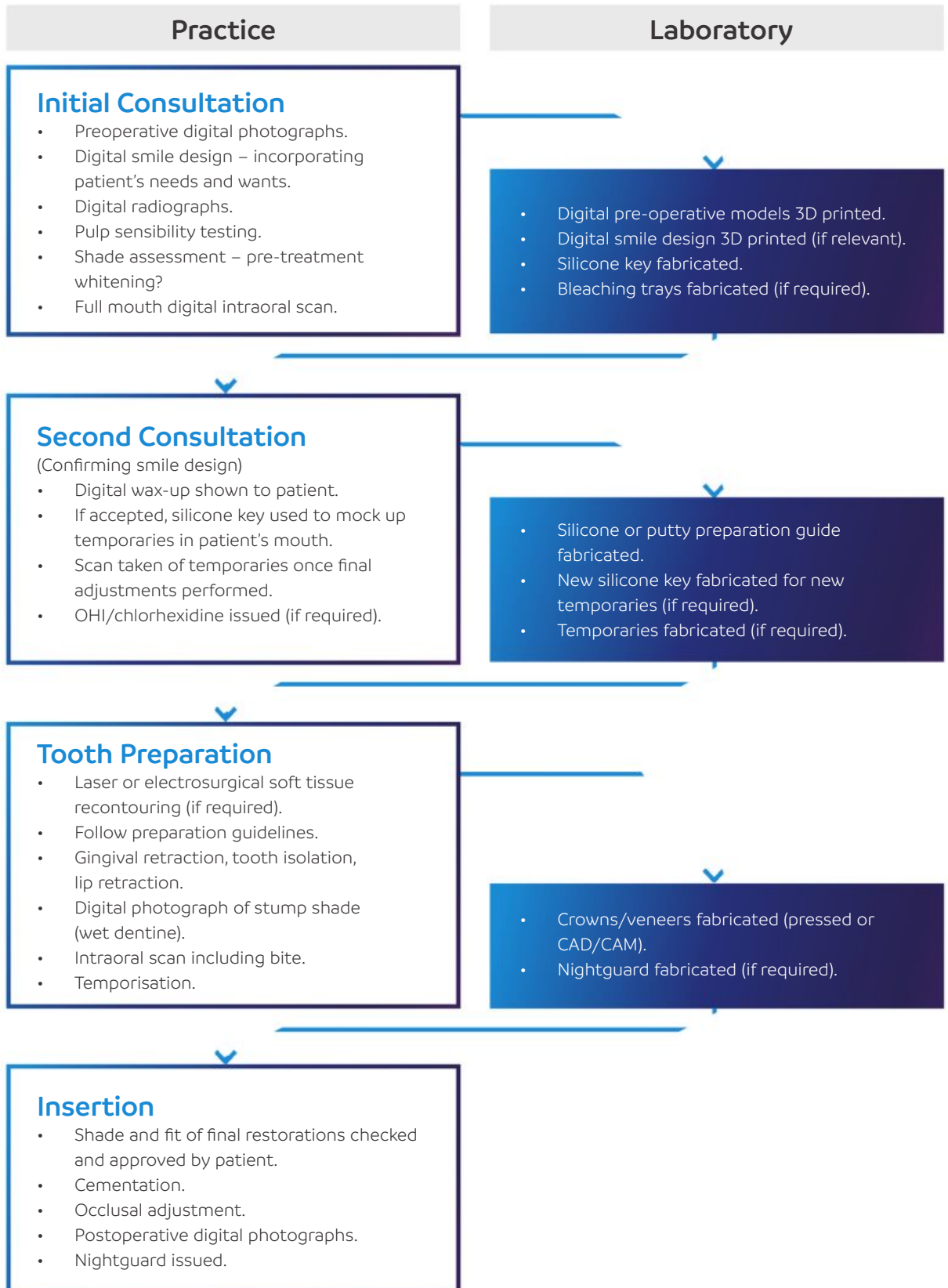
Overall Tooth Display

- Generally, about 13.0mm of tooth display is considered aesthetically pleasing when talking or smiling broadly.
- An excessive overbite may require orthodontic intervention to optimise aesthetic outcomes.



Practice-Laboratory Partnership in Digital Workflow

An example of a full digital cosmetic case workflow (adapted from Weston, J., 2016):



Bleaching and Orthodontics

CONSERVATIVE AESTHETIC TREATMENT OPTIONS

Dental Bleaching

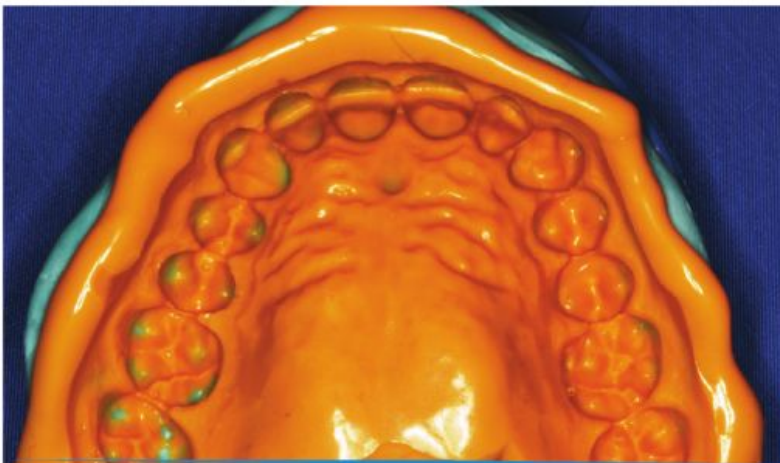
If tooth colour is the only reason for treatment, in-surgery bleaching, take-home treatments or a combination of the two may serve the purpose efficiently. If tooth colour has to match restorative resins, the bleaching procedure should be completed a few days before the colour of the bleached teeth is matched with the resin. This allows the colour of the bleached teeth to return to a stable shade. Wait at least two weeks after bleaching is completed before starting restorative procedures.

Dental bleaching may be combined with microabrasion techniques. Bleaching stents can also be used as medicament carriers for preventive therapeutics.

Orthodontic Therapy with Sequential Aligners

If patients choose an aggressive, quick fix elective restoration, e.g. placing ceramic veneers, particularly at an early age, (which require replacement of the restorations after several years at extra expense and even further biological cost) the patient should be informed of the irreversible, permanent commitment attached to the process.

Patients need to be advised that more conservative and less invasive orthodontic options exist to achieve aesthetic results. It is now possible to introduce an alignment phase into aesthetic dentistry with sequential aligners.



This 2-stage PVS impression has captured all the detail required in order to commence sequential aligner therapy.

Removable Orthodontic Appliances

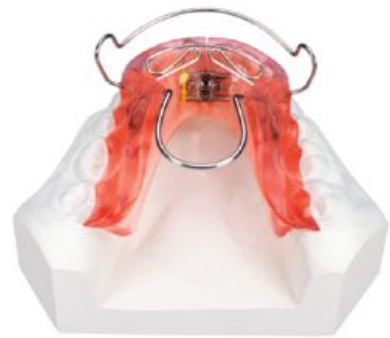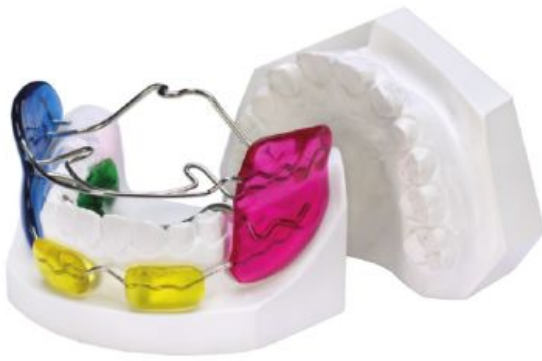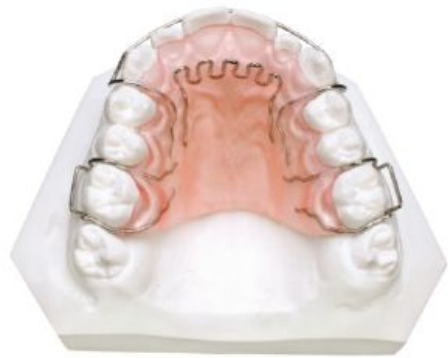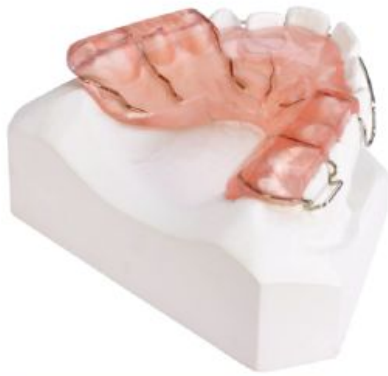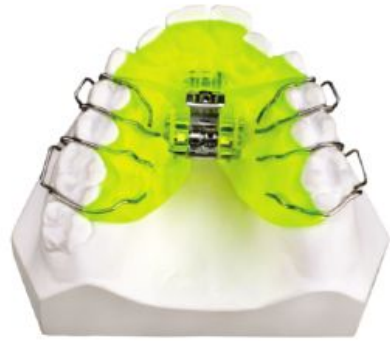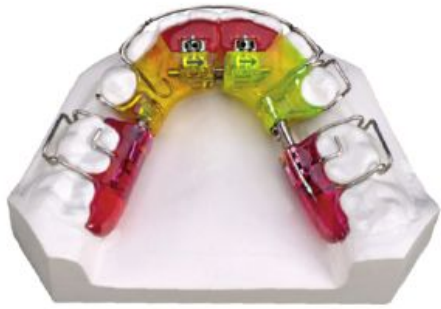Removable orthodontic appliances are often utilised during a course of treatment for limited tooth movement within the primary, mixed or permanent dentitions.

Active appliance:

- May be employed in upper or lower arch.
- Typically incorporate finger springs or elastics as the active component.

Passive appliance:

- May act as a retainer.
- Appliance examples: Hawley (Dr C. Hawley), Begg (Dr P. Raymond) and Essix® (Dr J. Sheridan).



Examples of removable orthodontic appliances.

Orthodontic Retainers

	Hawley/Begg	Essix®*	Lingual Wire in Memosil Key	Vivera®
Effectiveness – Anterior	✓ ✓	✓ ✓ ✓	✓ ✓ ✓	✓ ✓ ✓
Effectiveness – Posterior	✓ ✓	✓ ✓ ✓	–	✓ ✓ ✓
Cost	✓	✓	✓	✓
Longevity	✓ ✓	✓ ✓	✓ ✓ ✓	✓ ✓
Comfort	✓	✓ ✓	✓ ✓ – ✓ ✓ ✓ (Depends on tongue adapting to its presence)	✓ ✓
Removability	✓ ✓ ✓	✓ ✓ ✓	–	✓ ✓ ✓
Hygiene	✓ ✓	✓ ✓ ✓	✓	✓ ✓ ✓
Occlusal Settling	✓ ✓ (esp. Begg)	limited	✓ ✓ ✓	limited
Grinding Protection	–	✓ ✓ ✓	–	✓ ✓ ✓
Bleach/Medication Application	–	✓ ✓ ✓	–	✓ ✓ ✓
Ability to Store Digitally	–	–	–	✓ ✓ ✓
Ability to be Repaired	✓ ✓ ✓	–	✓ (limited)	–

*Essix appliance (Dr John Sheridan)

Aesthetic Recontouring

AESTHETIC RECONTOURING OF:

- A. Teeth** – Often, an unsightly appearance of the anterior teeth is related to unequal length of teeth or slightly rotated teeth. Simple tooth recontouring followed by smoothing and polishing of the affected tooth structure, followed by application of fluoride, can improve the unsightly condition at minimal expense, and without the need for further treatment. Conservative aesthetic recontouring is often required after orthodontic therapy, as previously imbricated anterior teeth often have significant wear patterns from being in a traumatic occlusion.
- B. Gingivae** – It is important to achieve symmetry of the gingival margins with a high smile line. When there is sufficient attached gingiva, and the clinical crowns need to appear longer, the level of the gingival tissues can be harmonised using electrosurgery or laser therapy.

In order to achieve good aesthetics, orthodontic therapy, tooth recontouring and gum recontouring may need to be followed with the placement of resin-based composite veneers.

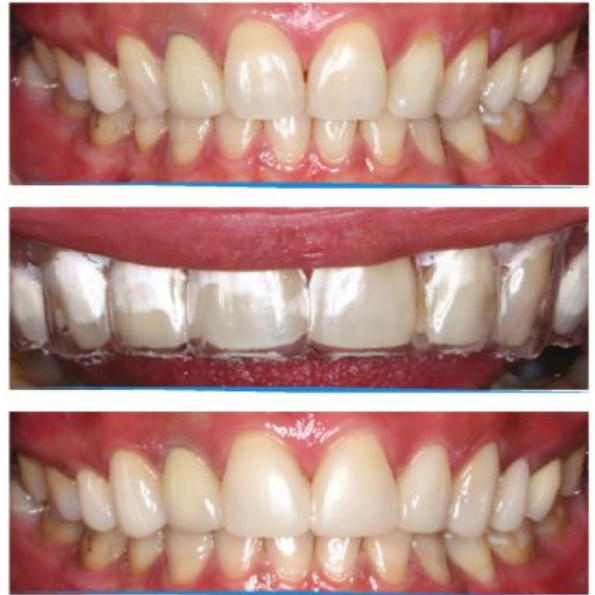
DIRECTLY PLACED RESIN-BASED COMPOSITE VENEERS

(Penn Composite Stent™, Pavona Pty Ltd)

Traditional direct bonding techniques added incremental composite that was bonded to enamel and then shaped initially by hand with flat plastics and then trimmed and polished. The technique yielded improved outcomes as materials evolved with better masking abilities in thinner diameters of material. Thus, veneers became less bulky with less need for preparation when colour change was critical.

The injectable direct composite veneer process was developed by Dr D. Penn in 2008 and is known as the Penn Composite Stent™. It is suitable for temporary or more intermediate solutions. Study models are evaluated for the most desirably shaped teeth for each case and a diagnostic wax-up provided for the dentist prior to stent fabrication. Further evolution of this technique occurred as the physical properties of flowable resins improved. The strength of the newest-generation flowable resins now matches that of traditional nano-filled resins, yet yields superior aesthetics.

Examples of the latest materials suitable for this technique are CLEARFIL MAJESTY™ ES Flow (Kuraray), BEAUTIFIL® FLOWPlus (SHOFU) and Premise™ (Kerr).

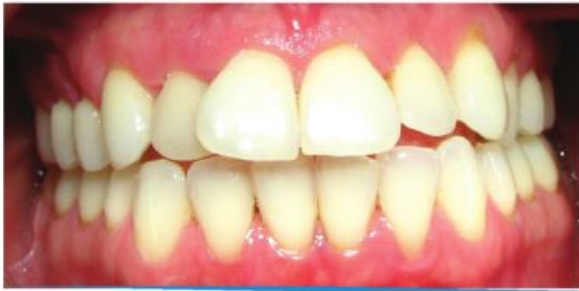

The Penn Composite Stent™ results in morphologically correct direct composite veneers.

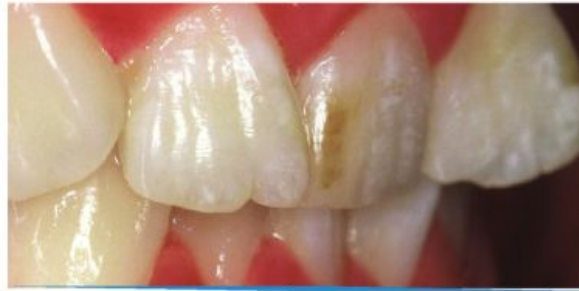Veneers with Little or No Preparation

Cautious and conservative preparation methods for veneers and crowns are the superior treatment option. Both fired-ceramic and pressed-ceramic veneers are popular because they are quick and easy to apply and do not require a local anaesthetic. They can easily improve unsightly teeth and are in high demand to fix peculiar tooth contours, tooth spacing and gum recession that exposes roots.

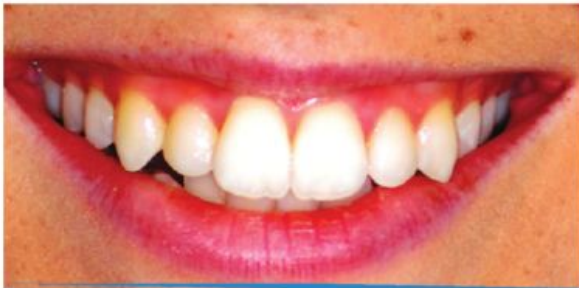Treatment Planning for Veneers	
Indications	Contraindications
Discoloured teeth unresponsive to tooth whitening or microabrasion procedures.	Should not be used to rectify malocclusions (Friedman, M.J., 2001).
Closure of interdental spacing and restore malformed teeth where crowns are contraindicated.	Heavily restored teeth, worn teeth and teeth with insufficient enamel for bonding.
Realignment of instanding/rotated or protruded teeth.	Teeth too weak to withstand functional forces (Layton, D. and Walton, T., 2007).
Alteration of discrepancies in size and shape of teeth not correctable by orthodontics alone.	Parafunctional activity and use of dentine substrate (Walls, A.W., 1995).
	Where the spaces requiring closure are too wide to be closed just by increasing tooth width alone.
	Non-vital teeth with significant discolouration.



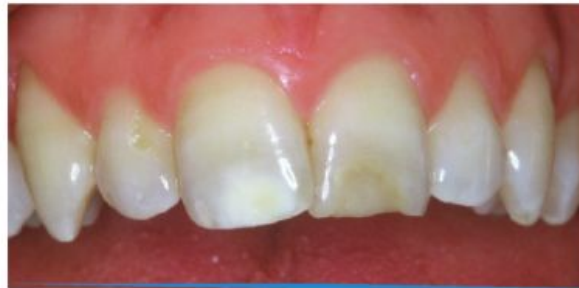A case exhibiting this degree of crowding is beyond the scope of ceramic veneers. This patient was treated with sequential aligner therapy.



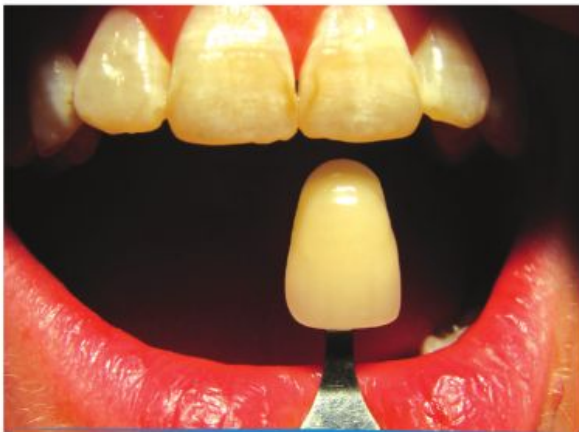The degree of rotation on the 2.1 was so severe that veneers were contraindicated without some orthodontic intervention beforehand.



This patient could have been treated successfully with ceramic veneers or sequential aligner therapy.



An ideal case for ceramic veneers with only minor imbrication and where arch shape, colour and morphology can be improved significantly.



Residual staining from hypoplasia after considerable bleaching can be successfully treated with thin ceramic veneers.

Advantages

- Minimally invasive.
- Aesthetically pleasing.
- Elicit a good tissue response.

Disadvantages

- Technique sensitive.
- Some tooth preparation required.
- Once placed, shade cannot be modified.
- Provisionalisation may be difficult.
- Delicate to manipulate prior to cementation.
- More costly than alternatives.

The Treatment Planning Process

An appropriate treatment plan evolves following a sequence of carefully considered steps (Newsome, P., et al., 2012):

Step	Evaluate
1. Collect and Collate Information	<ul style="list-style-type: none"> Information collected at history and examination visit including radiographs, photographs, study models and diagnostic wax-up. Understand patient's problems, wishes and expectations. Assess what constitutes a reasonable outcome.
2. Establish a Diagnosis	<ul style="list-style-type: none"> Determine cause of present condition and why treatment is required.
3. Treatment Options: Tooth Discolouration and Shade Selection	<ul style="list-style-type: none"> What needs to be changed and/or improved. Intrinsic discolouration - establish cause; e.g. ageing, habits, loss of vitality or congenital (tetracycline during tooth formation). One tooth/several teeth affected. Microabrasion/tooth whitening may be preferred. Heavily discoloured teeth may resist bleaching. Masking with a thin layer of ceramic, even with an opaque luting cement, may not be possible. Masking dark discolouration may involve tooth reduction into dentine and restoration with an all-ceramic crown bonded to dentine.
Tooth Shape	<ul style="list-style-type: none"> Where altered tooth morphology is required, a diagnostic wax-up helps to assess if correct proportionality can be achieved. Consider more conservative options – directly bonded composite resin or cosmetic recontouring.
Tooth Position and/or Spacing	<ul style="list-style-type: none"> Some small rotations can be corrected using veneers – small tooth spacing can be treated by directly bonded composite. Larger spaces can be treated using indirect veneers – severe tooth spacing or malalignment is corrected with orthodontic therapy followed by prosthodontics.
Old Restorations	<ul style="list-style-type: none"> Remove old restorations prior to veneer placement. Place new veneers within two weeks after composite replacement to ensure adequate bond strength. Full coverage restorations are more suitable for heavily restored teeth, which are weaker, perhaps non-vital and will have less enamel available for bonding.
Trauma	<ul style="list-style-type: none"> Veneers can restore teeth damaged by trauma. Consider the amount of enamel available for bonding, pulp vitality and crack lines. Evaluate the degree/quality of remaining enamel.
4. Formulate Final Treatment Plan	<ul style="list-style-type: none"> Veneers are not a "universal" solution. There are a number of alternatives to consider and the most conservative option is preferred before progressing to more invasive procedures (Dietschi, D., 2005). Evaluate the dentist's experience/skills and the laboratory support available.

The bond strength of porcelain bonded to enamel is still superior when compared with the bond strength of porcelain bonded to dentine (Van Meerbeek, B. et al., 1998). The use of Aesthetic Pre-evaluation Temporaries (APTs) provides an opportunity for both clinician and patient to evaluate the approximate final result (Gürel, G. and Gürel, G. 2003). Once the desired contours are achieved, veneer preparation can be performed according to the APTs regardless of existing tooth position.

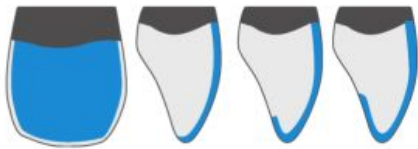Reduction Area Recommendations

Labial

- Use a diagnostic wax-up to:
 - » Visualise the final restoration(s)
 - » Make a stent as a guide to preparation (Javaheri, D., 2007)
 - » Be a template for provisionals (Bloom, D.R. and Padayachy, J.N., 2006)
- Stay within enamel – remove 0.75mm of enamel. (Christensen, G.J. and Christensen, R.P., 1991). The longevity is governed by the amount of enamel supporting it (Friedman, M.J., 2001).
- Remove the aprismatic top surface of immature unprepared enamel.
- Maintain the correct emergence profile.
- Avoid sharp line angles.
- Depth-cutting burs can be useful, except when:
 - » Veneers are being used to alter tooth contour
 - » A uniform reduction of the tooth surface is not required (Magne, P. and Belser, U.C., 2004)

Incisal

- Cover incisal edge (Smales, R.J. and Etemadi, S., 2004, Priest, G., 2004).
 - Avoid placing margins where there is a high degree of occlusal loading.
- The differences between the various recommended preparation designs, centre upon the following key areas:



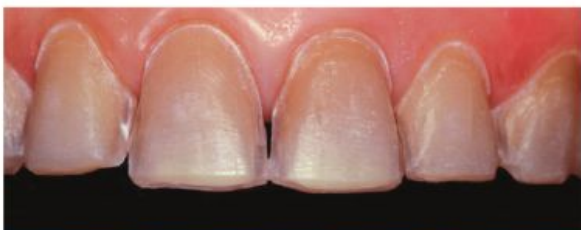Various different veneer incisal edge preparation designs have been advocated. Of these, the butt joint currently appears to be the most favoured.

Interproximal

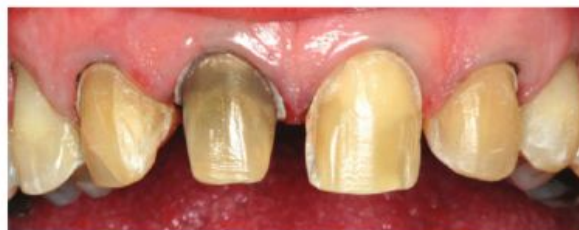- Break through the contact point:
- Ceramic can be “wrapped around” and the junction with the tooth hidden especially when masking dark teeth.
 - Results in tooth destruction with consequent problems, should drifting occur between preparation and cementation appointments.
 - Leave contacts in place.
 - Less tooth destruction and little chance of drifting.
 - Bonding may be difficult because of the tight space.
 - Ensure that the preparation is far enough into the embrasure to hide the margin.
 - “Visible” margins may not be a problem if the veneer is thin and there is little need for masking discoloration.

Cervical

- Staying in enamel here, where enamel thicknesses are as low as 0.3mm, is difficult (Cherukara, G.P., et al., 2005) and it is almost inevitable that dentine will be exposed.
- If it is not possible to remain within enamel, consider alternative treatment.
- Chamfer preparations are preferred.
- Decide where to place the cervical margin relative to the gingival level.
- Where tooth discoloration requires masking interproximally, margin will need to be subgingival.



These preparations are more conservative and well-defined.

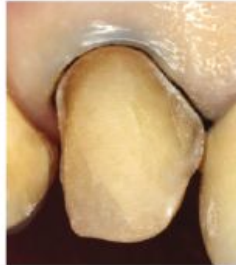

An endodontically treated upper central incisor in tandem with vital upper anteriors is challenging aesthetic dentistry.

Clinical Procedures For Ceramic Veneers

Pre-Prosthetic Workup

- Periodontal condition of the teeth undergoing preparation should be carefully managed prior to the restorative and impression stages.
- Use 0.12% chlorhexidine gluconate preoperatively, during the provisional restoration period and for two weeks postoperatively.

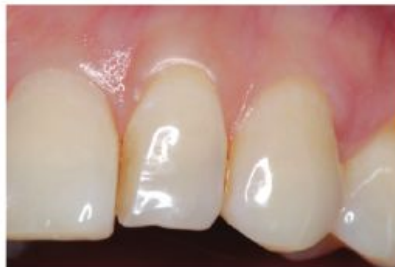

This textbook preparation depicts excellent soft tissue health and the tooth is being veneered to mimic a lateral incisor that was congenitally absent.

Confirm Tooth Condition and Existing Restorations

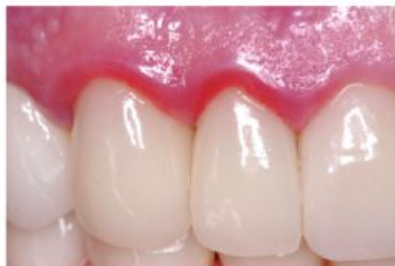- Protect exposed dentine with a primer to prevent postoperative sensitivity and bacterial invasion (Olgart, L., et al., 1974, Brännström, M., 1992).
- Application of dentine bonding agent immediately after completion of tooth preparation showed improved bond strength in vitro (Paul, S.J. and Schärer, P., 1997).

Confirm Correct Reduction Interproximally



The dreaded interproximally "show" of discoloured tooth structure from failure to extend the "elbow" far enough interproximally.

Confirm Correct Reduction Buccally



These veneers were overcontoured and were the result of no finishing line or reduction in the gingival third.

Check Occlusion

- Validate occlusion.

Impression Taking

- Excellent impressions are essential.

Retraction

- An extra-thin cord such as a #00 is placed into the sulcus following initial tooth preparation to deflect the tissue, allow more access, and serve as a depth gauge.
- Use a single cord when preparing equi/supragingival margins with healthy tissues.
 - Once the preparation is completed, a thicker, braided cord achieves tissue displacement. Remove after five minutes.
 - Leave initial cord in place and take impression.

Haemostatic Agents

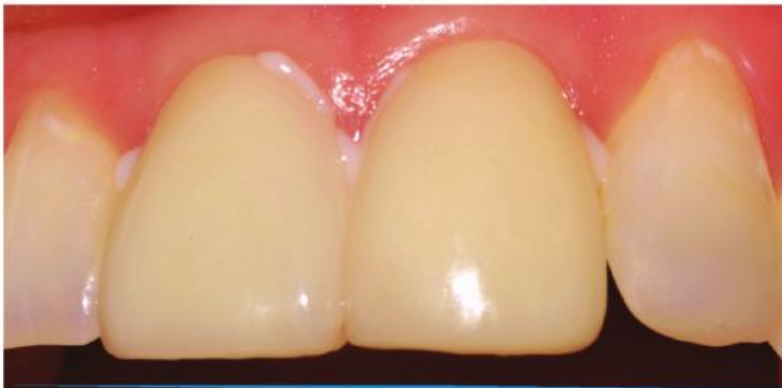- Used for unexpected bleeding during tooth preparation.
- All astringents negatively affect the bond strengths of adhesives to dentine.
- Wash the teeth after use of astringent.
- Then use chlorhexidine (O'Keefe, K.L., et al., 2005), 2% glycolic acid or an EDTA-based cleaning gel, which may assist in improving the bond strength.

Tray Selection	<ul style="list-style-type: none"> • Use full arch impressions (Shillingburg, H.T., et al., 2012).
Polyvinylsiloxane (PVS) Impression Materials	<ul style="list-style-type: none"> • PVS is easy to use, exhibits zero dimensional change during setting, and has good tear strength and wettability (Mandikos, M.N., 1998). • Single mix (a medium-body material is used in both the syringe and the tray). • Double mix (light body in the syringe, medium or heavy body in the tray). • Putty/wash (light body in the syringe and very heavy body in the tray). This technique is popular but prone to error. • All the margins should be recorded with light body.

Issuing Veneers

1. VERIFICATION OF FIT:

- Handle veneers with powder-free gloves to avoid risk of surface contamination.
- Check veneers fit on the working and untrimmed models and confirm that the ceramic has not been overtrimmed.
- A separate visit may be needed if changes are extensive and final laboratory finishing needed.
- Fitting surface must be etched. Best practice if done by the laboratory (Alex, G., 2008).
- If checking multiple veneers, check each individually.
- Use thin articulating paper interproximally to adjust heavy contact.
- Clean fitting surface of veneer. Recommend use of Ivoclean™ (Ivoclar Vivadent) or 37% phosphoric acid (Nicholls, J.I., 1988, Aboush, Y.E., 1998).
- Then use a water-soluble try-in paste. Use wedges if needed.



Try-in paste is an integral part of the veneer cementation process.

2. FOLLOWING TRY-IN AND CLEANING:

- Re-etch the veneer if needed.
 - » A two-part silane is mixed and painted onto the fitting surface of the veneer. Liquid must be clear. (Blatz, M.B., et al., 2003)
- Leave silane to dry (60 seconds).
- Clean prepared tooth with chlorhexidine 0.2%.
- Do not use prophylaxis paste with fluoride (can reduce the bond strength).
- Do not use pumice and water (may remain within dentinal tubules and reduce bond strength).

3. ETCHING THE TOOTH:

- Traditional "total-etch technique" with phosphoric acid.
- "Self-etch" technique:
 - » Produces less postoperative tooth sensitivity (Perdigão, J., et al., 2003).
 - » May eliminate residual bacteria and thus reduce the risk of secondary caries (Feuerstein, O., et al., 2007).
 - » Is recommended for preparations involving both exposed enamel and dentine.
 - » Do not cure the primer/bonding agent before seating as the veneer will not seat fully due to the film thickness of the self-etching bonding agent.

4. LUTING:

- Light-cure luting system is suitable for thinner veneers (i.e. less than 0.7mm thickness).
- A dual-cured luting system is suitable for thicker veneers (Cardash, H.S., et al., 1993).
- The efficiency of light curing is relative to the amount of light reaching the luting composite through the ceramic material.
- The colour and opacity of the porcelain have been shown to have less influence on the amount of absorbed light than veneer thickness (Linden, J.J., et al., 1991).

5. PLACEMENT:

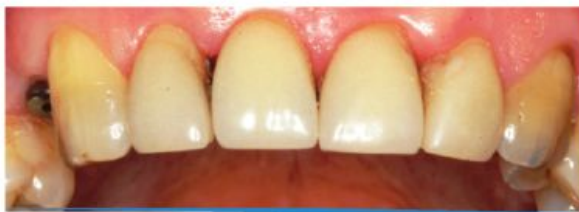- Place the two central incisors at the same time.
- Once the centrals are in place, complete one side before moving onto the contralateral teeth.
- The luting cement is placed in the veneer that is then seated onto the tooth, ensuring that excess cement is visible all around the margin. If not, then the veneer should be quickly removed and more cement applied.
- Place light pressure on the middle third of the veneer with a small condenser to fully seat. Remove gross excess with a microbrush.
- Light cure from buccal about 1.0cm from the tooth for no more than five seconds.
- Floss interproximally to ensure no excess cement is lodged between the teeth.
- Repeat curing for the palatal/incisal surface.
- The more hardened excess resin that needs removing, the more likelihood of removal of the glaze from the porcelain (Peumans, M., et al., 1998).
- Once all the excess cement has been removed, final curing can take place.

6. FINISHING:

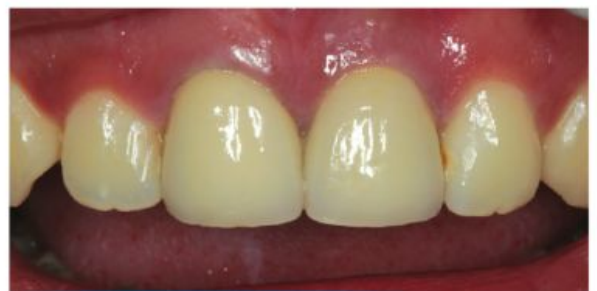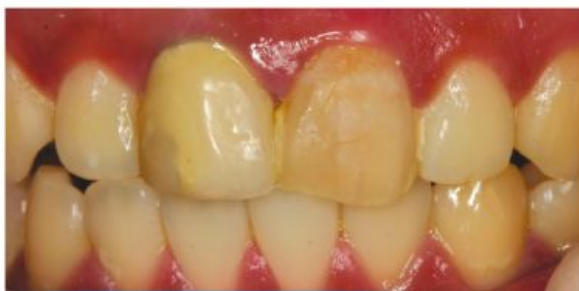- Best practice processes during placement should result in minimal finishing.
- If required, best to use a series of finishing grit diamonds followed by a 30-fluted carbide bur and polishing pastes (Haywood, V.B., et al., 1988, Goldstein, R.E., 1989).
- Polishing with water spray ensures a smoother surface than dry polishing (Haywood V.B. et al., 1988).

7. POSTOPERATIVE INSTRUCTIONS:

- Use less abrasive toothpaste.
- Floss as per normal teeth.
- No alcohol or mouthwash with alcohol during first 48hrs as this can affect the bond.
- Avoid hard foods, chewing ice, biting hard sweets, eating ribs, etc.
- A night splint is recommended.



Poor oral hygiene caused these veneers to fail.

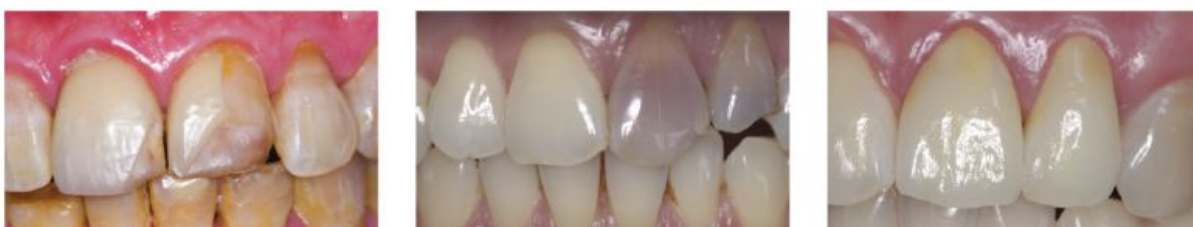

Poor hygiene and low expectations were managed prior to fabrication of veneers.

Veneer Failures

Note: Some require replacement, others might not (Fradeani, M., et al., 2005).

Reason	Explanation
Total De-Bond	<ul style="list-style-type: none"> Determine the interface where the failure has occurred (tooth/luting resin or veneer/luting resin) to prevent recurrence. Failure is more likely to occur at the tooth/resin interface as composite bonds tend to react better to etched silanated porcelain than to the tooth surface (Highton, R.M., et al., 1979). Bond failure can occur due to: <ul style="list-style-type: none"> » Inappropriate tooth preparation – excessive and/or uneven tooth reduction may mean the veneer will be bonded to a dentine substrate. Thus, a thick veneer will result and a possible failure of a solely light-cure luting resin to fully polymerise » Inadequate laboratory preparation (insufficient sandblasting and etching) » Failure of the patient to follow postoperative instruction (e.g. placing excess loading on the veneer during eating) » Patient's parafunctional habits Where a total de-bond occurs without damage to the veneer or underlying tooth, it may be possible to recement the veneer after removal of any excess luting cement from the tooth and/or veneer. Re-etch the ceramic-fitting surface. Any cracks/marginal discrepancies – take a new impression and remake.
Partial Fracture/De-Bond	<ul style="list-style-type: none"> Adhesive failure – rather than the whole bond failing and the restoration de-bonding intact, it fractures, leaving a portion still in place on the tooth. Cohesive fracture within the ceramic itself. <p>Repair may be possible with bonded composite; however, replacement is advised. A veneer may crack but not de-bond, so replacement may not be initially indicated.</p>
Inaccurate Seating	<ul style="list-style-type: none"> Any adjustment required at fitting should be minimal. If more major adjustment is required, veneer should be remade.
Colour Mismatch	<ul style="list-style-type: none"> Incorrect shade selection at initial consultation. Veneers can look slightly darker than adjacent natural teeth when bonding as teeth dehydrate and appear lighter. This should settle after a few hours. Veneer may not be able to adequately match adjacent unrestored teeth. Different shades of luting cement can only marginally change the shade of the overlying veneer. Colour change may also occur over time due to oxidation of aromatic tertiary amines used in dual-cure resins.
Poorly Finished Veneers	<ul style="list-style-type: none"> Should finishing be required, use a series of finishing grit diamonds followed by a 30-fluted carbide bur and polishing pastes with copious water spray.
Marginal Discolouration	<ul style="list-style-type: none"> For minor discolouration, clean the affected margin and then reseal with a flowable composite. This becomes more difficult for more significant discolouration especially with visible evidence of a crevice along the margin.
Marginal Integrity Loss	<ul style="list-style-type: none"> For minor breakdown, a flowable composite may be tried to reseal the margin. Preferred treatment is to replace the veneer.
Postoperative Sensitivity	<ul style="list-style-type: none"> The more the preparation is in dentine, the greater the risk of sensitivity. Seal any exposed dentinal tubules when freshly cut and etch as prescribed.



This sportsman had the 21 and 22 treated endodontically and required two IPS e.max® crowns (opaque ingots) as veneers were incapable of masking the discolouration.

07

CROWN AND BRIDGEWORK



Overview

Too much freedom inhibits choice. Constructive narrowness clarifies choice.


– Walter Darby Bannard.

Once upon a time we had just three realistic choices for the indirect restoration of teeth: gold alloy, PFM and feldspathic porcelain. Life was so simple then. For some of us, less seemed to be more.

Nowadays, the broad range of options can be bewildering. Which material is best? If I choose that material, how much preparation must I provide? How do I ensure I cement it so that it stays put comfortably and doesn't cause my patient (and me) any grief down the track?

At Modern Dental Pacific, we're happy to support dentists through their decision-making process. However, because we believe that it is better to know your best options ahead of time, we've included lots of practical information in this chapter about crown and bridgework.

You might like to refer to this chapter as you plan your cases. It's a great tool for narrowing down possibilities in order to determine what's best for your patient.



CROWN AND BRIDGEWORK

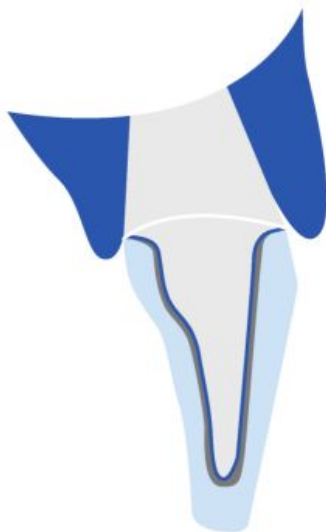
Tooth Preparation Concepts

1. CORONAL SUPPORT:

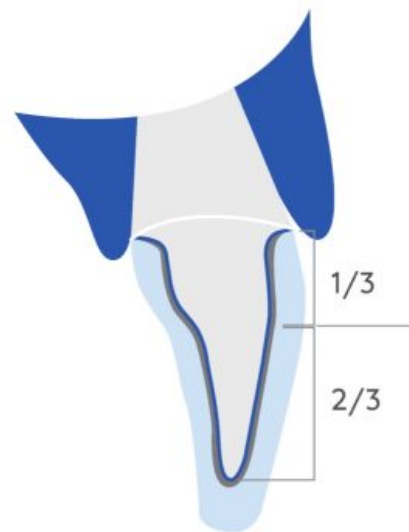
- When more than one-half of the coronal tooth structure is missing, build up the tooth with restorative material for more retention.
- Undercuts and channels may be needed.

2. AXIAL WALL PREPARATION:

- Proper axial reduction provides retention and resistance form to the preparation and enhances structural durability (Shillingburg, H.T., et al., 2012).
- Two-plane buccal reduction of anterior teeth:
 - » Confers structural durability
 - » Improves resistance and retention
- Inadequate reduction of axial wall results in overcontouring and compromised aesthetics.



Straight plane preparation produces hot spots.



Even two-plane reduction produces more predictable aesthetics or bright opaque area.

3. TOOTH REDUCTION ON INCISAL/OCCLUSAL SURFACES:

- Follow previous contour of the tooth inclines.
- Reduce evenly to enhance structural durability.
- Use depth groove burs to guide uniform reduction.

4. TOOTH FORM:

a. Conserve Tooth Structure:

- Where buccal and lingual walls of a PFM preparation meet, a wing is formed. This enhances resistance and retention.
- Perform minimal cingulum reduction.
- Maintain palatal walls in anterior teeth.
- Overpreparation can cause pulpal damage and compromise strength and retention.

b. Ensure Circumferential Irregularity:

- Maintain form of tooth during crown preparation. Maxillary molars are rhomboidal; mandibular molars are rectangular; premolars and anteriors are oval.

c. Conserve the Corners of the Preparation:

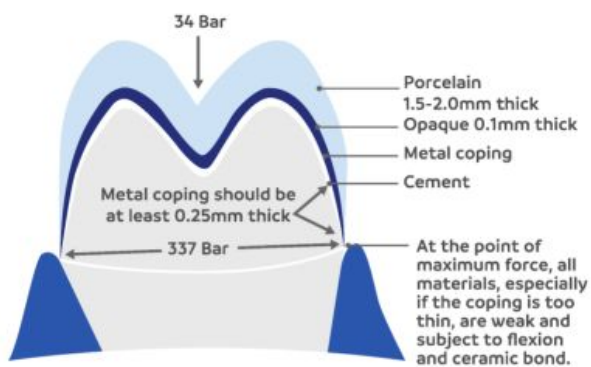
- Where line angles meet, they should be smooth and rounded.

d. Use Axial Grooves and Boxes to Increase Retention:

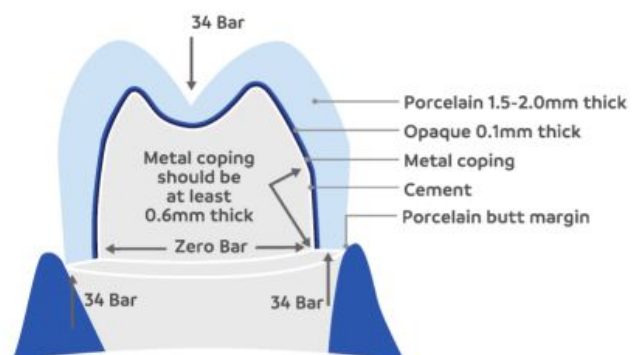
- Proximal grooves provide more resistance to buccolingual crown dislodgement.
- Buccal or lingual grooves provide only partial resistance (Woolsey, G.D. and Matich, J.A., 1978).

5. TOTAL OCCLUSAL CONVERGENCE (TOC):

- TOC is the angle formed between two opposing prepared axial surfaces.
- The ideal TOC should be from 10-22° (Shillingburg, H.T., et al., 2012).
- Use a mirror to view the buccal and lingual preparation from the occlusal perspective. Both eyes should be used (MACK P.J., 1980).
- Some situations predispose to greater TOC and placement of grooves or boxes may be needed.
- Posterior teeth are often prepared with greater TOC than anterior teeth (Norlander, J., et al., 1988).
- Mandibular teeth have been prepared with greater convergence than maxillary teeth (Kent, WA., et al., 1988). The greatest TOC occurs with lower molars.
- Mesiodistal surfaces have less convergence than buccolingual surfaces (Annerstedt, A.L., et al., 1996).
- Individual crowns can be prepared with less TOC than bridge abutments.



This tooth was underprepared with a knife-edge finish. This knife-edge finish generates a high flexing force when the crown is fitted, which bends the metal and the ceramic can de-bond. As a result, the technician was forced to make the coping and porcelain ultra-thin to accommodate the preparation.



This tooth had an ideal preparation with a shoulder, which minimises the possibility of metal flexion upon cementation.

6. TOOTH HEIGHT:

- Anterior teeth and premolars should have a minimum occlusocervical (OC) dimension of at least 5.0mm when they are prepared with a TOC in the range of 10-20°.
- Molars should have a minimum OC dimension of 4.0mm.
- When the OC dimension is less than ideal, proximal grooves/boxes are advised.

7. MARGIN DESIGN:

All-Metal Crowns:

- Use a chamfer 0.3-0.5mm to minimise stress (Proos, K.A., et al., 2003).
- Use a tapered round-end diamond bur.

Lithium Disilicate (Veneered and Monolithic):

- Use shoulder if not being bonded.
- Use chamfer/shoulder if bonding.
- Opaque porcelain systems or discoloured teeth require buccal reduction > 1.0mm.

Monolithic Zirconia:

- Use a chamfer 0.3-0.5mm.

Metal-Ceramic Crowns:

- Use shoulder/metal chamfer or all-ceramic margin 360° anteriorly.
- Use metal chamfer or all-ceramic margin 360° posteriorly.

CLINICAL TIP

Biologic Width

A violation in the biologic width causes chronic gingivitis around anterior restorations if margins are situated too far into the sulcus. Deep margin placement into the sulcus makes retraction difficult and increases the chance that the damage will be irreversible, causing recession.

The ideal restorative margin placement should be 0.5mm from the healthy free gingival margin, which is at least 3.0mm from the alveolar crest. The most atraumatic way to avoid soft tissue injury is by use of rotary instruments (tissue protection end-cutting burs).

8. MARGIN PLACEMENT:

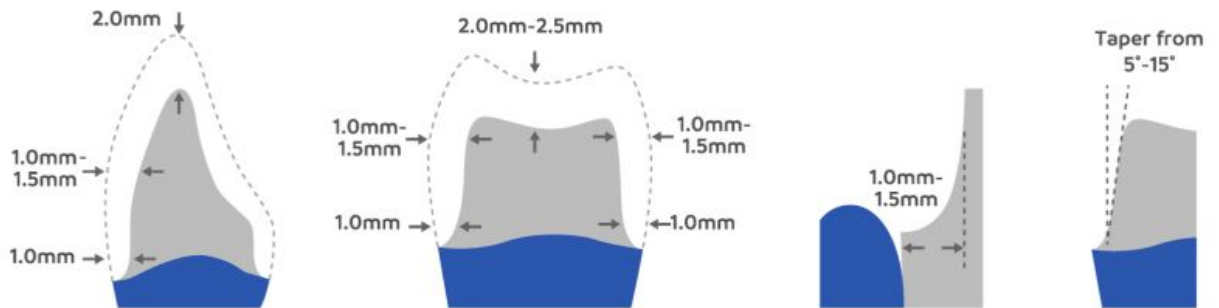
- Margins should ideally be positioned equi- or supra-gingivally (VALDERHAUGW, J. and Birkeland, J.M., 1976).
- In critical areas, it is necessary to:
 - » Ensure total caries control
 - » Achieve adequate crown height
 - » Account for discoloured teeth and teeth with morphological irregularities
 - » Bypass cracks, fractures and lesions related to erosion and/or abrasion
- The margin should be placed just into the gingival sulcus. The smile line and the amount of soft tissue shown should be evaluated before determining the position of the margin when anterior restorations are placed.
- Around 25% of patients do not show anterior gingival tissues even in the presence of a normal or wide smile (Rosenstiel, S.F., et al., 2016).
- The ferrule effect is important for endodontically compromised teeth.

Anterior	All-Ceramic (e.g. IPS e.max®)	Incisal reduction	2.0mm	
		Buccal/lingual	1.0mm	
		Reduction shoulder	0.8-1.0mm	
	Metal-Ceramic (Porcelain-Fused-to-Metal)	Incisal reduction	2.0mm	
		Lingual reduction	0.5-1.0mm	
		Labial shoulder/heavy chamfer	1.5mm	
		Lingual chamfer	0.5mm	
		All-ceramic margin 360°	1.5mm	
	Porcelain-Fused-to-Zirconia	Incisal reduction	2.0mm	
		Lingual reduction	0.6-1.0mm	
		Chamfer	0.5-1.0mm	
		Buccal reduction:		
		If buccal reduction is > 1.0mm: <ul style="list-style-type: none"> • High-value/low-chroma shades → minimal shade improvement • Lower-value/higher-chroma shades (C2, A3) → improved shade This relates to opaceous all-ceramics (e.g. Lava™ Zirconia Classic Frame/PFZ).		
	Posterior	All-Metal + Monolithic Zirconia	Chamfer	0.3-0.5mm
			Axial reduction	0.5-0.8mm
Occlusal reduction			1.0-1.5mm	
Buccal reduction – non-functional cusps			1.0mm	
Buccal reduction – functional			1.5mm	
Lingual reduction – non-functional cusps			1.0mm	
Palatal reduction – functional			1.5mm	
Veneered Zirconia		Shoulder/heavy chamfer	1.0mm	
		Buccal reduction – non-functional cusps	2.0mm	
		Buccal reduction – functional	2.5mm	
		Lingual reduction – non-functional cusps	2.0mm	
		Palatal reduction – functional cusps	2.5mm	
Metal-Ceramic (Porcelain-Fused-to-Metal)		Metal chamfer	0.5mm	
		All-ceramic margin 360°	1.5mm	
		Occlusal reduction:		
		If metal occlusion, as for full metal crown	1.0-1.5mm	
		Buccal reduction – non-functional cusps	2.0mm	
		Buccal reduction – functional cusp	2.5mm	
		Lingual reduction – non-functional cusp	2.0mm	
		Palatal reduction – functional cusp	2.5mm	
		Labial shoulder	1.5mm	
	This will create enough space for the occlusion.			

The occlusal reduction should include a functional cusp bevel on the palatal incline of upper palatal cusps and buccal inclines of lower buccal cusps (Shillingburg, H.T., et al., 2012).

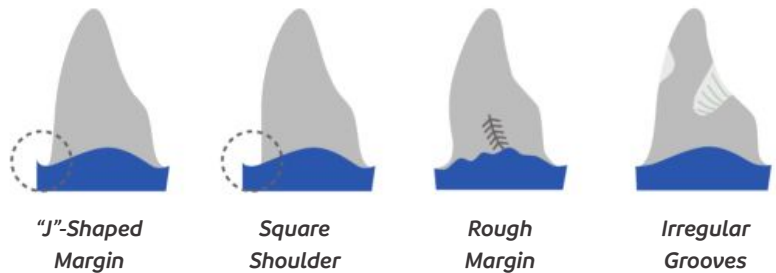
All-Ceramic Crown Preparations

IDEAL PREPARATION FOR ALL-CERAMIC RESTORATIONS (EXCLUDING MONOLITHIC ZIRCONIA)

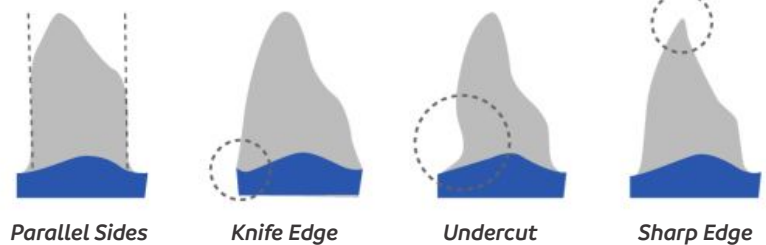


The ideal preparation should be smooth and have a chamfer or slight shoulder margin with no sharp edges or irregular grooves. For best results, apply 1.5mm-2.0mm occlusal reduction, 1.0-1.5mm circumferential reduction and around 1.0mm reduction near the cervical region. Retentive elements, if required, should have a minimum radius of 0.5mm.

No!



Avoid



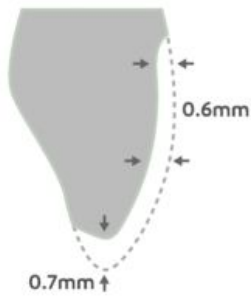
A proper cement space cannot be milled. The coping will be either too tight or too loose.

Procera® – mildly knife-edged margin is possible but will increase the risk of coping failure.

Undercuts and sharp edges are undesirable and need to be blocked out during production.

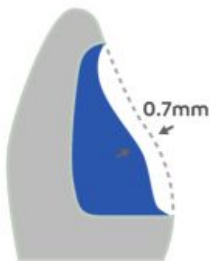
Lava™/PFZ – either a thin line of zirconia will be visible at the margin or alternatively, the emergence profile will have to be overbuilt.

IDEAL PREPARATION FOR ALL-CERAMIC RESTORATIONS



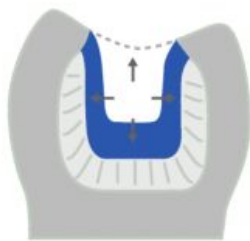
Veneer:

- $\geq 0.6\text{mm}$ labial and cervical reduction (do depth cuts).
- $\geq 0.7\text{mm}$ incisal reduction.
- Incisal preparation margins must avoid areas of static or dynamic contact.
- Bevel the incisal one-third back to the lingual incisal edge.
- Lingual preparation is not needed on all veneers. It can be used on the lingual aspect of the cuspid to re-establish canine rise.
- IPS e.max[®] thin veneer (0.3mm) is possible and requires little to no preparation.



Maryland Bridge:

- 0.5-0.7mm lingual reduction for metal.
- 0.8-1.2mm lingual reduction for zirconia or nanoceramic (reinforced with mesh) and higher clearance required.
- Preparation should be in enamel instead of dentine.
- Use of retentive element is recommended – either a groove, a ridge or a pinhole.
- Retentive element must have a minimum radius of 0.5mm.
- Circular/island preparation of wings is not possible.



Inlay/Onlay:

IPS e.max[®]

- $\geq 1.5\text{mm}$ preparation depth.
- $\geq 1.5\text{mm}$ isthmus width.
- 6° sidewall taper.
- Proximal box should have diverging walls.
- Inlay bridge – contraindicated.

CERAMAGE[®]

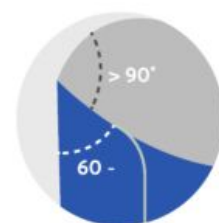
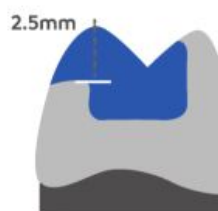
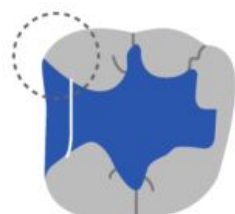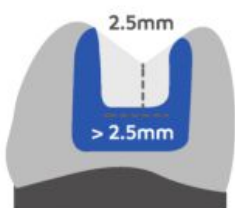
- 2.5-4.0mm preparation depth.
- $\geq 2\text{mm}$ isthmus width.
- 2-3° sidewall taper.
- Proximal box should have diverging walls.

PREPARATION OF INDIRECT COMPOSITE INLAYS AND ONLAYS

The main feature of such restorations is the use of butt joint margins. These are recommended throughout the preparation since bevelled margins:

- Can break off easily during seating if thin.
- Are more likely to fracture under occlusal forces.
- Are more difficult to prepare.
- Are more difficult to finish in the laboratory.
- Tend to remove more tooth structure.

Recommendations for Specific Restorations:



Inlay preparation. The preparation depth should be a minimum of 2.5mm. The axial walls of the proximal box should be flared slightly so that the enamel margin does not form an acute angle.

Onlay preparation. The overlaid portion should be at least 2.0mm deep. Forget conventional gold-only preparations – this is a totally different material that needs bulk at the margins wherever possible.

INLAYS

The basic principles are shown. Essentially, the preparation should be a minimum of 2.5mm deep, with rounded internal line angles preferred. Recommended practice is to place a dual-curing glass ionomer lining cement over all deep dentine. Any roughness and deficiencies in enamel are removed so that there is a very smooth margin. Internal dentinal undercuts, however, need not be removed as they will be blocked out in the laboratory and filled with resin luting agent at cementation. However, the smaller such voids are, the less will be the degree of shrinkage of the luting cement. At least 10-15° of taper towards the occlusal is recommended. Since 100% of the restoration will be bonded, nearly parallel walls are not needed and could pose a problem during seating.

ONLAYS

The same principles apply to onlay preparations. Again, butt joints are essential, plus any cuspal reduction should be at least 2.0mm. An adequate thickness of material is essential as strength is directly proportional to the bulk of material when loaded vertically.

Suggested Burs for Preparation of Full Crowns/PFM/All-Ceramic Crowns

Restoration	Preparation Area	Bur
Full Metal Crown	Occlusal reduction & functional cusp bevel	Coarse grit round end tapered
	Proximal axial reduction	Medium grit short needle & coarse grit round end tapered
	Buccal & lingual axial reduction	Coarse grit tapered torpedo
	Chamfer & axial finish line	Fine grit tapered torpedo
PFM Anterior	Incisal & labial reduction	Coarse grit flat-end tapered
	Lingual reduction	Coarse grit oval-shaped
	Initial proximal reduction	Medium grit long needle
	Lingual axial reduction	Coarse grit tapered torpedo & fine grit tapered torpedo
PFM Posterior	Occlusal reduction & functional cusp bevel	Coarse grit round end tapered
	Buccal reduction (2 planes)	Coarse grit flat-end tapered
	Proximal axial reduction	Medium grit short needle
	Lingual & axial reduction	Coarse grit tapered torpedo & fine grit tapered torpedo
	Buccal, axial and shoulder finishing	Fine grit flat-end tapered
All-Ceramic	Incisal & labial reduction (2 planes)	Coarse grit flat-end tapered
	Lingual & axial reduction	Coarse grit flat-end tapered
	Lingual reduction	Coarse grit oval-shaped
	Axial wall & radial shoulder	Fine grit flat-end tapered

Grit ■ Coarse ■ Medium ■ Fine

■
Round end tapered
ISO 856

■
Flat end tapered
ISO 847

■
Flat end tapered
ISO 847

■
Torpedo tapered
ISO 877

■
Short needle
ISO 852

■
Long needle
ISO 850

■
Oval
ISO 379

■
Torpedo tapered
ISO 877



Suggested Preparation Features for Crowns

		Reduction	Finish Line Depth & Configuration
Anterior Crowns	All-Ceramic (Veneered or Monolithic) IPS e.max® or IPS Empress Esthetic®	2.0mm incisally. 1.0mm buccal/lingual.	0.8-1.0mm shoulder.
	Porcelain-Fused-to-Zirconia	2.0mm incisally. 0.6-1.0mm lingual aspect (porcelain guidance requires greater clearance).	> 0.4mm chamfer lingually. > 1.0mm labial.
	Metal-Ceramic (Porcelain-Fused-to-Metal)	2.0mm incisally. 0.5-1.0mm lingual aspect (porcelain guidance requires greater clearance).	1.5mm labial shoulder or heavy chamfer. 0.5mm lingual chamfer. 1.5mm circumferentially for 360° ceramic margin.
Posterior Crowns	Full Contour Crowns (FCC) (Metal or Zirconia)	1.0mm non-functional cusps. 1.5mm functional cusps.	0.3-0.5mm shoulder or heavy chamfer.
	All-Ceramic (Veneered or Monolithic) IPS e.max® or IPS Empress Esthetic® Porcelain-Fused-to-Zirconia	2.0mm non-functional cusps. 2.5mm functional cusps.	1.0mm shoulder or heavy chamfer.
	Metal-Ceramic (Porcelain-Fused-to-Metal)	If metal occlusal, as with FCC. If porcelain occlusal: • 2.0mm non-functional cusps • 2.5mm functional cusps	1.5mm labial shoulder or chamfer. 0.5mm lingual chamfer (metal collar). 1.5mm circumferentially for 360° ceramic margin.

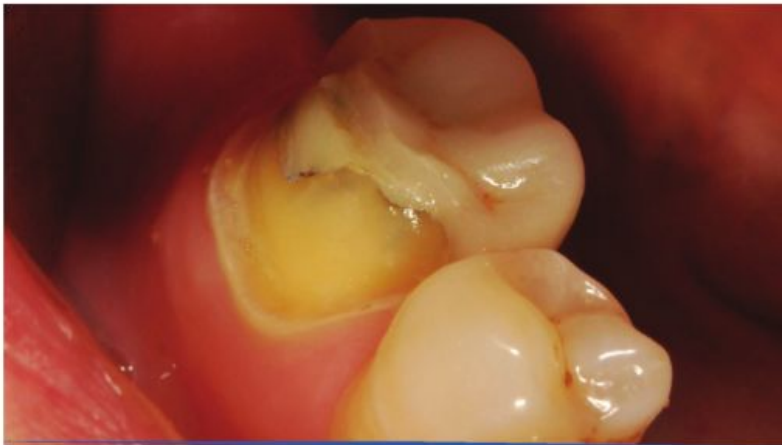Common Errors to Avoid When Preparing Crowns for All-Ceramic Restorations

SHARP INTERNAL LINE ANGLES

Can cause:

- Minor to major problems with fitting and seating.
- Premature stress fracture at the seating appointment or soon after cementation.

Use any tapered, fine diamond bur or a Sof-Lex™ Finishing and Polishing System (3M ESPE) disc.



*Why did this fracture occur?
Occlusal loading can often be the cause and is often exacerbated by sharp internal line angles that propagate cracks in ceramic copings.*

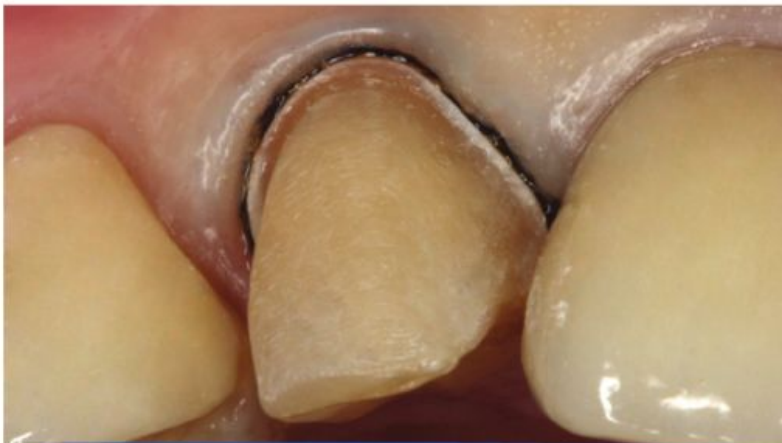BEVELLED OR FEATHER MARGINS

Porcelain is difficult to fabricate and finish over any bevelled or feather margin as it has a higher chance of fracturing during try-in or after cementation.

Ensure definitive chamfer or shoulder of minimum width 1.0mm.

Shallow or non-existent chamfers or shoulders result in bulky, less aesthetic crowns with poor emergence profile.

If an old PFM restoration is being replaced with an existing bevelled (metal) margin, and it cannot be modified into a definitive chamfer or shoulder margin, then employ a PFM as the replacement crown.

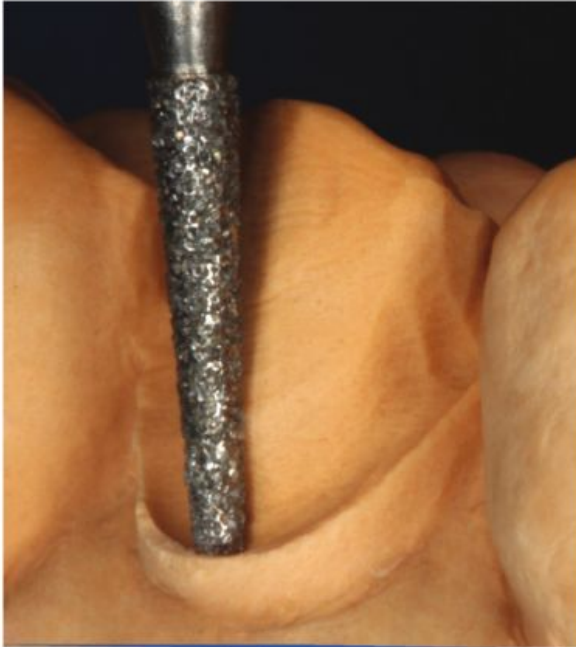


The margins of this all-ceramic crown preparations are well-defined and the line angles have been smoothed as much as is practicable.


“J” MARGIN (GROOVED MARGIN)

This unintended creation occurs when the apex of the diamond passes the edge of the margin and creates a groove inside the margin. Do not exceed a depth into the tooth equal to more than one-half of the width of the chamfer diamond bur tip.

Convert a “J” margin into a modified shoulder margin by reducing the outer lip with an end-cutting bur.



A “J” margin is created when the apex of the chamfer bur passes the edge of the margin, creating a groove.



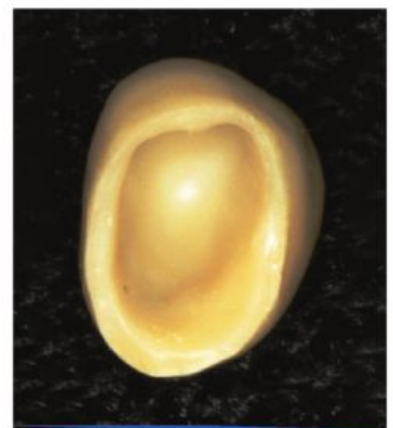An end-cutting bur (tissue protected) provides well-defined chamfers and rounded shoulders that are ideal for all-ceramic crowns.

INCOMPLETE AND/OR NON-UNIFORM SHOULDER

Causes:

- a. Porcelain in the cervical areas varies in thickness, with potential for premature fracture during fabrication, seating or after cementation.
- b. Aesthetic problems can occur when the underlying abutment shade affects the final colour in the thinner areas of porcelain.

Round any sharp spicules to reduce the potential for stress fractures. After shoulder preparation with a shoulder bur, refine the shoulder with an appropriately sized end-cutting bur.

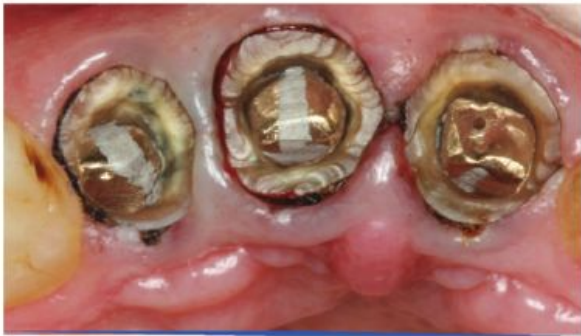

The operator produced well-defined margins. The thickness varied significantly which may fracture in the thinner, weaker areas under load.

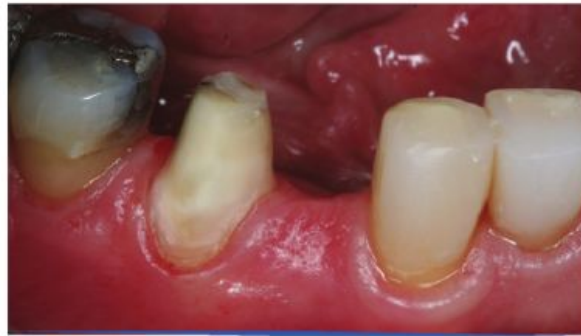INADEQUATE REDUCTION:

- a. Labially:
 - Inadequate axial wall reduction leaves inadequate room for the coping and veneering ceramic.
 - Avoid “Buccal Belly” – ensure unimpeded visual access from preparation to gingival margin.
- b. Occlusally/lingually:
 - Under-reduction on the occlusal aspect of all-ceramic crown preparations threatens the stress-bearing ability of the restoration and bond between the veneering ceramic and underlying restoration.

If the proper anterior coupling cannot be accomplished with anatomic reduction of the maxillary teeth alone, consider other alternatives – e.g. opening of the occlusal vertical dimension.



These preparations on endodontically treated teeth needed to be prepared slightly subgingivally to mask the dark root surface. The margins need to be smoothed to remove the gouge marks from the shoulder bur.



The margins of this all-ceramic preparation are indistinct. Circumferentially, sharp line angles exist on the occlusal aspect and further occlusal height reduction also needs to be done.

Resin-Bonded Bridges

Resin-bonded bridges have been associated with lower retention rates than conventional bridgework. However, recent studies have shown that with improved design, in terms of framework placement and tooth preparation, these bridges are lasting longer than the earlier pioneering prostheses.

Advantages:

- Conservative nature of abutment preparations.
- Retainer margin of a resin-bonded bridge can be placed supragingivally, which facilitates periodontal health and simplifies impression procedures.
- Preparations are more conservative and largely confined to enamel and can be done without local anaesthesia.
- Suitable for apprehensive and younger patients.
- Less chairside and laboratory time and hence reduced costs.
- Resin-bonded cantilever bridges replacing single anterior teeth have been reported to have the lowest de-bond rate.

Disadvantages:

- Concerns with longevity vary depending on:
 - » Case selection
 - » Amount of preparation
 - » Occlusion/parafunction
 - » Isolation when bonding

Clinical Success:

Clinical success rates of resin-bonded bridges are influenced by many variables and evidence-based information has now been gathered relating to prosthesis design, tooth preparation and length of span.

FRAMEWORK DESIGN

Factors to consider are:

1. Retainer Thickness and Configuration

It is recommended that, where possible, retainers for molars be at least 0.8mm thick or even greater if the retainer is not joined over the occlusal surface.

2. Bonding Area

Maximising the surface area for bonding the framework to enamel is one of the basic premises of good retention and resistance form for resin-bonded bridges. Sandblasting with 50µm aluminium oxide has been shown to produce a surface that is retentive enough to use luting cements, which can form chemical bonds to metal surfaces. The use of adhesive resins such as Panavia™ that chemically bonds to enamel and alloy by 4-META has helped to increase the success rate of resin-bonded bridges. Coverage involves extension of the metalwork as far occlusogingivally and circumferentially around the tooth as is possible.

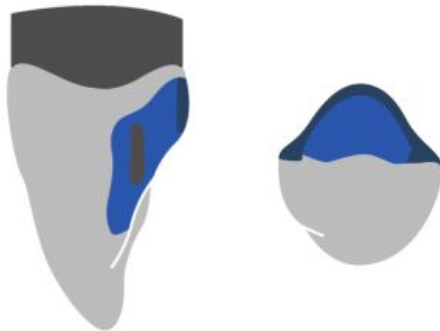
3. Wraparound

This was one of the earliest framework design features and is intended to provide buccolingual stability especially for posterior prostheses.

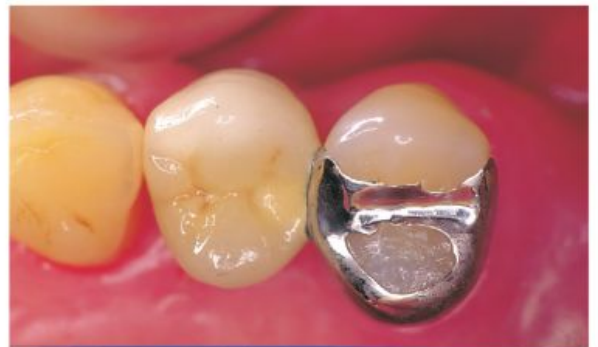4. Occlusal Extension of Metalwork

On anterior teeth, the incisal extension finishes 1.0-3.0mm short of the incisal edge to prevent metal from casting a grey shadow through the tooth or possible occlusal interferences. Posteriorly, the extension of metalwork to the occlusal surfaces of posterior abutment teeth has three important biomechanical features for prosthesis design:

- Resistance to displacement apically or laterally.
- Increased rigidity of the framework.
- Greater surface area for bonding.



Conservative groove considerations.



A direct cantilever resin-bonded bridge replacing an upper first premolar. Notice 180° wraparound and occlusal bar to increase rigidity.

Any loss of retention in the anterior teeth may be compensated for by providing conservative grooving in the enamel on the mesial and distal aspects of the abutment.

A delicate touch is required to produce this well-defined "miniature" groove. This groove should not be placed too far labially.

CONNECTOR DESIGN

Significant stresses are applied to the retainers of fixed-fixed resin-bonded bridges because of differential tooth movements between the abutments during functional and parafunctional tooth contacts. These forces stress the cement lute, which may lead to de-bonding. Such stress can be reduced by increasing the resistance form of the abutment or by changing the design from fixed-fixed to fixed-movable or to a 2-unit cantilever design.

LENGTH OF SPAN

Several studies have shown that long-span resin-bonded prostheses have a shorter clinical life. This does not mean that long-span bridges should not be provided but rather that the tooth preparation and framework design should be planned to reduce potential de-bonding stresses on the retainer. Complex interabutment stresses occur with multiple abutments. These stresses challenge the retainer framework and adhesive interface leading to premature de-bonding.

TOOTH PREPARATION:

- Axial tooth preparation not only increases the area for bonding but also increases resistance and retention form.
- Grooves allow increased resistance form to lateral displacement and may help increase retention form. They also increase the structural rigidity of the metal framework after cementation. The use of two grooves (1.0mm deep) per abutment, in comparison to no grooves, significantly increases resistance to de-bonding forces for both anterior and posterior bridges.
- Occlusal rest seats allow the transmission of occlusal forces along the long axis of the tooth but also provide resistance form and may, therefore, limit shear forces to the cement lute.
- Extension of the metal framework intracoronally into existing restorations has been advocated to achieve improved resistance form. One modification that is gaining popularity is the joining of the mesial and distal rest seats of the retainer over the occlusal surface to form an occlusal bar to improve the rigidity of the retainer. This is useful because it not only enhances the retainer's resistance to deformation but also improves the resistance form and increases the surface area for bonding.

The success and complication rates of resin-bonded bridges has been studied.

There are many factors to be considered such as (Pjetursson, B.P., et al., 2008):

- Surface area for bonding.
- Additional retention area – grooves/slots/pin holes.
- Occlusal scheme and loading (occlusally neutral is ideal).
- Bio-dynamics of the patient and presence of parafunction (a contraindication).
- Substrate to which the bridge is being bonded – i.e. presence of enamel will assist bonding.
- Material of the wings and the way the wings are treated (i.e. chemical agents e.g. silica-coating).

It is not recommended to cantilever a molar-sized pontic because the greater leverage forces from the pontic may cause uncontrolled tooth movement. Abutments requiring cuspal protection or having restorations larger than a Class II are not good candidates for such cantilevered bridges. However, in the case of a small restoration being required, this can often be incorporated into the framework design for additional resistance form.

Inlays and Onlays

There are currently three main options for intracoronal posterior aesthetic restorations, namely: direct composite, indirect composite and indirect ceramic. Of these, direct composites are, of course, the most widely used but can be technically taxing, leading to difficulties with polymerisation shrinkage, open proximal contacts (in large Class II restorations), durability and safety. Indirect ceramics undoubtedly produce excellent restorations but are expensive, extremely technique sensitive and, again, there are question marks, especially over the degree of wear shown on opposing teeth if the ceramic is finished incorrectly.

There is, however, a middle ground that offers the best of both the direct composite and indirect ceramic techniques:

- The indirect hybrid composite restoration, in particular the latest zirconium silicate materials e.g. CERAMAGE®.

The technique produces high-quality, durable restorations (Barone, A. et al., 2008) and offers the following advantages:

- Less technique sensitive.
- Significantly lower fracture rates with flexural and compressive strength > 140 MPa.
- Less wear of opposing tooth structure and excellent abrasion resistance of opposing dentition.
- Excellent marginal adaptation.
- Ease of adjustment with excellent 'polishability'.
- Cost-effective.

Importantly, indirect composites are superior to direct composites because the bulk of polymerisation shrinkage takes place outside the mouth. Consequently there is less stress at the tooth-restoration margin and as a result there is less:

- Microleakage.
- Marginal breakdown.
- Postoperative sensitivity.
- Marginal staining.

INDICATIONS

The indirect composite technique is ideally suited to inlays, onlays and, in selected cases, full crowns. It is ideal for use in premolars and first molars but care should be exercised if second molars are to be restored. Consideration should perhaps be given to a stronger alternative. As with porcelain restorations, indirect composite restorations must be bonded in place, not cemented, and it is important that the tooth is kept dry during the bonding procedure. Consequently, deep subgingival margins pose a considerable problem (Gerdolle, D.A., et al., 2005). Wherever possible, rubber dam should be used.

TRY-IN

The inlay should slide into place quite easily if the above guidelines have been followed. If not, do not panic as the likely cause is the various surface irregularities that can appear on the fitting surface following blocking out of undercuts in the laboratory. These can be removed with a carbide finishing bur. Do not check the occlusion until after the restoration has been fully bonded, as the inlay is much stronger after bonding and there is consequently less risk of damage or even fracture.

ETCHING AND BONDING

Once the fit has been assessed and corrected where necessary, the fitting surface should be cleaned, acetone being one of the most widely recommended agents for this purpose (Swift, E.J., 2002).

There is some debate as to whether the fitting surface of an indirect composite restoration should then be silanated. In theory, this would enable a chemical bond to form between the glass particles on the surface of the restoration and the luting resin. This may not, however, be so effective in hybrid-based ceramics such as CERAMAGE®. The balance of evidence currently available is that silanation should be performed (Matinlinna, J.P. and Vallittu, P.K., 2007).

The prepared tooth should also be cleaned prior to etching. Prophylaxis paste containing fluoride is contraindicated as the presence of the fluoride has been shown to compromise bond strength. Pumice and water is widely used, although some concern has been expressed about the possibility of pumice remaining within dentinal tubules, leading to reduced bond strength.

Again, acetone is increasingly being used to clean the tooth surface. The tooth enamel can then be etched (preferably under a rubber dam), at the same time avoiding etching the adjacent proximal surface since excess luting resin can bond to that surface, closing the contact as a result.

Once the tooth has been etched, a dual-cure bonding agent is then placed on the preparation, but not light cured at this stage. Equal lengths of a dual-curing luting agent are dispensed just prior to mixing. An excess of the mixture is applied to the silanated surface of the restoration, as well as a thin amount to cover most of the cavity preparation, especially in undercut areas.

Prior to seating the inlay, floss should be placed into the interproximal areas. The inlay is then seated and, with an assistant holding it in place firmly with an instrument, the floss moved in an occlusal/gingival direction, thus removing any excess luting agent at the gingival margin. The floss is then removed towards the buccal or lingual.

With the restoration still firmly seated, a fine brush can be used to remove 95% of the excess luting agent from the margins. Some operators prefer to cure the resin for a very short time, three to four seconds, and then carry out removal of excess resin as they find that the material peels away from the tooth more cleanly.

Despite the earlier warning contraindicating subgingival preparations, should these occur, the latest research suggests that use of a resin-modified glass ionomer cement leads to significantly less microleakage at the enamel margins compared to self-cure or dual-cure resin cements (Brackett, M.G., et al., 2002).

FINISHING

While the goal is to reduce the amount of finishing required to a minimum, there will always be situations where some adjustment is necessary. The use of a series of finishing grit diamonds followed by a 30-fluted carbide bur and polishing pastes will produce highly satisfactory results. Polishing under water spray has also been shown to produce a smoother surface than dry polishing (Haywood, V.B., et al., 1989).

Cementation

SELECTION OF CEMENT

Luting cements are amongst the most commonly used materials in dental practice. They have evolved rapidly in recent years in tandem with the development of ever-more-effective bonding and ceramic systems that demand so much more than traditional cements such as zinc phosphate (ZnP) can offer.

ZINC PHOSPHATE CEMENT

Long gone are the days when ZnP was the only option available to dentists for cementing crown and bridgework. Following its introduction in 1902, it reigned supreme for decades and still continues to be popular with many dentists.

Dentists believed for many years that the acidity present when mixing ZnP led to pulpal irritation. However, it has since been shown that any such irritation is more likely the result of a combination of aggressive tooth preparation and bacterial contamination occurring some time post cementation (Bra, M. and Nyborg, H., 1974). While this misconception prompted the search for more biocompatible alternatives, ZnP nevertheless remains a useful material, especially when some degree of retrievability is desirable. One such example is when cementing metal posts with good retention form, as the cement is weak enough for the bond to be broken if post removal is required (Mitchell, C.A., et al., 2000). Some practitioners also find ZnP useful for cementing long-term provisional restorations.

A succession of replacement materials appeared, starting with zinc polycarboxylate (Smith, D.C., 1968) followed by glass ionomer cement (GIC) (Wilson, A.D., 1972) through to the more recent adhesive resin and resin-modified glass ionomer (RMGI) cements.

RESIN-MODIFIED GLASS IONOMER CEMENT

This material provides most of the characteristics required for a luting cement:

- Little or no postoperative tooth sensitivity.
- Low film thickness.
- Bonds to tooth structure.
- Acceptable strength when compared with other cements.
- Coefficient of expansion and contraction similar to that of tooth structure.
- Sustained fluoride ion release.
- Relative insolubility in oral fluids.
- Ease of use (seating viscosity, post-insertion clean-up).

For many dentists, RMGI cement is the routine cement of choice for PFM, all-metal and alumina- and zirconia-based restorations. It is, however, considered unsuitable for use with leucite- and lithium disilicate-based restorations as these require a stronger underlying luting cement.

The limitations of RMGI cements are due to limited shade selection and their relative opacity under some restorations.

RESIN CEMENT

Resin cements do not adhere to tooth structure alone but can be bonded to both teeth and restorations using intermediary bonding agents.

The process options are:

Three-Step	1. Etch	2. Prime	3. Bond
Two-Step (Etch and Rinse)	1. Etch	2. Prime and bond	
Two-Step (Self-Etch Primer)	1. Etch and prime	2. Bond	
One-Step (Self-Etch Adhesive)	1. Etch, prime and bond		

There are three different categories of resin cement currently available.

RESIN PRECEDED BY SEPARATE SELF-ETCHING BONDING AGENT

(e.g. Panavia™ F and Multilink® Automix)

Advantages:

- Reduced postoperative sensitivity.
- Greater strength than RMGI.
- Adhesion to teeth and restorations.
- Adhesion to fitting surface of ceramics (other than zirconia-based) can be enhanced by sandblasting or etching with hydrofluoric acid followed by application of silane coupling agent.

Disadvantages:

- Must not contaminate tooth surface with saliva or blood.

These cements are particularly useful in the following situations:

- When the retentive features of the restoration are less than ideal (tooth preparation is too short, too tapered, or both), (Zidan, O. and Ferguson, G.C., 2003).
- When salvaging indirect restorations that have become loose during function and require enhanced retention.

RESIN WITH INCORPORATED SELF-ETCHING PRIMERS

Self-Etching Resin Cements

(e.g. RelyX™ Unicem 2 Self-Adhesive Resin Cement (3M ESPE) and Maxcem Elite™ (KERR Corp.)

Advantages:

- Almost total elimination of postoperative sensitivity (Christensen, G.J., 2009).

RESIN PRECEDED BY TOTAL-ETCH BONDING AGENT

(e.g. Calibra® (Dentsply), Nexus NX3® (KERR Corp.), RelyX™ Veneer Cement (3M ESPE), Variolink® II (Ivoclar Vivadent) and RelyX™ Ultimate Adhesive Universal Resin Cement (3M ESPE))

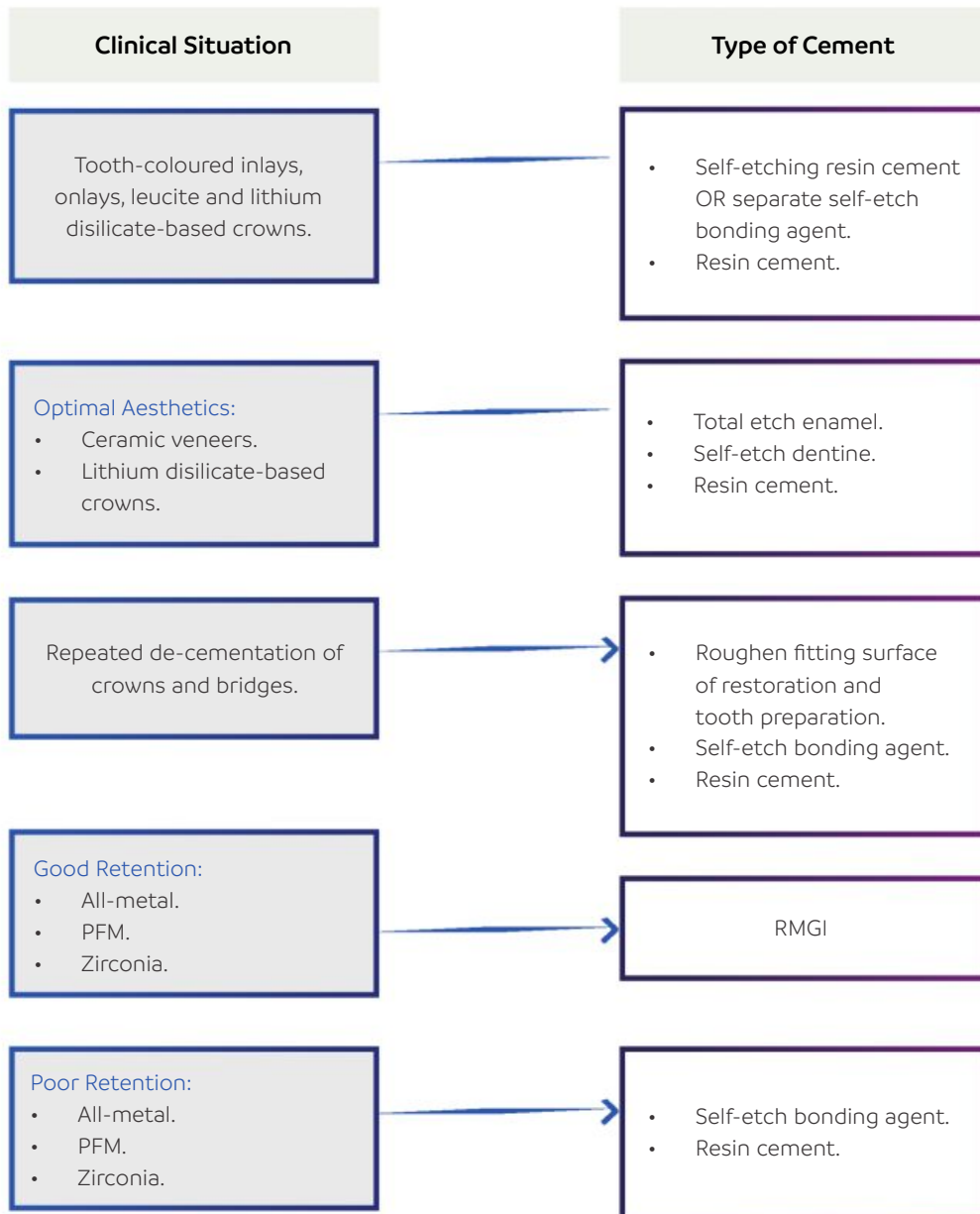
Advantages:

- Anterior restorations where shade and translucency are critical.
- For use with leucite ceramic (e.g. IPS Empress® Esthetic) and lithium disilicate ceramic (e.g. IPS e.max®).
- Strongest bonding option.

Disadvantages:

- Etching of tissue surface and application of silane bonding agent is very technique sensitive.
- Postoperative sensitivity can be a problem (due to washing away of components of smear layer released during etching process).

Choice of Resin Cement



Restoration Cementation Guide

Restoration Type and Example		Veneer		Crown/Bridge/Maryland Bridge/Metal Post		
		Lithium Disilicate e.g. IPS e.max®	Zirconia e.g. UZir Translucent Zirconia	Metal e.g. Full Gold Crown, Post & Core Porcelain-Fused-to-Metal (PFM)	Lithium Disilicate e.g. IPS e.max® Crown or Inlay/Onlay	Zirconia e.g. FMZ, PFZ, Lava™/Lava Plus™, UZir, IPS e.max® ZirPress/CAD
Adhesive Selection	Suggested type.	Adhesive resin veneer cement.		Resin-modified GIC OR adhesive resin cement (if bonding).	Self-adhesive resin cement OR adhesive resin cement.	Resin-modified GIC OR self-adhesive resin cement.
Try-In	Remove temporary. Clean tooth with pumice slurry, rinse and lightly dry.	Try-in restorations with water soluble try-in pastes or water. Check shade before teeth dehydrate. Check marginal fit. Check contact points. Check occlusion.				
Tooth Treatment Steps after Try-In	Isolate teeth and clean again if needed.	Acid etch prepared tooth with 35-37% phosphoric acid for 15-20sec/wash/dry.		Do not desiccate teeth.		
	Apply bonding agent to teeth.	Apply universal bonding agent Agitate for up to 20sec, air thin. Do not light cure unless advised by manufacturer.		N/A unless using adhesive resin cement (in which case follow veneer step here).		
Restoration Treatment Steps after Try-In	Clean fitting surface of restoration.	Use Ivoclean® for 20sec OR 37% phosphoric acid etch for 15sec. Rinse and dry.	Sandblast OR apply Ivoclean® for 20sec. Rinse and dry. Do not etch.	Sandblast. Rinse and dry. Do not etch.	Use Ivoclean® for 20sec OR 37% phosphoric acid etch for 15sec. Rinse and dry.	Sandblast OR apply Ivoclean® for 20sec. Rinse and dry. Do not etch.
	Treat restoration fitting surface to enable bonding.	If not yet HF etched, apply 5% HF for 20sec (IPS e.max®), rinse and dry. Apply silane and allow to dry.	Apply primer containing MDP and allow to dry.	N/A	If not yet HF etched, apply 5% HF for 20sec (IPS e.max®), rinse and dry. Apply silane and allow to dry.	N/A if using RMGI. If using self-adhesive resin cement, apply primer containing MDP (optional and dependent on chemistry of adhesive).
	Apply adhesive.	Apply universal bonding agent (if advised by manufacturer).		Only if bonding: Apply universal bonding agent.	N/A	N/A
Cementation	Mix and apply chemical-cure cement components if required.	N/A as light curing only (except where opaque ingots used to mask underlying discoloured tooth structure).		Only if bonding: Mix and apply primers as per manufacturer's instructions (if required for adhesive system).	N/A unless using adhesive resin cement, in which case follow step for metal bonding.	N/A unless using adhesive resin cement, in which case follow step for metal bonding.
	Mix and apply cement to restoration. Seat carefully. Remove gross excess. Finish margins and adjust occlusion.	Do not apply cement to teeth. Tack cure margins for 1-2sec with curing light. Remove excess, light cure all margins for 20-30sec per margin and restoration for 30-50sec per surface.		Allow cement to chemically cure (up to 6min depending on cement). Only if bonding: Light cure all margins for 20-30sec.	Tack cure margins for 1-2sec with curing light. Remove excess, light cure all margins for 20-30sec per margin and 30-50sec per surface. Wait up to 6min for chemical curing (or as advised by manufacturer) before finishing.	For RMGI, remove excess when at gel stage. Allow to set for 4min or as advised by manufacturer, then finish margins. For other cements follow steps for lithium disilicate.

Strategies for Preventing Tooth Sensitivity

A number of different strategies have been proposed to counter postoperative sensitivity, all aiming to prevent irritating chemicals from the luting cement penetrating into the open dentinal tubules:

- Place and cure the bonding agent immediately prior to cementation with resin cement. The major difficulty with this approach is the thickness of the bonding agent layer, which could subsequently affect the full seating of the crown.
- Place and cure the bonding agent immediately after tooth preparation and prior to taking the impression or scan. This approach is effective (Magne, P., 2005) and has the added advantage that dentine-bonding agents create the highest bond strength when applied to freshly cut dentine (Paul, S.J. and Schärer, P., 1997).
- Implement a two- or three-step total etch system with light curing. This is the most widely recommended approach. It must be carried out before saliva contaminates the prepared tooth. The light curing polymerisation must be done in two stages to prevent the bonding agent's oxygen-inhibiting layer interacting with the impression material (Magne, P., 2005). When fabricating the temporary resin restoration the tooth surface should first be covered with a thick layer of petroleum jelly to prevent the resin bonding to the tooth (Magne, P., 2005). Resin-based temporary cements should also be avoided.
- A desensitiser agent (eg. Gluma® Desensitizer (Heraeus Kulzer GmbH) be placed prior to the primer and bond being placed and cured. This technique is only suitable for thin translucent veneers or shallow inlays to allow transmission of the curing light through the restoration.
- Use self-etching primer and bond, which appears to be the most successful approach.
- For those preparations involving exposed enamel and dentine (typically veneers):
 - » Selectively etch the enamel with well-controlled viscous phosphoric acid gel
 - » Wash the gel from the tooth with copious water spray
 - » Place self-etching primer and bonding agent on the entire preparation, including the just-etched enamel.

Chairside Finishing and Polishing

It is widely accepted that the best surface for porcelain is a high gloss glaze finish. However, it is not uncommon for PFM, PFZ and all-porcelain restorations to require adjustments to the ceramic prior to cementation. Ideally, adjusted surfaces should be reglazed prior to cementation for optimum longevity and smoothness.

POLISHED SURFACES

There have been many studies comparing the surface of ceramic restorations that have been adjusted chairside, then either reglazed or polished with current polishing systems. The findings have varied widely, with the most practical approach being the use of one of the specifically designed chairside polishing systems to return the ceramic surface to a clinically acceptable level of smoothness. The polishing process removes scratches and defects to obtain a more homogenous, smooth and light-reflective lustrous surface.

CERAMIC FINISHING AND POLISHING PRODUCTS

System	Product	Description
Shofu	CeraMaster. Super-Snap buff disc. Ultra II Diamond polishing paste.	Range of bullet, knife, cup, mini-points and wheels using a blend of silicone and diamond particles. Ultra II Diamond Polishing Paste, which comprises ultra-fine diamond particles, used with Super-Snap buff disc to create final polish.
Ivoclar Vivadent	OptraFine®.	Suits all-ceramic restorations made of IPS Empress® CAD and IPS e.max® CAD or IPS InLine® metal-ceramics.
VH Technologies	DiaShine® polish. VH intraoral brush range.	Range of diamond grit polishes for use with soft brushes for final polish of ceramics.

08

IMPLANTS




Overview

Every day at Modern Dental Pacific, we encounter at least one case where implants have been placed in what can only be described as “restoratively-challenging” positions. These implants create technical challenges for our team as we work with the dentist to resolve what might otherwise be potentially catastrophic problems. In this chapter we discuss how to achieve successful implant restorations that are well placed, functional and look great.

Successful implants are the result of careful planning and execution. To ensure an optimal outcome, it can be helpful to work through part of the process backwards. Before you start, ask yourself these questions: “What must this restoration look like?”, “What does the desired look mean for where my implant must be placed?” and “How does the placement dictate the method by which the restoration attaches to the implant?”. Once you can answer these questions, you will have an invaluable insight into how a case must be approached.

Working through the process this way also means that you are not trying to work it out as you go. Instead, you can plan to achieve predictable results right from the outset.

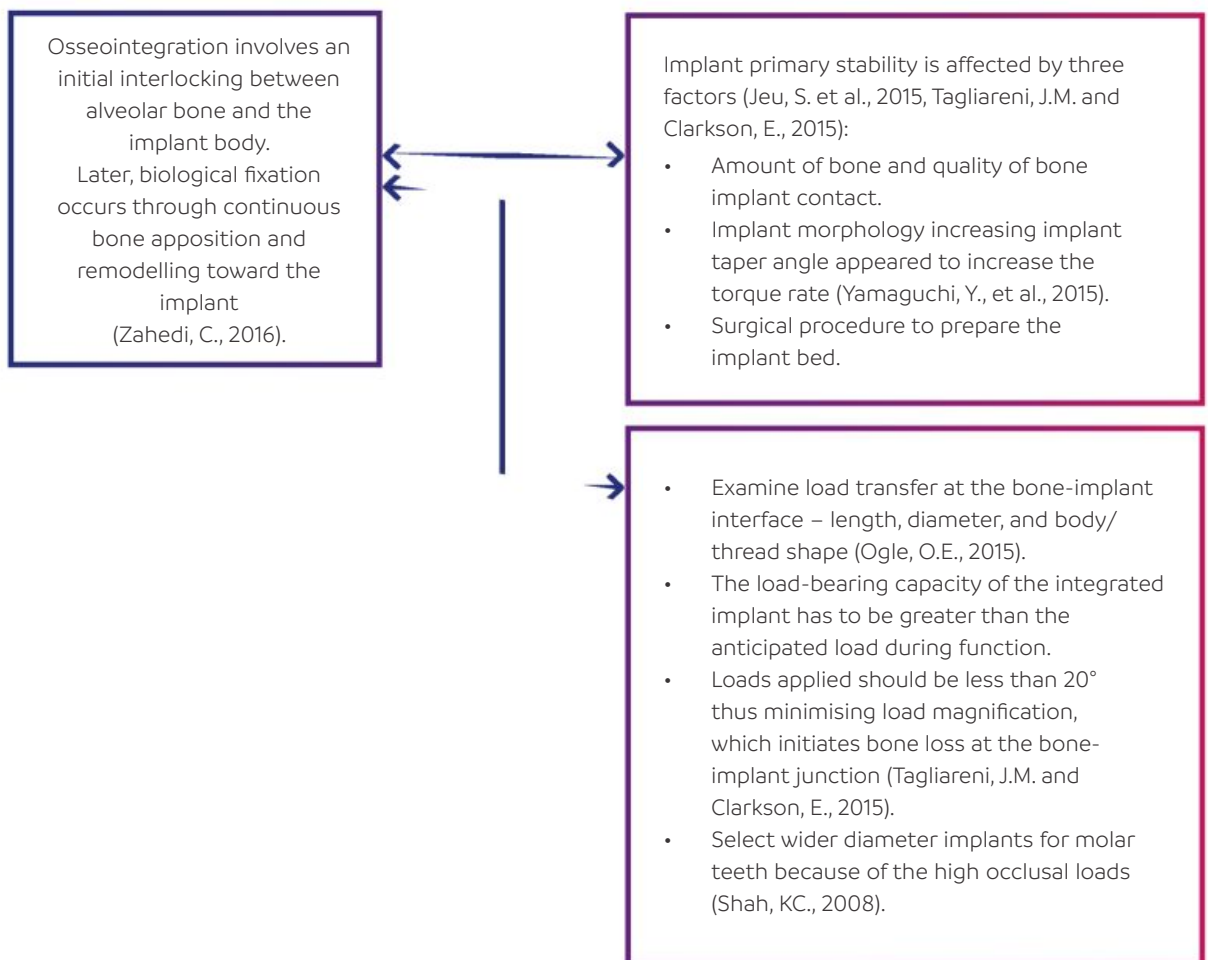
In this chapter we share with you our thoughts on successful implants. We hope you’ll integrate this knowledge into your clinical practice, as it is sure to save you time and money.



IMPLANTS

Treatment Planning for Implants

A. BIOLOGICAL CONSIDERATIONS



B. TREATMENT WORK-UP

Generation of CAD designs of full-arch implant-supported bridges are based on diagnostic wax-ups, which allow proper design for strength and retention (Thalji, G. et al., 2014).

Adopt a "crown-down" approach (Fugazotto, P.A., 2009).

Implant spacing: (Shah, K.C. and Lum, M.G., 2008):

- Implant should be at least 1.5mm away from the adjacent teeth.
- Implant should be at least 3.0mm away from an adjacent implant.
- Consider sequential aligner therapy.

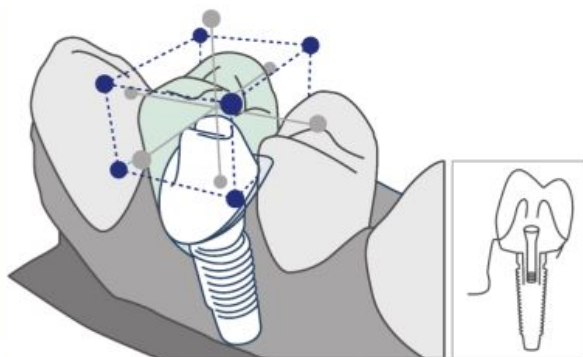
Ensure information regarding implant size and manufacturer is communicated between surgeon and restorative team.

Procure prosthetic components required (Christman, A. et al., 2014).

C. DESIGN PARAMETERS

Confirm:

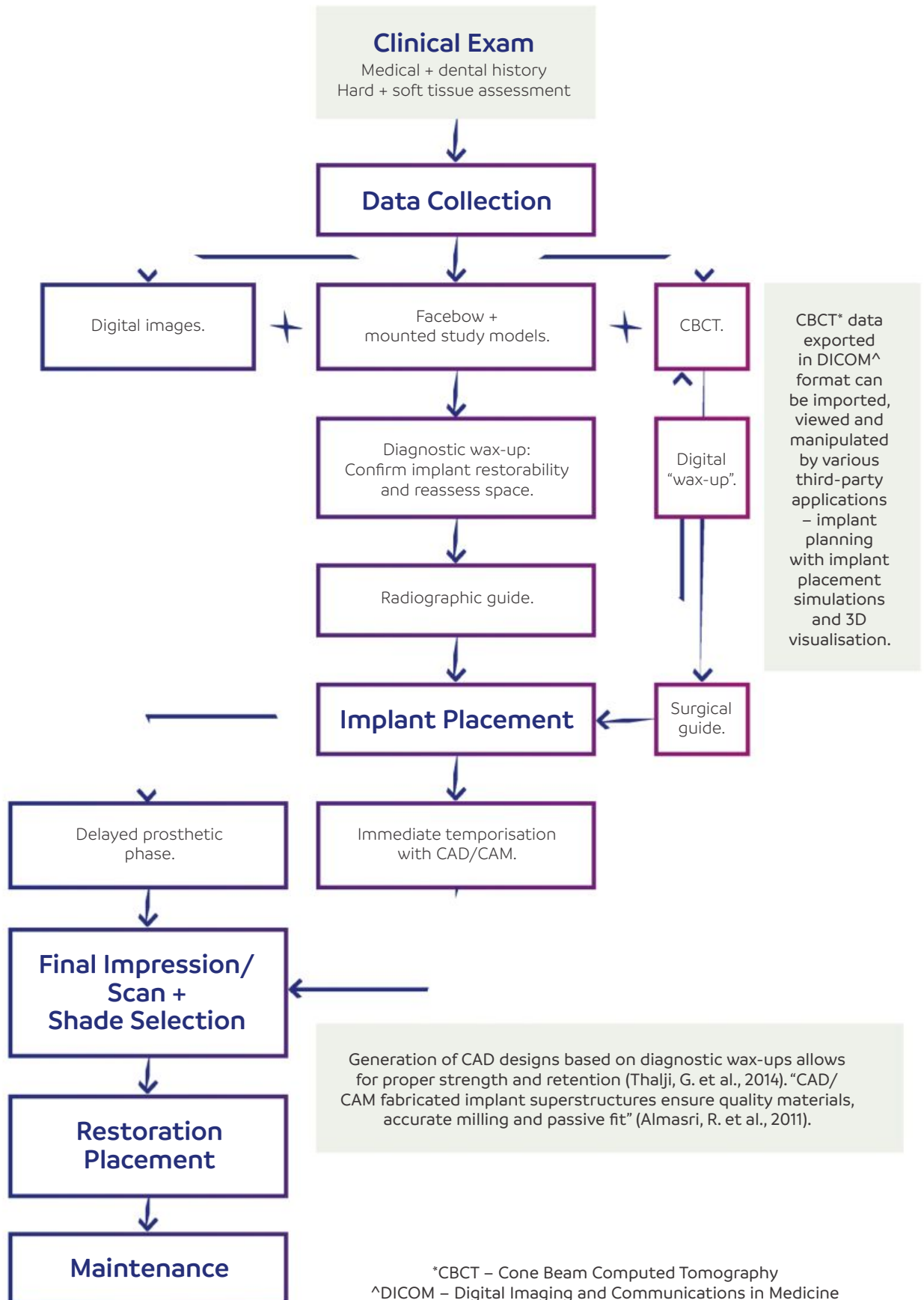
- Screw-retained?
- Cement-retained?



Allow adequate clearance under the metal superstructure for patient hygiene (Lin, W.S. et al., 2014).

Treatment Planning for Implants

(Boyce, R.A and Klemons, G., 2015)



Implant Treatment Planning and Imaging

RESTORATIVELY DRIVEN IMPLANT DENTISTRY

Diagnostic phase often begins before scan is taken (Ganz, S.D., 2015).

The planned position and form of the proposed prosthesis must be defined by the diagnostic wax-up process and/or denture tooth arrangement for:

- Single tooth.
- Multiple teeth (e.g. Implant-supported bridges).
- Full arch reconstructions.

Treatment planning by virtual 3D implant placement is based on both anatomic and prosthetic considerations and criteria (Vasak, C., et al., 2014). Inclusion of volumetric imaging in this process is the only way to fully evaluate the implant position in all three dimensions. However, without inclusion of the planned tooth or prosthesis position in this 3D image, such planning is not possible. Central to computer-aided implant planning is the use of radiographic stents that present the planned tooth or prosthesis position within the radiographic image.

Stent Options:

1. Use an existing prosthesis containing radiopaque markers (simple, direct, economical).
2. Thermoplastic template incorporating radiopaque markers.
3. Radiopaque teeth in a mucosa- or tooth-supported stent.
4. Radiopaque resin duplicate of a prosthesis or a diagnostic wax-up.

Note: Options 2-4 require initial study casts mounted on an articulator.

Ideal features of a radiographic stent:

- Radiopaque indicator of correct tooth form and position without inducing scatter.
- Retentive and stable intraorally.
- Comfortable.
- Able to be decontaminated if used as a surgical guide.
- Compatible with scanner (hardware) platform.

Computer-aided implant planning and implant placement have been developed to facilitate more efficient preoperative assessment of bone volume, safe implant placement and a successful implant restorative outcome.

CBCT:

- Allows "planar imaging" (Angelopoulos, C. and Aghaloo, T., 2011).
- Provides 3D image of osseous area of interest, constructed and viewed in multiple planes (axial, coronal, sagittal).
- Evaluates bone density, which is directly proportional to load-bearing capacity.

GUIDELINES FOR USE OF CBCT IMAGING FOR DENTAL IMPLANT TREATMENT PLANNING:

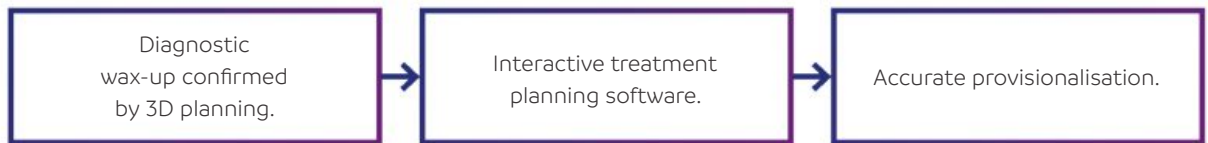
(American Dental Association Council on Scientific Affairs, 2012)

- Evaluate morphology of residual ridge.
- Determine orientation of alveolar ridge.
- Identify anatomy that may limit implant fixture position.
- Match imaging findings to restorative plan.
- Consider when preoperative cross-sectional imaging is deemed necessary.
- Desired when hard tissue grafting is required.
- Evaluate hard tissues after augmentation.

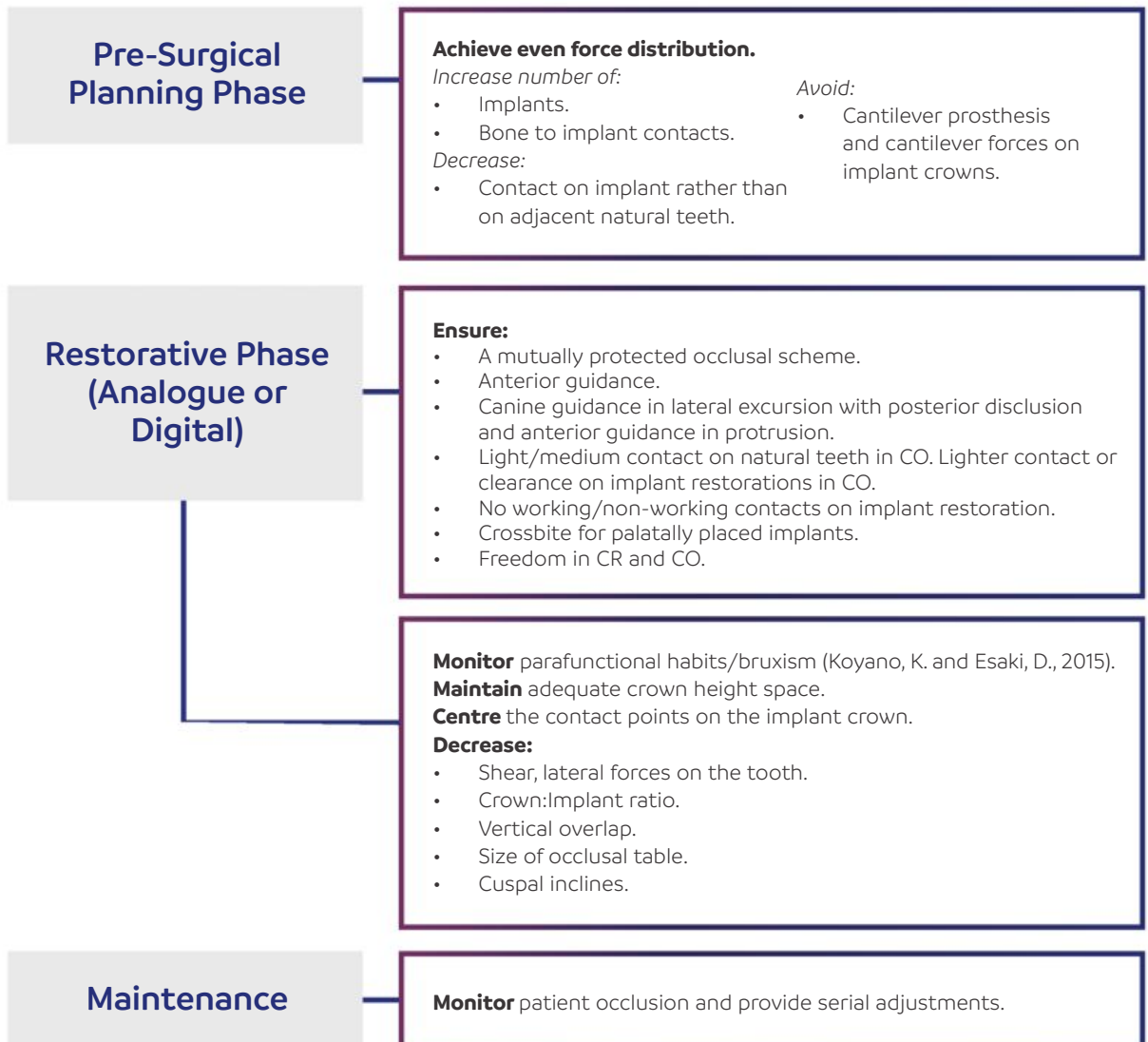
Any CBCT scan intended to aid in the planning, placement and restoration of dental implants must include a scan prosthesis or integrate an optical scan of a diagnostically waxed cast. DICOM data from the CBCT is exported into a third-party treatment planning software application with the functionality to simulate implant placement. The software should also have the ability to export the data for the fabrication of surgical guides, which offer 3D control of implant placement. Whenever multiple implants and their precise interimplant orientation are required for prosthesis success, the use of a 3D model-derived CAD/CAM generated surgical guide may be used to clinical advantage.

General Features of Implant Planning Software Include:

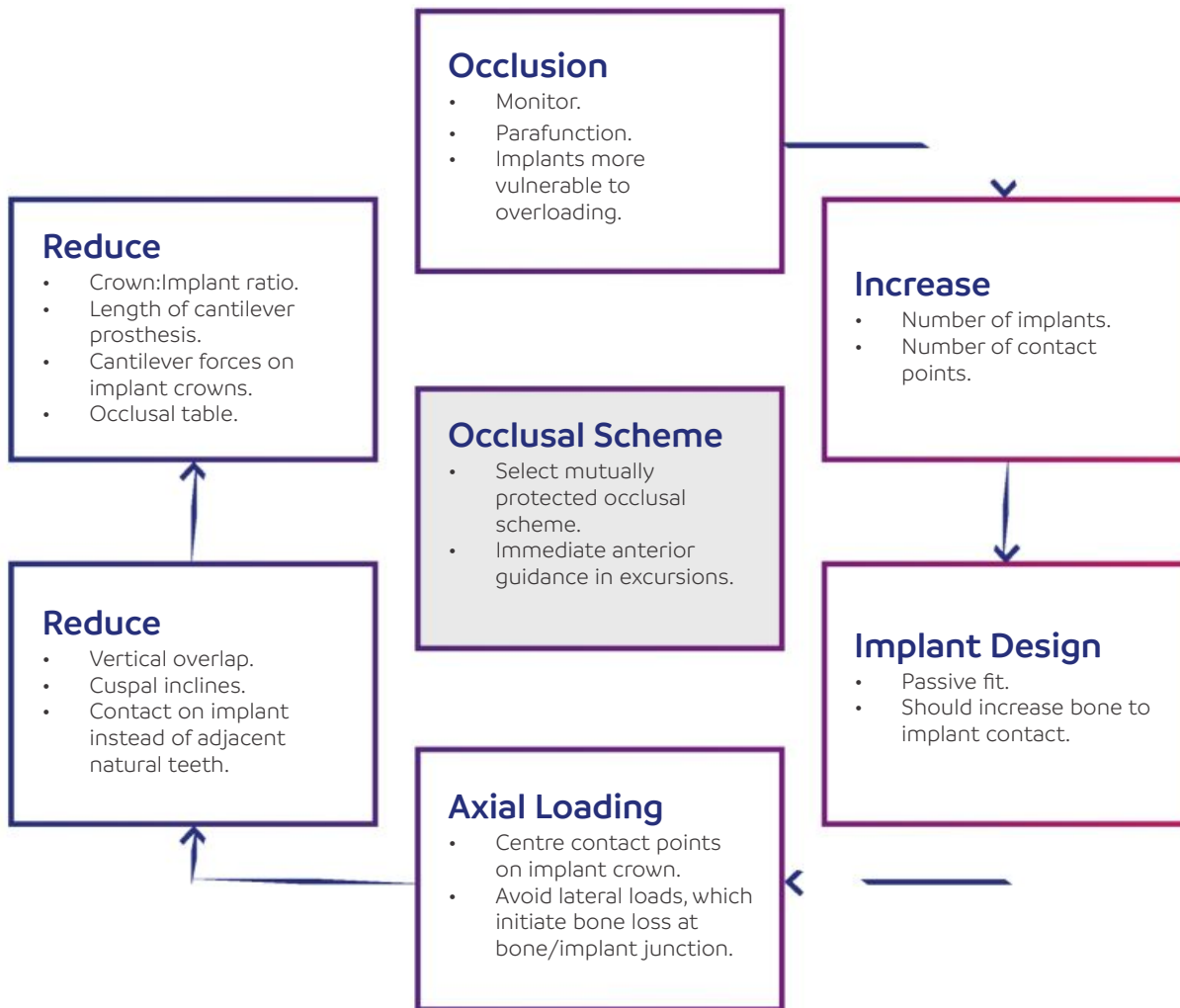
- Acquire DICOM data and then generate a 3D model.
- Filter and segment 3D data in preparing a cleaned model for evaluation.
- Identify or segment areas of the maxilla and the mandible, or regions of interest.
- Visualise 3D data-generated images of soft tissues, bone, teeth, and the scan prosthesis.
- Superimpose dual-scanned or optically scanned data representing the scan prosthesis or diagnostic cast.
- Virtually place 3D implant and abutment models within regions of interest.



Occlusal schemes for single implants and bridges supported by implants (Sadowsky, S.J. and Zitzmann, N.U., 2016, Gross MD., 2007).



Implant Occlusion Recommendations



The above chart was based on the findings of Sadowsky, S.J. and Zitzmann, N.U., 2016, Gross MD., 2007, Isidor F., 2006, Mericske-Stern R. et al., 1992, Koyano, K. and Esaki, D., 2015.

ACHIEVING SUCCESSFUL OUTCOMES – WHAT TO CONSIDER

A. Aesthetics:

- Use smile analysis to achieve the most aesthetic result.
- Evaluate the pink, white and black components of the smile:
 - » *Pink* aesthetics relates to the examination of the shape of the gingival tissues around the gingival margins and edentulous spaces
 - » *White* aesthetics relates to the study of the tooth morphology, position and axial inclination of the clinical crowns within the arch of the aesthetic zone
 - » *Black* aesthetics relates to the embrasure spaces around teeth which aid in the framing of the aesthetic zone and express the complete tooth shape
- Cooper (Cooper, L.F., 2008) has stated that “dental implant placement can be guided by the location of the gingival zenith”. The gingival zenith is the soft tissue reference point.
- “Zenith-directed planning” is achieved using study casts and diagnostic wax-ups.
- The proposed crown contour can be included in the CBCT image by use of a radiographic template. The final surgical guide will incorporate the location of the gingival zenith.

What Affects the Gingival Zenith?

Relative Tissue Locations	<ul style="list-style-type: none"> • The planned gingival zenith should be symmetrical with the contralateral tooth and be in balance with the gingival levels of adjacent teeth. • Interproximal tissue contours of the papillae are supported by adjacent teeth connective tissue contacts.
Depth of Implant Placement	<ul style="list-style-type: none"> • A biologic width forms at the dental implant (Hermann, J.S., et al., 2000). • The buccal dimension of the biologic width created at the abutment is about 3.0mm (Kan, J.Y., et al., 2003). • The “three/two” rule describes the relationship in space of the implant/abutment interface to the gingival zenith and should be: <ul style="list-style-type: none"> » 3.0mm apically displaced from the zenith » 2.0mm palatally displaced from the zenith
Peri-Implant Mucosal Design	<ul style="list-style-type: none"> • Predictable aesthetic success is possible if the dentist assesses the connective tissue attachment at the adjacent teeth. • Interproximal papillae depend on adjacent tooth contours. • Tooth form is largely defined by the peri-implant soft tissues.
Prosthetic Management of Peri-Implant Design	<ul style="list-style-type: none"> • Provisionalisation of both temporary crowns and abutments enables the clinician to assess the tissue response and subsequently refine the definitive restoration. • An abutment can be placed to allow formation of biologic width, which will allow proper shaping of the peri-implant tissues. • The abutment will be concave except for a convexity on the buccal.

B. Restorative Space:

Single-Tooth Screw-Retained Restoration	<ul style="list-style-type: none"> • Crown can be screwed directly to the implant with 6.0mm of space needed from the restorative platform of the implant to the occlusal plane.
Single Cement-Retained Crown	<ul style="list-style-type: none"> • Needs about 8.0mm of space to accommodate the abutment and the prosthesis. An extra 2.0mm of distance from the implant/abutment interface is needed to allow formation of the biologic width of the abutment.
Bar-Retained Restorations	<ul style="list-style-type: none"> • May require as much as 16.0-18.0mm space from the implant/abutment interface to the planned occlusal table so there is enough room for the abutment, bar, acrylic and teeth. • Transmucosal dimension (biologic width) of about 2.0mm. • Supramucosal abutment height (0.0-2.0mm) to allow hygiene. • Framework height 3.0-5.0mm. • Acrylic veneer thickness of more than 2.0mm.

Simple Single-Tooth Implants

“Rules of Six”:

(Cooper, L.F. and Pin-Harry, O.C., 2013)

- 6.0mm of inter-radicular space.
- 6.0mm of buccolingual osseous dimension.
- 6.0mm of minimum implant length.
- 6.0mm of interocclusal distance for prosthetic and component requirements.
- Less than 6.0mm distance from the bone crest to the interproximal contact point for papillary formation.
- “Three/two” rule – zenith planning (see above).

Implant-Retained Overdentures or Implant-Supported Fixed Prosthesis

“Rules of 10”:

- The inferior/superior dimension of the mandible must be 10.0mm or more.
- The interocclusal (restorative) dimension measured from the ridge crest to the occlusal plane must be 10.0mm or more. When planning for implant placement, know the planned position of the prosthetic teeth. Plan DOWN from the occlusal plane and not UP from the osseous crest.
- The anterior/posterior distribution of implants must be at least 10.0mm. The aim is to have the distal implant in the distal-most location not impose on the inferior dental nerve.

C. Positioning of the Implant

The position of an implant can greatly influence the achievement of a successful aesthetic, biological and functional outcome. Pre-surgical planning of the position of the desired restoration (“crown-down approach”) allows for planning of ideal implant positioning. However, anatomical and surgical factors may prevent ideal placement.

Where an implant is placed by a different clinician from the restorative dentist, or sufficient forethought has not been given to the requirements of the final restoration, the restorative dentist may be presented with unforeseen restorative challenges. These are best managed with multidisciplinary decision making, including consultation with the technical team.

RISK FACTORS INFLUENCING SUCCESSFUL TREATMENT OUTCOMES

(Weber, H.P., et al., 2008)

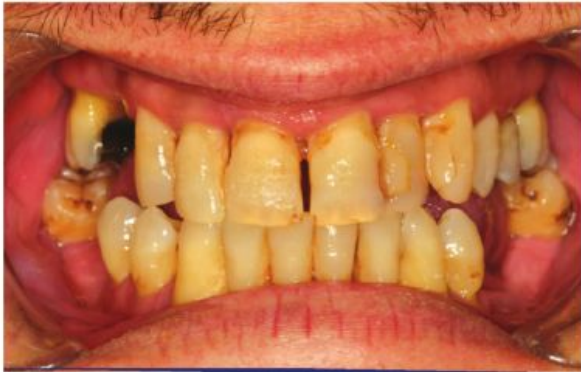Health Status Contraindications to Implants

Temporary	Systematic		Local
	Absolute	Relative	
<ul style="list-style-type: none"> • Transient infection. • Systemic therapy: <ul style="list-style-type: none"> » Anticoagulant treatment » Immuno-suppressive drugs » Corticosteroids » Chemotherapy 	<ul style="list-style-type: none"> • Radiotherapy – high dose. • Disordered bone metabolism. • Systemic disease – renal, liver, thyroid, pituitary, and vascular. 	<ul style="list-style-type: none"> • Radiotherapy – low dose. • Osteoporosis. • Rheumatoid arthritis. • Anticoagulant treatment. • Drug/alcohol abuse. 	<ul style="list-style-type: none"> • Unresolved bone loss (e.g. osteomyelitis). • Inadequate hygiene. • Periodontitis (local + generalised). • Soft tissue + mucosal abnormalities (e.g. pathology/insufficient tissue). • Adjacent tooth issues (e.g. root proximity).

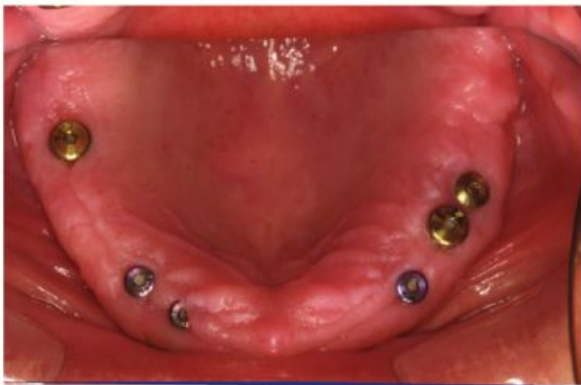Factor	Low Risk	Medium Risk	High Risk
Patient Expectations	Low	Medium	High
Wound Healing	Normal wound healing		Impaired wound healing
Smoking	Non-smoker	< 10 cigarettes/day	> 10 cigarettes/day
Periodontitis Disease Susceptibility	Low, gingivitis only	Mild to moderate disease	Severe periodontitis
Bruxism	No		Yes
Aesthetic Demand	Low	Medium	High
Smile Line	Low	Level	High
Lip Line	Low	Medium	High
Gingival Biotype	Flat scalloped Thick	Medium scalloped Medium thick	High scalloped Thin
Keratinised Mucosa	Adequate band		Thin or keratinised
Soft Tissue Anatomy	Intact soft tissues		Soft tissue defect
Bone Deficiency	No deficiency	Horizontal deficiency	Vertical deficiency
Shape of Tooth	Rectangular, long contact points		Triangular, short contact points
Bone Level to Adjacent Teeth	≤ 5.0mm to contact point	5.5-6.5mm to contact point	≥ 7.0mm to contact point
Width of Edentulous Space	≥ 7.0mm (regular implant) ≥ 6.0mm (narrow implant)	< 7.0mm (regular implant) < 6.0mm (narrow implant)	Two teeth and more
Bone Anatomy of Alveolar Crest	Alveolar crest without bone deficiency	Horizontal bone deficiency	Vertical bone deficiency

Treatment Planning Involves a Thorough Understanding of Mechanical Principles Involved in Implant Dentistry

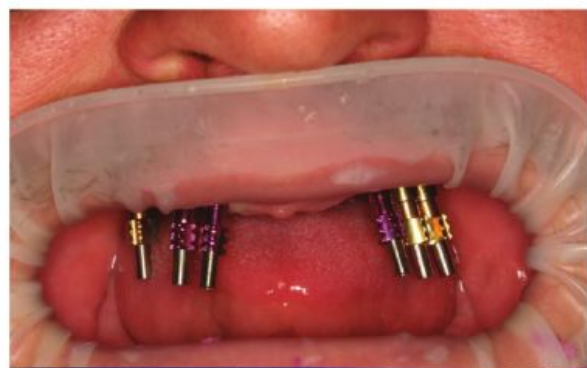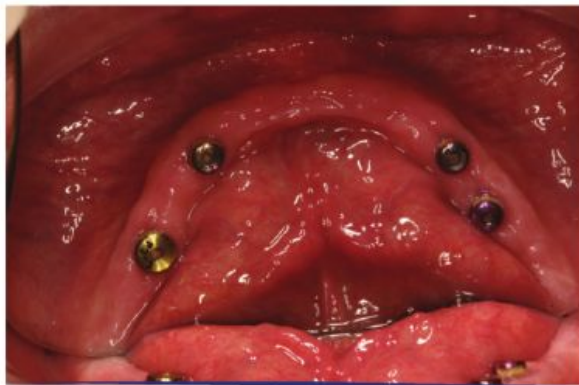The case below illustrates upper and lower fixed implant-supported telescopic prostheses with custom-milled abutments (Baker, B.H., 2014). The aim was to restore 16-26 on the maxilla and 36-46 on the mandible.



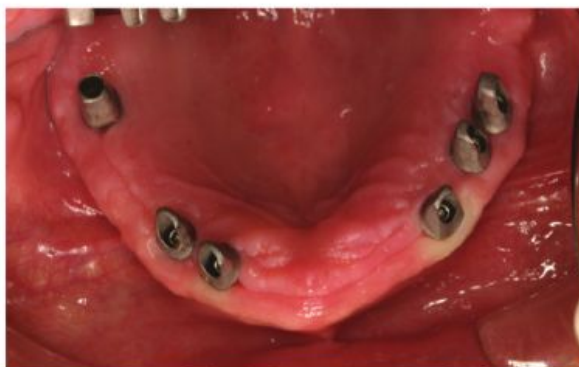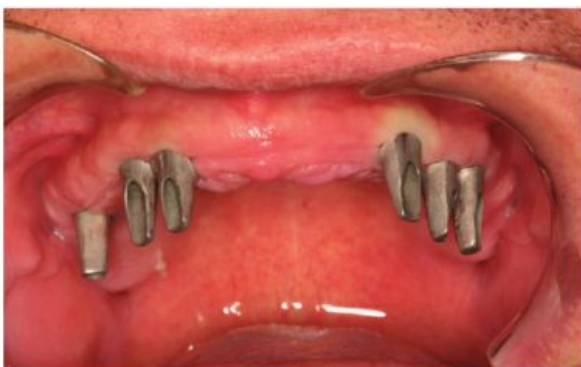This preoperative view illustrated the destructive periodontitis evident with significant attachment loss and associated loss of support.



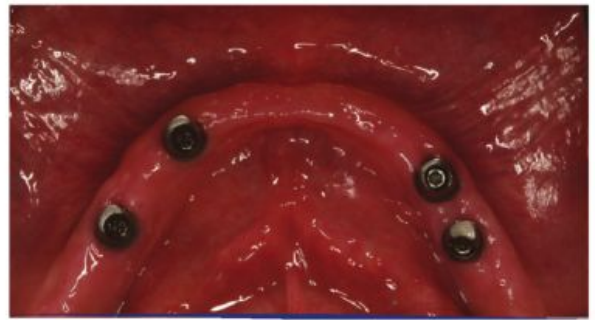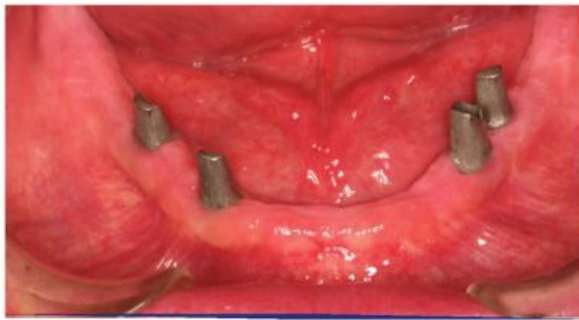Upper and lower healing caps are illustrated in situ.



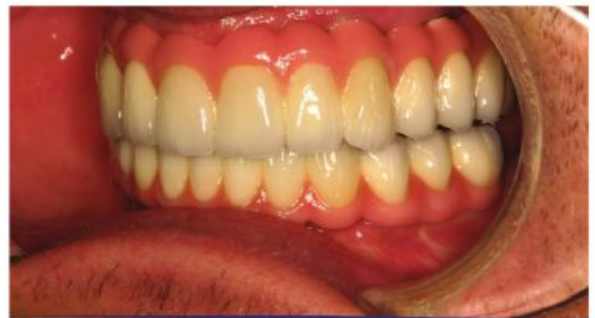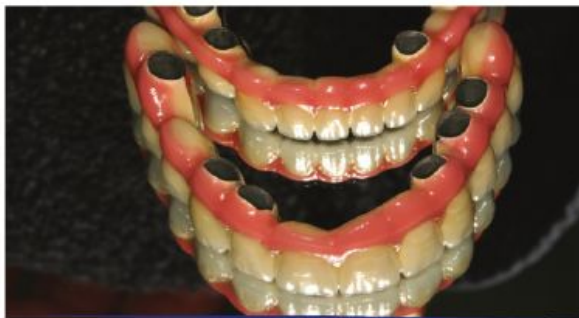The position and angulation of the impression copings is indicated.



Maxillary abutments in situ from a buccal and occlusal perspective.



Mandibular abutments in situ from a buccal and occlusal perspective.



The completed implant-supported prostheses were shown to the patient prior to insertion.

The final restorations were placed.

Impressions for Implants

MATERIAL CHOICE

Polyether and PVS are the recommended materials for implant impressions. Putty and light-body combination PVS impression materials have been shown to be more accurate than medium-body polyether impression material when the implant was placed deeply subgingival.

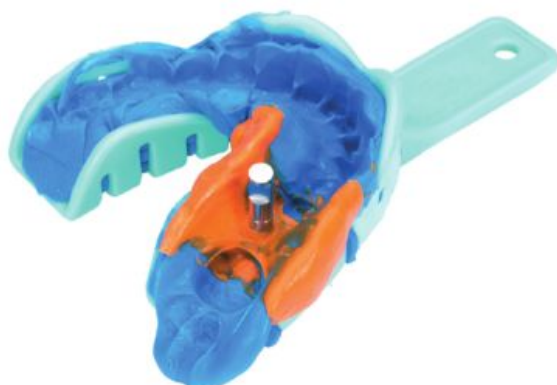Preliminary Impressions

Are for study models, surgical and radiographic stents or for fabrication of custom final impression trays, which should be taken and poured up in dental stone.

Custom Final Impressions

Can be taken of either the implant body itself or of the abutment attached to the implant. This choice depends on the type of prosthesis being made: crown, bridge, metal bar or overdenture.

Metal analogues must be used in the impression when pouring up the model.



One-Stage Procedure

The healing abutment is already present. It is unscrewed and the impression coping is placed and the impression taken.

OR

Two-Stage Procedure

Typically, at implant exposure, the cover screw will have been removed and a sulcus former (healing abutment) attached. The same provisional restoration is used with minor modifications to adapt to the presence of the sulcus former.

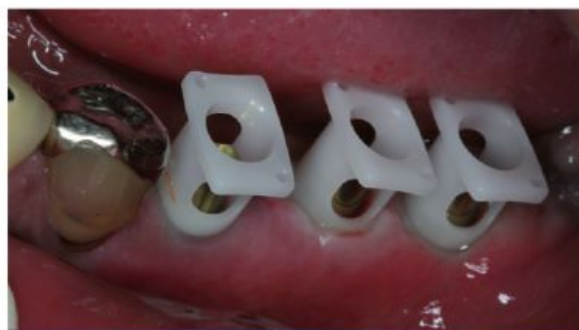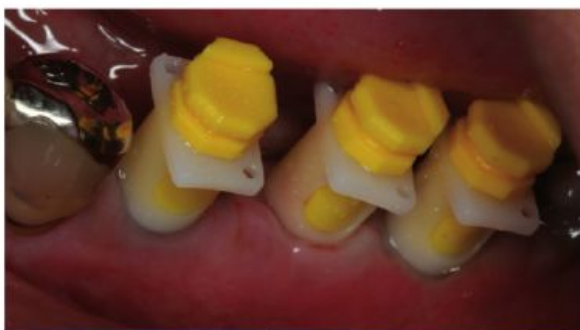TWO TECHNIQUES FOR CUSTOM FINAL IMPRESSIONS FOR IMPLANTS

Open Tray:

- **More accurate and recommended for all implants.**
- Use if the impression is taken over multiple (more than three) implants or if the implants diverge from each other by more than 15°.
- The impression coping is retained in the impression during its removal from the mouth.
- The impression coping consists of two parts: the coping itself; and the impression coping screw, which holds the coping onto the underlying abutment or implant.
- Use an impression tray that has access to the screw attaching the transfer device to the implant.
- Syringe impression material around the transfer device prior to the loaded tray being seated.
- Once the impression material is set, the fixation screw is detached from the implant, enabling the impression to be removed with the transfer device embedded within it.
- The implant replica can then be attached prior to pouring the impression.

Closed Tray:

- Suitable for impression taking over implants which are within 15° of each other.
- Ideal when there is limited opening and occlusal height as it avoids the need for impression copings with associated guide pins to be inserted.
- Torque solid abutments to the fixtures into their final position and add transfer copings directly onto the abutments.



- These copings then remain in the impression, and laboratory analogues are then attached chairside or in the laboratory.
- Closed tray impression copings are completely torqued onto the fixtures in their final position and a standard crown and bridge impression is taken.
- The impression is removed, the copings unscrewed and then carefully repositioned inside the impression.
- If resistance is met, the likelihood is that the angulation or position of replacement is incorrect and should not be forced.
- Laboratory analogues can be added chairside or in the laboratory.

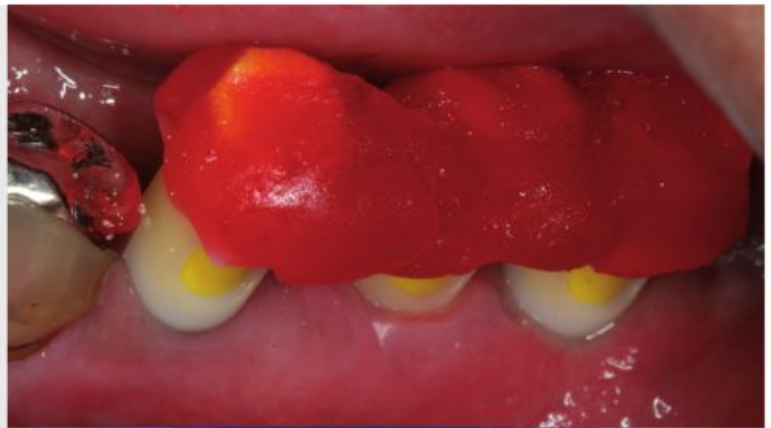SPLINTING

The abutment level or implant level internal connection implants have greater accuracy with splinting than with non-splinting. Acrylic resin is the material most commonly used for this purpose. In order to minimise resin polymerisation contraction, the resin scaffold should be prepared one day prior and the final connection should be performed just before the impression procedure.

Roughening the external surface of the pick-up impression copings, and applying an adhesive coating to it, is routinely chosen when an immediate loading multiple implant impression has to be made. In these cases, intraorally splinting the impression copings with acrylic resin is not the preferred option.

Straumann® Solid 4.0mm abutments were torqued to 35Ncm, basket and transfer copings are attached and secured with DuraLay™ resin to avoid movement during laboratory analogue attachment.*

**Straumann (Institut Straumann AG)*



Impression Taking

Prosthodontic Management of Implant Therapy

A. FIXED PROSTHESIS**Use of Screw-Retained or Cement-Retained Prostheses**

Cement-retained restorations may offer aesthetic advantages when access holes are visible facially and occlusally. An implant-supported bridge will have a more passive fit with a cement-retained restoration (Karl, M., et al., 2006). Elements important for the retention of the cement-retained restorations are essentially the same as those for natural teeth, including taper of axial walls, surface area, height of the abutment, roughness of the surface, and type of cement (Emms, M., et al., 2007). Cement-retained restorations require adequate interarch space to allow fabrication of an abutment with 3.0-4.0mm axial walls (Sadig, W.M. and Al Harbi, M.W., 2007). Most abutments are manufactured to approximately a 6° taper, which has been considered optimal for crown preparation (Enkling, N., et al., 2013). The minimum abutment height for use of cement-retained restorations with predictable retention was documented as 5.0mm. Excess cement was associated with signs of peri-implant disease (Burbano, M., et al., 2015). Cemented restorations are designed with prosthesis-abutment interface no more than 2.0-3.0mm subgingivally so that excess cement may be readily removed.

Screw-retained restorations or custom abutments for cement restorations with higher margins may be used to avoid cement-related complications in situations where implants are deeply placed. If possible, long-span and full-arch bridges as well as riskier cantilever bridges may be best treated with screw-retained options (Chaar, M.S., et al., 2011).

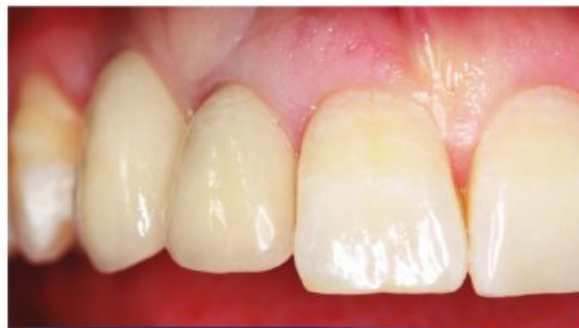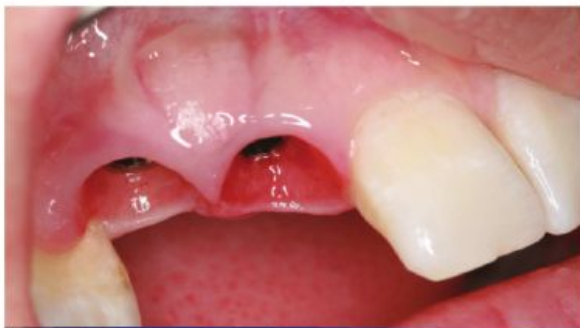Cement-Retained vs Screw-Retained Restorative Considerations

Feature	Cement-Retained	Screw-Retained
Retrievable	Not easily, may need repair	Yes
Evaluate Underlying Implant	No	Yes
Aesthetics	Superior	May be inferior (depending on screw hole location)
Ability to Correct Misaligned Implant	Yes	Sometimes
Vertical Loading	Yes	Less/no
Insertion	Easy	Challenging posteriorly
Retention at Minimal Occlusal Height	Marginal	Superior
Passive Fit	Yes	No
Maintenance	Medium	Low

Screw-Retained Restorations

With screw-retained restorations, if the implant is misaligned, the screw access hole may be in various positions. Posteriorly, the screw access hole may eliminate considerable occlusal anatomy. When the retaining screw has been tightened, the access hole is filled with a resin, which wears, stains and may need replacement. The screw access hole can occupy at least 5-10% or more of the occlusal surface of a posterior tooth.

A screw access hole on an anterior implant-supported prosthesis may mean that the alignment of the implant is such that the screw access is to be placed buccally or near the incisal edge. Access holes may be filled with tooth-coloured resin in the provisional restoration but the final restoration would require a cement-retained prosthesis. Screw retention requires great vigilance as the small retaining screw can be lost in or outside the mouth. Drivers used to tighten the retaining screws can be difficult to align posteriorly. The stability of the implant/abutment connection is crucial to long-term success. The finish on screws affects the tension induced by a certain torque. Screws with enhanced surfaces lowered the coefficient of friction. There are cross screws that can loosen, being smaller than the abutment-to-implant screws and typically placed with lower torque (10Ncm versus up to 32Ncm) depending on the abutment material and the system.



Implants with PFM screw-retained crowns.

Cement-Retained Restorations

The lack of screw holes in cemented prostheses enhances the physical strength of porcelain and acrylic resin so less fracture occurs. The occlusal surface has no screw holes and so axial loading is achieved. Cement-retained implant prostheses allows easier access posteriorly and reduces costs, complexity of components, laboratory procedures and clinical chairside time. Cement-retained prostheses are made using standard restorative techniques.

Cement-retained prostheses have fewer insertion issues. Correcting a misaligned implant is easier with a cemented restoration. TempBond™ (KERR Corp) or a mix of TempBond™ and Vaseline® (Unilever), which can reduce strength, is useful to cement implant-supported restorations to allow some retrievability. (Note that Unilever does not support or endorse the use of Vaseline® to assist in cement-retained implant-supported restorations).

Abutment Selection

Criteria for Abutment Selection	Implications for Abutment Selection
Tissue Height	<ul style="list-style-type: none"> Abutment margins should be supragingival in non-aesthetic zones. Abutment margins should be slightly subgingival in aesthetic zones.
Crown Height	<ul style="list-style-type: none"> Abutment height must not exceed the available space for crown materials.
Interproximal Distance	<ul style="list-style-type: none"> Abutment width must be sufficient to support the crown. Interproximal access to hygiene instruments must be sufficient.
Angulation	<ul style="list-style-type: none"> Abutments must counter any implant angulation.
Aesthetics	<ul style="list-style-type: none"> Margin must be subgingival in aesthetic areas. Abutment emergence profile must support gingival tissues. Porcelain abutment will improve aesthetics.

Abutment Options

Prefabricated	<ul style="list-style-type: none"> Most implant systems offer prefabricated titanium and zirconia abutments. They may or may not be modified. Have set collar heights and taper. Solid abutments are a type of prefabricated abutment. Some are angled from the implant body to counter inclination of implants.
	<ul style="list-style-type: none"> Metal – can be titanium or cobalt chrome. Customised titanium abutments are machined from titanium Grade 5 alloy and are tested according to ISO 14801:2007 Fatigue Test for Endosseous Dental Implants. Metal abutments are stronger than zirconia abutments but may be less aesthetic in thin tissue biotype applications. (See below).
Custom-Designed Milled (CAD/CAM) (Metal or Zirconia)	<p>Metal</p>  <ul style="list-style-type: none"> A limitation of metal abutments is grey discoloration of peri-implant mucosa in patients with thin biotypes (Sailer, I., et al., 2009). Titanium abutments with nitride coatings have a gold-shaded hue and can be an alternative to ceramic abutments for high aesthetic demand cases. In large-span and heavy-load cases, stronger alloys are preferred. Metal abutments are stronger than zirconia abutments. <p><i>Milled titanium abutment.</i></p>
	<p>Zirconia</p>  <ul style="list-style-type: none"> “Zirconia abutment strength may be improved by an internal connection via a secondary metallic component” (Sailer, I., et al., 2009). <p><i>Zirconia abutment.</i></p>

**Titanium Milled Bases
(CAD/CAM)**



- Used as adhesive bases for individual implant-supported reconstructions made of:
 - » Monolithic or laminated zirconium-oxide ceramics
 - » Lithium disilicate (Hatai, Y., 2014)
 - » Ceramic-composite hybrids.

BellaTek Encode®



- System eliminates the need for implant-level impressions.
- Clinician takes an analogue or digital impression of the Encode® Healing Abutment.
- Abutment is “encoded” with special markings that, when scanned, relay abutment design and milling information.
- Minimises component swapping and gingival trauma.
- Preserves soft tissue critical for an aesthetic outcome.

Custom-Fabricated



The following abutments are wholly custom fabricated in the laboratory:

- UCLA (universal castable long abutment) is a castable abutment offered with a machined gold alloy base or in a fully castable version. It may be used for single- or multi-unit screw or cement-retained restorations. It may correct angles up to 30° degrees when cast as a custom abutment.

A **GoldAdapt™** is a UCLA which has a gold rim. Semi-precious or high-precious alloy is needed to cast onto GoldAdapt™.

Castable



- For example, Dynamic:
 - » Dynamic consists of a base with a semisphere, on which a burnout chimney sits and which can be freely moved to deviate from the axis by up to 28°. The fixation screw is unique and allows tightening while off axis with a screwdriver with a hexagonal 1.30-mm-faceted sphere.
- Three options:
 - » Cast-to Dynamic Abutment® 3.0 with cobalt-chrome (CoCr) milled base.
 - » Castable 3.0 Dynamic Abutment®.
 - » Cast-to Dynamic Abutment® 3.0 with Tilite® milled base.

Angle Screw Channel Parts

Original



- For example, Nobel ASC:
 - » The angulated screw channel (ASC) provides the option to place the screw access hole anywhere between 0° and 25° in a 360° radius.

Multi-Axial (MTX) Technology



- MTX are millable and enable angulated screw channels of up to 25°.

Multi-Unit Abutment

These are intermediate parts that are screwed direct to fixture. They change the angles so that the restoration is screwed onto them. This accommodates undesirable implant angulations. Hence, buccal access is not required and parallelism is improved.

B. FIXED OR REMOVABLE PROSTHESIS

Implant Treatment Options for the Edentulous Arch (Stanford, C.M., 2005)

Mandibular Arch:

- Fixed complete denture:
 - » Either gold casting or CAD/CAM milled titanium framework with prosthetic acrylic resin teeth
 - » Conventional fixed complete denture with acrylic teeth requires a minimum of 15.0mm from the alveolar crest to the planned incisal edge.
- Fixed bridge.
- Overdenture:
 - » Overdenture with attachment to the implant can be supported and retained fully by the implant or by a combination mucosa-borne/implant-borne prosthesis.

Maxillary Arch:

- Minimal bone resorption; ceramometal is possible.
- Consider replacing every three teeth with three-unit bridge on two implants using the pontic contours to adjust implant alignment and aesthetics.
- Fixed maxillary construction entails between six to eight implants with four independent bridges.
- In order to limit loading, six implants may be used with distal cantilevers on two bridges.

USE OF INDIVIDUAL ATTACHMENTS OR BARS FOR RETENTION OF REMOVABLE OVERDENTURES

Is an Overdenture Appropriate?

Two implants spaced between 12.0mm and 16.0mm apart (edge to edge) in the mandibular canine region can be restored with free-standing attachments such as ball attachments, locator (Zest Anchors, Escondido, Calif) or ERA (Sterngold, Attleboro, Mass) style attachments or an overdenture bar system (e.g. Hader Bar, Attachments International, San Mateo, Calif) and a plastic clip attachment in the denture.

Maxillary removable overdentures may be considered as a satisfactory treatment option for patients with complaints about the retention and stability of their dentures (Zembic, A. and Wismeijer, D., 2014). Maxillary overdentures with four to six implants typically connected with a rigid bar and clip attachment system is the treatment of choice in cases of moderate-severe resorption. Mucosal inflammation and mechanical problems (especially without palatal coverage) occur more often – retention system changes due to loosening/fracture especially in bruxers.

Maxillary and mandibular removable overdentures are typically fabricated with acrylic resin prosthetic teeth processed on a rigid acrylic resin base that may be reinforced with a metal frame, often used for the maxillary overdentures with a horseshoe-shaped design (Bryant, S.R., et al., 2007). The use of metal reinforcement is advisable, owing to the frequent base fracture that may be encountered because of the reduced bulk of acrylic resin in accommodating the attachment systems (Osman, R.B., et al., 2012).

Overdentures can be retained either by bar and clip attachments or by locators, ball-and-clip attachments, or cone-shaped telescopic copings. Bar-supported overdentures need less prosthetic maintenance. Bar reconstructions are appropriate for non-parallel implants in which the connecting bar is designed to parallel the retromolar pads (fulcrum of rotation) allowing the overdenture to gain retention from the bar and support from the mucosal tissues. If patients are sensitive to pressure on the mandibular mucosal tissues, the dentist should consider placing four implants that are connected with a rigid bar and overdenture that rests solely on the bar.

The use of either solitary attachments or bars requires adequate restorative space. The minimum vertical distance requirement from the implant platform to the incisal edges is 13.0mm to 14.0mm when bars are used (Phillips K. and Wong K.M., 2001).

Solitary attachments require only 10.0mm to 11.0mm. Implant angulation plays a critical factor in the retention of solitary anchors (Gulizio, M.P., et al., 2005). Surgeons should place implants in these cases with focused concern for parallelism.

Treatment Considerations for Mandibular Implant Overdentures:

(Sadowsky, S.J., 2001)

Indications:

- To maintain functional mandibular loading and minimise anterior alveolar resorption (may occur at 0.1mm per annum long-term), (Lindquist, L.W., et al., 1996; Naert, I., et al., 1998).

Quantity Required:

- Two in lower canine or first premolar sites.
- An implant-supported lower overdenture with two implants is the minimum standard of care (Feine, J. S., et al., 2002).
- Multiple implants are recommended in cases of:
 - » Dentate maxilla.
 - » High retention need.
 - » Implant length of < 8.0mm or implant width of < 3.5mm.

Contraindications:

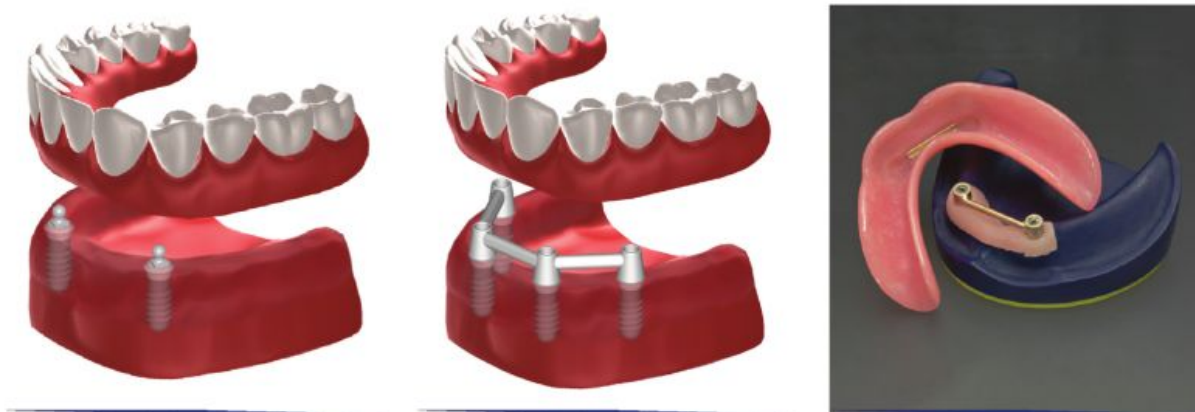- Younger patients or those edentulous for fewer than 10 years.

Considerations in Case Selection:

- Increased occlusal force may exacerbate anterior maxillary resorption and/or soft tissue inflammation.
- May offer only marginal increase in retention and stability compared to an implant-mucosa-supported overdenture.

Design Options:

- Ball attachments are more economical and more hygienic as well as less prone to hyperplasia in cases of two anterior implants.
- Bars are more retentive, less technique sensitive, and better suited for tapered arches.



Maintenance (Frequent Recalls):

- Overdentures retained by two implants in the anterior mandible need more maintenance during the first year than in later years.

Patient Satisfaction:

- These exhibit similar satisfaction to fixed implant complete dentures.
- Patients who value stability more than hygiene select a fixed prosthesis.

Treatment Considerations for Maxillary Implant Overdentures:

(Sadowsky, S.J., 2007, Sadowsky, S.J. and Zitzmann, N.U., 2016)

Quantity Required for Support:

- At least four implants (canine and second premolar sites) if there is no palatal coverage.
- No specific number required in other situations.

Design Considerations for Force Distribution:

- Broadly distribute designs across the anterior premolar area and tuberosities.
- Bars with distal cantilevers can increase the forces on the terminal implants.
- Bars are recommended when restoring divergent implants of more than 10°.

Inadequate Bone?

- Zygomatic implants in the atrophied maxilla must not be placed too palatally to avoid unusual substructure designs and overcontouring.
- A milled bar-retained implant-supported prosthesis may suit severe resorption cases.

Space:

- A bar design needs at least 15.0mm from the implant platform to incisal edge.
- The span length should not exceed 18.0mm.
- Use of attaching mechanisms (e.g. bar clip) requires a minimum distance of 10.0-12.0mm between implants or else use a milled bar with a frictional fit superstructure.

Rate of Loss:

- Short implants (less than 10.0mm) demonstrate lower survival rates.

Patient Preference:

- Patients prefer a palateless long-bar overdenture design to a fixed implant denture.
- Most patients prefer a removable prosthetic design.
- A tissue-borne overdenture needs fewer implants and is less costly than a fixed complete denture.

Complications:

- Higher rate of implant loss than other implant procedures.

Long-term success of overdenture therapy depends on periodic maintenance, with the most common requirement being replacement of the matrix portion of the different attachments. The frequency of replacement of the matrices varies and may be influenced by patient-related factors (e.g. parafunctional habits, dietary habits) and implant-related factors (interimplant distance, attachment angulations in relation to the occlusal plane) and type of attachment (Abi Nader, S., et al., 2011). The rubber O-ring should be replaced annually or biannually. The prevalence of wear reported for ball abutments with metal clips is lower than with the resilient rubber O-rings or nylon inserts (Kleis, W.K., et al., 2010).

DIFFERENT RESTORATIVE MATERIALS FOR DIFFERENT SITUATIONS

a. Materials for Crown and Bridgework

Restorative Options for Cement-Retained Restorations (CR)

Restoration	Cast Gold Abutment	Titanium OR Co-Cr Abutment	Zirconia Abutment*	Indications
PFM	✓	✓	Limited	Universal
IPS e.max®	Limited	Limited	✓	High aesthetics
PFZ/Lava™ Classic Zirconia Frame	✓	✓	✓(Aesthetics +)	Aesthetics + strength
FMZ	Limited	✓	✓	Strength + low cost

* Titanium interface in some cases.

1. Titanium interface is strong. When it is torqued down, it is unlikely to split zirconia abutments.
2. Some systems have a pure zirconia abutment direct to fixture depending on:
 - » Size of implant (narrow implants are unsuitable).
 - » Compatibility with scanners.

Restorative Options for Screw-Retained Restorations (SR)

Restoration	Retained	Indications	Explanatory Notes
PFM	✓	Universal	Direct to fixture with high noble, noble and cobalt chromium or titanium superstructure with porcelain veneering.
IPS e.max®	✓	Limited	<ul style="list-style-type: none"> • Titanium interface, monolithic combination abutment and crown. • Reduced strength/care in case selection (optimal translucent effect).
PFZ/Lava™ Classic Zirconia Frame	✓	Aesthetics/ strength	Titanium interface, zirconia abutment with veneering ceramic (optimal aesthetics).
FMZ	✓	Low cost/ strength	Titanium interface, monolithic combination abutment and crown (optimal strength).

Property	PFM		IPS e.max®		PFZ		FMZ	
	CR	SR	CR	SR	CR	SR	CR	SR
Strength	✓	✓	-	-	✓	✓	✓	✓
Retrievability	-	✓	-	✓	-	✓	-	✓
Aesthetics	✓	-	✓	✓	✓	-	-	-

Material Selection for Implant Restorations

		PFM	PFZ	FMZ	Resin	IPS e.max®
Properties	Strength	✓ ✓ ✓	✓ ✓	✓ ✓ ✓	✓	✓ ✓
	Longevity	✓ ✓ ✓	✓ ✓	✓ ✓ ✓	✓ ✓	✓
	Cushioning	✓	✓	✓	✓ ✓ ✓	✓
	Cost	✓*	✓ ✓	✓	✓ ✓	✓ ✓
	Aesthetics	✓ ✓	✓ ✓	✓	✓ ✓	✓ ✓ ✓
	Indications	Unlimited	Aesthetics Good strength	Strength	Cushioning, less force transmitted to implant (material wears)	Aesthetics
	Ability to be Repaired Intraorally	Limited	Limited	Limited but rarely needed	Excellent	Some but still limited

*Some alloy costs may increase overall cost considerably.

b. Materials for Removable and Fixed Prosthesis:

Framework and Bar Fabrication

Use of CAD/CAM technologies for manufacturing implant superstructures produces precision of the milled superstructures and passive fit (Drago, C., et al., 2010). CAD/CAM milling systems have facilitated the fabrication of cost-effective Co-Cr frameworks. Co-Cr superstructures may well be used as an alternative to gold alloy veneered with ceramic or acrylic resin (Teigen, K. and Jokstad, A., 2012).

Overdenture bars and screw-retained frameworks can be customised. A range of popular designs is available – Dolder® bar (CENDRES + METAUX – distributed by Sterngold), Hader® bar (HL TECHNOLOGY SA – distributed by Sterngold) and Locator® bars Overdenture Implant System (ZEST ANCHORS). One-piece screw-retained implant frameworks can be fabricated through ultra-precision scanners and state-of-the-art milling machines. Frameworks are produced in pure titanium grade 4. One CAD/CAM system is exclusively tailored to fabricate computer-designed and milled titanium alloy abutments and does not need laboratories to own digital/optical scanners/computerised milling units.

An overall ten-year cumulative prosthesis survival rate of 88.4% when titanium was used as the superstructure for metal-ceramic implant restorations, compared with 100% with the use of conventional metal alloys, was documented (Örtorp, A. and Jemt, T., 2008).

This relative failure is largely attributed to the excessive oxidation of the titanium metal during firing of the veneering porcelain.



Final Fit Check and Issue

For patient safety, it is wise to place gauze or a similar barrier in the mouth to reduce the risk of ingestion or inhalation of components or prostheses during fitting.

SINGLE TOOTH IMPLANT

a. Anterior Restorations

Contour tissues with a provisional crown. When inserting a provisional crown for the first time, slight expansion of tissue should provoke blanching for about 20 minutes and may require local anaesthesia.

b. Posterior Restorations

Access can be difficult.

Cement-Retained Crowns	
At Try-In Appointment	Troubleshooting
Confirm shade suitability with patient.	<ul style="list-style-type: none"> Retake shade if required. Check that crown shade matches shade tabs used in laboratory prescription.
Take radiograph to confirm seating of abutment and crown and confirm all residual cement debris has been removed from subgingival areas.	<ul style="list-style-type: none"> Retake impression if crown is unable to be seated.
Check contact points with dental floss and then mark contacts using double-sided thin articulating paper and Vaseline®.	<ul style="list-style-type: none"> If contacts are too tight, slightly flatten contact points of adjacent teeth to increase the contact surface of implant crown. If contacts are too loose, retake impression and return crown to laboratory for adjustment, or modify proximal restoration on adjacent tooth (if possible).
Check occlusion.	<ul style="list-style-type: none"> Verify no error made in selecting analogue. Each implant diameter is associated with one matching analogue. Verify abutment sits properly on model. Verify no interfering material at abutment connection. Verify implant head free of debris. Retake impression if crown is unable to be seated.
Screw-Retained Crowns	
At Try-In Appointment	Troubleshooting
Try in crown without applying full torque to retaining screw.	Check that the correct screw and driver are being used.
Verify seating with radiograph. Make sure screw turns without resistance until last quarter turn is reached.	Verify crown is engaging implant head or abutment completely.
Once crown(s) seated, verify and adjust contact points, occlusion and shade as above.	Ensure no debris or soft tissue between crown and implant or abutment.
Torque screw to recommended amount.	Retake impression if problems in seating restrict torqueing.
Cover screw head with cotton pellet, temporary restoration and then seal access cavity with composite resin.	Adjust proximal contacts. Check implant orientation in the mouth is exactly the same as on the model.

CLINICAL TESTING FOR PASSIVE FIT OF A SCREW-RETAINED BRIDGE

Implant bridges should seat with all screws requiring a similar force to tighten. Where one screw seems to require excessive force or does not engage, this indicates an absence of passive fit. Forcing screws into place can bend the framework and cause tension in the framework, which is unfavourable to the stability of the screws and bridge and implant.

Problem	Problem Cause	Solution
There is resistance when engaging a screw.	One of the impression copings was misaligned.	<ul style="list-style-type: none"> Put framework aside. On model make a resin framework and section between each implant. Try-in in mouth. The framework piece that is misaligned indicates the malpositioned analogue.
One mesial-distal (M-D) screw is in place, but the opposite screw is not engaging at all.	The framework is distorted M-D and B-L.	<ul style="list-style-type: none"> Leave the first screw in place. Place a screw in the immediately adjacent implant. If there is a misfit, section between these two implants. Rejoin as below.* If not, repeat with the next implant.
One M-D is in place but the opposite screw engages with more resistance.	The framework is distorted apicocoronally. The screw is forcing the framework apically, so the unsecured end of the prosthesis lifts.	<ul style="list-style-type: none"> Leave the first screw in place. Place a screw in the immediately adjacent implant. If there is a misfit, section between the two implants. Rejoin as below.* If not, repeat with the next implant.

SUMMARY OF PROCEDURES AND SEQUENCES FOR RESTORATIVE PHASE

(Sethi, A., et al., 2005)

Procedures and Steps	Single Tooth	Multiple Units	Full Arch Reconstruction
Impression	Visit 1	Visit 1	Visit 1 Preliminary intermaxillary registration
Intermaxillary Registration	Visit 1 Intercuspal position (ICP)	Visit 1 ICP	Visit 2 Wax rims on acrylic framework screwed down
Diagnostic Preview (Confirm Colour, Form, Occlusion)	Transfer from original preview	Transfer from original preview	Visit 3 Setup of teeth on acrylic framework to confirm original preview
Metal Work/Framework Try-In (Accuracy and Passivity of Fit, Relate Soft Tissues to Framework)	Not usually necessary	Visit 2	Visit 4 Cast in sections for locating or pre-soldered/laser welded
Re-Try of Metal Work* (Confirm Accuracy and Passivity of Fit)	Not usually necessary	If required	Required if sections located intra-orally at visit 4
Try-In of Unglazed Porcelain (Confirm Form, Colour, Occlusion)	Visit 2	Visit 3	Visit 5
Insert Prosthesis	Visit 3	Visit 4	Visit 6
Review	Visit 4	Visit 5	Visit 7+

***Try and adjust framework if not passive seating:** Section and "solder" with acrylic resin e.g. Duralay™ if needed till seating is accurate. Take bite registration. Take impression with framework in the mouth if 100% seated. Remount.
Post-bridge issue: Provide nightguard.

PROSTHETIC FAILURE IN IMPLANT DENTISTRY

Biomechanics of Implant-Supported Restorations in Partially Edentulous Patients (Sadid-Zadeh, R., et al., 2015):

- Decrease the resistance to adverse leverage forces during function.
- Implants should be centered mesiodistally and as perpendicular as possible to the occlusal surface.
- Biomechanical forces are affected by cuspal inclination, implant inclination, horizontal offset of the implant and apical offset of the implant.
- Finite element analysis of implant-supported restorations showed the largest amount of stress is concentrated at the coronal part of the alveolar bone at the implant-bone interface. This stress level increases with the vertical interarch space.

Complications in Restorations

A. SINGLE IMPLANT

1. Loosening of the Abutment Screw:

- Design of the Implant Connection.
 - » External-connection (EC) implants (Gracis, S., et al., 2012) had higher incidence of screw loosening than internal-connection (IC) implants (Mangano, F.G., et al., 2014)
 - » Screw loosening was higher with screw-retained restorations with EC implants than with cement-retained restorations with EC implants (Zembic, A., et al., 2013, Preciado, A., et al., 2012).
- Anterior or Posterior Restorations?
 - » More in anterior (Schwarz, S., et al., 2012) than posterior restorations (Cha, H.S., et al., 2013)
 - » Anteriorly more associated with abutment design of EC implant
 - » Posteriorly more associated with IC implants.
- Occlusal issues/bruxism.
- Non-axial forces.
- Incomplete seating.
- Impression distorted – leading to mal-alignment in the mouth.
 - » Retake impression.
- Not enough torque/damage to screw head.
- Screw recoil.
- Damage to screw thread.

Clinical Treatment:

- Torque the abutment or the screw-retained crown twice.
- Follow manufacturer's specification exactly with 5-minute intervals.
- Use an implant with IC, reduce cuspal inclines. Eliminate heavy occlusal contacts.

2. Fracture of the Veneering Ceramic or the Crown:

- Material – more with ceramic than metal-ceramic restorations (Bergenblock, S., et al., 2012).
- Design of implant connection – more with EC implants (Nothdurft, F. and Pospiech, P., 2010).
- Anterior or posterior restorations? More with posterior restorations (Hosseini, M., et al., 2011).
- Type – more cement-retained (Lai, H.C., et al., 2013) restorations (Vandeweghe, S., et al., 2012).

Clinical Treatment:

- Reduce occlusal table, shallower cusp height, lighten occlusal contacts. Uniform support for ceramic.

3. Decementation:

- Measured over 5.2 years had a 6.1% incidence.
- The incidence was negligible when glass ionomer or resin cements were used.

Clinical Treatment:

- Use resin-reinforced cement to reduce the chance of decementation, especially if retention form is compromised due to limited occlusal clearance.

4. Fracture of the Abutment or the Coronal Fixture:

- 0.5% of restorations reported a mean at 4.4 years.

B. PARTIAL FIXED IMPLANT-SUPPORTED PROSTHESIS (PFISP)

1. Chipping or Fracture of Veneering Material:

- Observed in 12.4% cases over a mean of 5.7 years (Nedir, R., et al., 2006).
- Similar for PFISP restored with IC implants and EC implants (Kreissl, M.E., et al., 2007).
- Higher in screw-retained restorations (Nissan, J., et al., 2011).

2. Loosening of Screws:

As per for single implant – see above:

- Observed in 5% of cases (Wahlström, M., et al., 2010).
- Higher in screw-retained restorations (Nissan, J., et al., 2011).
- Design of the implant connection:
 - » Higher for PFISPs with an EC implant (Kowar, J., et al., 2013) than for IC implant (Pozzi, A., et al., 2012).

3. Screw Fracture:

- Incidence of 3.6% over 5.4 years (Romeo, E., et al., 2009).

4. Structure of Framework:

- Reduce occlusal table.

5. Abutment Fracture:

- Ensure correct torquing.
- Beware of bruxism.

6. Design of Implant Connection:

- Choose system wisely.
- Availability of multi-unit or angled screw channel options to be considered.

7. Decementation:

- Retention form important.
- Choice of cement may influence risk.

C. IMPLANT-SUPPORTED FIXED DENTURES

1. Fracture of the Veneering Material

Acrylic, ceramic, or composite (Pjetursson, B.E., et al., 2012):

- 13.5% of the FDPs had minor or major fractures of the veneering material after five years.
- More likely in bruxers.
- Reduce cantilever or eliminate altogether.
- Design of frame.

2. Loss of Screw-Access Hole Restoration:

- Related to bonding failure to restoration.
- Choice of material may need to be reassessed.
- Best if have some undercut.

3. Occlusal Screw Loosening

As per for Single Implant – see above:

- Torquing.
- Parafunction resulting in increased occlusal forces.

4. Fractures of the luting cement

5. Fractures of abutments and occlusal screws:

- More likely in bruxers.
- Accuracy of fit.

6. Fracture of implants and frameworks:

- More likely in bruxers.
- Accuracy of fit.
- Long-term studies on implant-supported complete dentures show a longevity-related prevalence of complications, with increased prevalence of resin fractures at the beginning of the clinical period and progression of severe wear in the later stages of follow-up (Jemt, T. and Johansson, J., 2006).

OTHER COMPLICATIONS

Inflammation and Peri-Implantitis

During maintenance, gingival inflammation can be detected. It may either be mucositis, which is reversible without evidence of bone loss or peri-implantitis, which can lead to bone loss (Thoma, D.S., et al., 2012). Most frequently, mucositis is caused by abutment loosening. The loosening of the abutment enables bacterial infiltration. If the mucositis caused by abutment loosening goes undetected, it can result in peri-implantitis (Lindhe, J. & Meyle, J. 2008). Mucositis lesions can show apical progression after three months of plaque build-up around implants.

In order to detect abutment loosening, look for abutment separation on the radiograph, which is seen as a dark line between the components, and also prosthesis mobility. Abutment loosening can result in uncomfortable pressure on the prosthesis if gingival tissue has overgrown into the opened junction. The excess soft tissue must be removed before the abutment or prosthesis can be tightened back into place.

Treatment of peri-implantitis involves inflammation control and modifying the exposed implant surface.

Occlusal Factors

The occlusal status of the implant and its prosthesis must be assessed routinely at every maintenance appointment. Occlusal overload can cause a variety of problems, including loosening of abutment screws, implant and prosthetic failure (Zarb, G.A. and Schmitt, A., 1990).

Occlusal contact patterns should be assessed as well as the mobility of the implant and opposing dentition. Successful implants should not be obviously mobile. A failing implant is not mobile until all or most of the bone has been lost.

Abnormal occlusal loading will negatively affect the various parts of the implant-supported prosthesis. Hence, premature contacts or interferences should be identified and corrected to prevent occlusal overload. There should be light centric contact with no contacts in lateral excursions (Engelman, M., 1996).

Bausch Arti-Fol® metallic black/red shimstock film BK 28-12 microns (Bausch GmbH + Co. KG) should be able to be held only with hard clenched teeth (Kerstein, D.M.D. and Robert, B., 2014). Possible bruxism and parafunctional activities must be evaluated as excessive concentrated forces can result in rapid and significant peri-implant bone loss. If a failed implant is connected to a multi-unit prosthesis, it may mask evidence of mobility.

IMPLANT MAINTENANCE PROTOCOLS

(Lang, N.P., et al., 2000)

These should be customised and re-evaluated for each patient. There is insufficient data on exact recall intervals, methods of plaque and calculus removal and appropriate antimicrobials for maintenance around implants.

The maintenance appointment should include assessment of:

- Presence of plaque and calculus and oral hygiene and possible need for antimicrobials.
- Peri-implant tissue and deposit removal from implant/prosthesis surface.
- Occlusal status and stability of prostheses and implants.
- Probing depths and presence of exudates or bleeding on probing.
- Mobility – any movement would indicate possible lack of osseointegration of the fixture, possible failure of the cement bond between the superstructure and the retainer, or screw failure by fracture or loosening.

If an abutment is loose, then the microgap widens, which can result in the formation of a fistula.

09

REMOVABLE PROSTHODONTICS




Overview

Dentures are one of the most difficult aspects of dentistry, especially for new graduates. In fact, no matter how much experience you might have, dentures often present a unique set of challenges. How does one get retention when there's no ridge to work with? How do we adapt our knowledge of dentures to make them useful in restoring full arches on implants, enabling cost-effective restorations for our edentulous patients that can overcome conventional retention headaches?

Instead of cringing when you see a denture case on your day sheets, you now have the opportunity to develop a clear understanding of all the steps necessary for success. Of course, expertise in removable prosthodontics doesn't come overnight. Nor can dentists always meet the high expectations of patients who present with cases that will involve compromise. However, what is certain is that prosthodontics can be done well when you have a sound grasp of all the steps necessary for success.

As you read this chapter, we hope you are inspired to rise to the challenge that prosthodontics can pose.



REMOVABLE PROSTHODONTICS

Removable Partial Dentures (RPDs)

“RPDs are indicated as a choice of treatment of partially edentulous patients when the length of the edentulous span contraindicates a fixed partial denture, there is a need for residual ridge support for mastication, or a patient has a guarded prognosis for their periodontal condition” (Bohnenkamp, D.M., 2014). RPDs are suitable for excessive loss of residual ridge, obtaining proper tooth position not achievable due to the biomechanics of dental implants, patient oral hygiene issues, and existence of a large maxillofacial defect which necessitates cross-arch stabilisation.

FUNCTIONS OF A PARTIAL DENTURE:

- Restore aesthetics and function.
- Be retentive and stable.
- Distribute masticatory forces.
- Prevent tooth drift and overeruption.

The Support for the Partial Denture can be:

- Mucosa-borne (like a full denture).
- Tooth-borne where the support is distributed through the remaining teeth.
- Tooth- and mucosa-borne.

Components of Partial Dentures

1. Saddle	<ul style="list-style-type: none"> • Carries artificial teeth over the edentulous area. • Can be mucosa-borne and/or tooth-borne. • Should cover the maximum surface area possible to maximise load distribution. • Occlusal table should be as narrow as possible.
2. Occlusal Rests	<ul style="list-style-type: none"> • Occlusal, incisal or cingulum rests allow support for tooth-borne dentures. • Seats are prepared in the tooth surface to enable axial loading.
3. Retainers	<ul style="list-style-type: none"> • Provide retention against dislodgement forces. Two main types of clasps: <ul style="list-style-type: none"> » Suprabulge (occlusally approaching) The whole arm touches the tooth but only the flexible tip engages the undercut » Infrabulge (gingivally approaching) This approaches the undercut from the gingival area. The clasp tip contacts the tooth
4. Reciprocation	<ul style="list-style-type: none"> • Reciprocation acts to keep the tooth in place as the clasp exerts a force. • It is on the opposite side of the tooth to the clasp tip and is either a reciprocating arm or plate.
5. Connectors	<ul style="list-style-type: none"> • Connectors link saddles and other parts. • Major connectors link saddle areas and most commonly are plates or bars. • Mandibular dentures have either bar or plates. • A minor connector attaches small parts like occlusal rests and clasps to the denture.

Kennedy Classification of RPDs

Class I	<ul style="list-style-type: none">• Bilaterally edentulous posterior segments.• Modifications 1, 2, etc., indicate number of additional edentulous spaces in the remaining dentulous segment.
Class II	<ul style="list-style-type: none">• Unilaterally edentulous posterior segment.• Modifications as in I.
Class III	<ul style="list-style-type: none">• Loss of teeth produces a posterior bounded saddle.• Modifications as in I.
Class IV	<ul style="list-style-type: none">• Tooth loss produces an anterior bounded saddle.• Modifications as in I.

Design of RPDs

Most classic designs for the four Kennedy classifications of RPDs are based on three fundamental principles: support, stability, and retention (Carr, A.B. and Brown, D.T., 2010). Class III RPDs are completely tooth-borne and do not receive support from the underlying edentulous residual ridge; the retentive clasping concepts are much more simplified than Class I and II RPDs, which are both tooth-borne anteriorly and tissue-supported posteriorly.

RPD designs require that support be derived from the remaining teeth, the hard and soft tissues of the residual ridge, or both. Healthy teeth can be displaced by as much as 0.2mm and the soft tissue overlying residual bone can be displaced by 1.0mm or more. "Choose direct and indirect retentive components that prevent displacement of an RPD away from and toward the teeth and soft tissues" (Phoenix, R.D. and Fleigel, J.D., 2008).

DESIGNS FOR RPDS

(Bohnenkamp, D.M., 2014)

Major Connectors in the Maxillary Arch

Borders should:

- Be placed a minimum of 6.0mm from the gingival margin or on the lingual surfaces of teeth.
- Follow the valleys between the crests of the rugae on the anterior palate.
- Cross the midline at right angles.

The palatal strap should not be less than 8.0mm wide.

Major Connectors in the Mandibular Arch:

Lingual Bar:

- Superior border should be 3.0mm from the gingival margin and the bar itself 5.0mm wide.
- Total depth of 8.0mm should be available on the lingual surface of the mandible.

Lingual Plate:

Use if planning to extract compromised teeth and add replacement teeth to metal framework in future.

Should be:

- Scalloped interproximally and cover the cingulum.
- Supported bilaterally by a rest located no further posteriorly than the mesial fossae of the first premolars.

Retentive Elements for Distal Extension Denture Bases:

- Maxillary arch should extend the entire length of the residual ridge over the tuberosity.
- Mandibular arch should extend two-thirds the length of the edentulous ridge and never extend onto or cover the retromolar pad.
- Use open latticework with one strut between each tooth for attachment of denture base to framework.
- Request a metal tissue stop on all distal extension designs. (Add acrylic resin stop if metal frame can be displaced toward tissue at try-in.)

Rest Seats:

- Occlusal rest seat preparation for posterior teeth – one-third to one-half the mesiodistal diameter and half the facial-lingual width measured from cusp tip to cusp tip. Floor of the rest seat angled downward toward centre of tooth. Tooth reduction should be at least 1.0mm and may need 1.5mm at the marginal ridge for an adequate thickness of metal.
- Maxillary canine – lingual or cingulum rest.
- Mandibular canine – incisal rest. Small V-shaped notch located 1.5–2.0mm from the proximal-incisal angle of the tooth **OR**
- Mandibular canine – cingulum rest with bonded composite resin if metal rest on incisal is unaesthetic or interferes with occlusion.

Clasps

The choice of direct retainers made by clinicians for RPDs can be either suprabulge (cast circumferential clasp and wrought wire clasp) or infrabulge (I-bar or T-bar). The three most common designs for distal extension RPDs include I-bar, T-bar, or round wire clasps. The design of a clasp assembly affects the magnitude of movement of abutment teeth adjacent to a distal extension base but does not affect the direction of movement (Browning, J.D., et al., 1986). The stability of the denture base seems of greater importance than the type of clasp retainer in terms of abutment tooth mobility (Barco Jr, M.T. and Flinton, R.J., 1988).

Clasps – Undercuts and Types:

- 0.25mm – amount of retentive undercut needed for cast metal half-round circumferential clasps.
- 0.5mm – amount of retentive undercut needed for wrought wire or cast metal round clasps.
- Circumferential – suprabulge half-round cast clasp needs 0.25mm mesiobuccal or distobuccal undercut; contraindicated for Kennedy Class I or II distal extension arches.
- Reverse circumferential - suprabulge half round cast clasp may engage a 0.25mm distofacial undercut of an abutment tooth adjacent to the Kennedy class I or II distal extension edentulous space.
- T-bar or 1/2 T-bar – infrabulge cast clasp needs 0.25mm distobuccal undercut; contraindicated if deep soft or hard tissue undercut present.
- I-bar – infrabulge clasp needs 0.25mm midbuccal undercut; contraindicated if deep tissue undercut present.
- Wrought wire – suprabulge clasp needs 0.5mm mesiobuccal undercut; contraindicated if aesthetics is a major concern.
- Only one-third of the end of a retentive clasp should be in the undercut; enameloplasty indicated if approach arm of clasp is below height of contour on abutment tooth.
- Reciprocal clasp must be located above the survey line, close to the height of contour, but no higher than the middle third of the tooth, preferably at the junction of the gingival and middle third of the tooth.

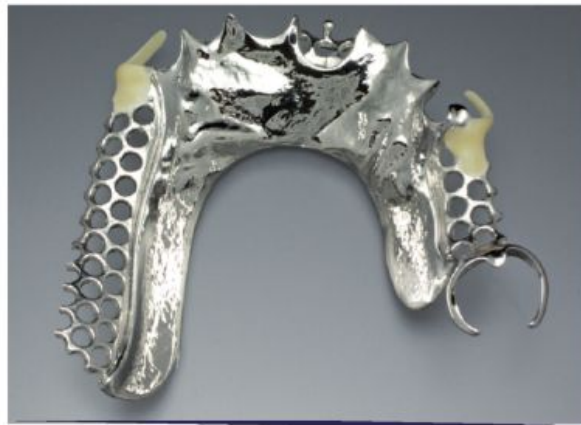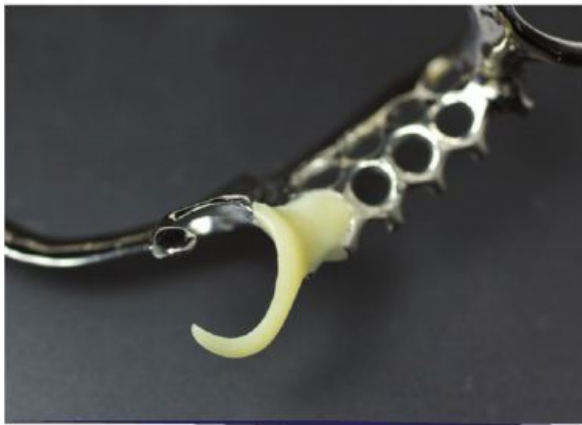Tooth-Coloured Clasps

DENTAL D TOOTH-COLOURED CLASPS

Dental D Clasps DurAcetal™ (Myerson Tooth Company) are a durable, aesthetic, metal-free acetal resin alternative to metal clasps. They possess high tensile and shock strength with excellent resilience, allowing the clasp to flex over extreme undercuts, whilst still providing a comfortable fit. Dental D is available in an array of tooth- and tissue-coloured clasps that exhibit long-term colour stability.

Many patients don't want to show stainless steel or chrome clasps any more: offering tooth-coloured or clear clasps as retentive adjuncts to standard acrylic, flexible or cast dentures is now prudent for every practitioner. DurAcetal™ is a pure, highly crystalline acetal copolymer resin possessing high tensile and flexural strength, fatigue resistance and hardness. These properties, when combined with its very low moisture absorption, make DurAcetal™ an ideal material for clasps. It is available in nine shades. VisiClear™ (Myerson Tooth Company) is a state-of-the-art thermoplastic material for clear clasps. 100% monomer and nylon free, strong, flexible, and stain resistant, these clear clasps provide long-term retention with the ultimate in aesthetics.

The combination of acetal resin clasps, a cobalt-chromium framework and conventional acrylic saddles make the appliance aesthetic, strong, tooth and tissue supported, comfortable and easy to reline or add to in the future.



Cobalt-chromium dentures with resin clasps.

Comparison Between Cobalt-Chromium and Dental D-Acetal™ Resin Clasps

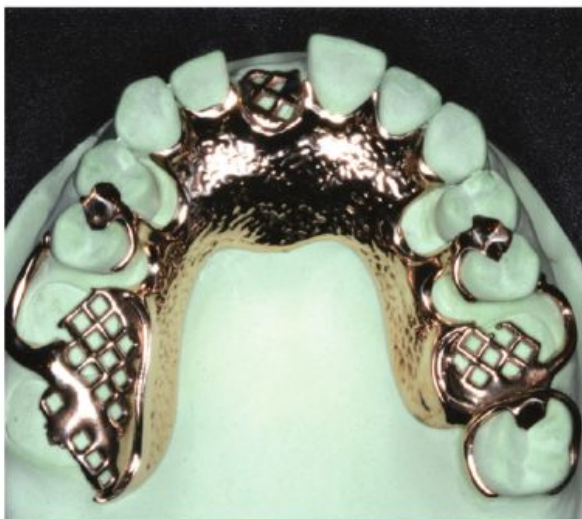The aim of a study by Atito, A.M., et al., (2006) was to evaluate and compare the mechanical properties of cobalt-chromium alloy and acetal resin clasps. Tensile strength and transverse strength tests were performed on 10 specimens of each material using the computerised testing system model LRX plus the Vickers hardness test was also performed following embedding the fractured transverse specimens in epoxy resin. The results revealed statistically significant differences in ultimate tensile strength, yield strength, percentage elongation and modulus of elasticity between the tested specimens. The Dental D-Acetal™ resin group showed higher values than the other metallic group for the transverse strength and Vickers Hardness.

Conclusion: Dental D-Acetal™ resin is a highly versatile material that can be used to replace cobalt-chromium clasps because of its superior aesthetic, mechanical and biocompatible properties. Its use is recommended for gingival areas rather than in load-bearing situations.

Denture Base Material

A variety of materials is available for removable dentures – hard or flexible acrylic with or without metallic frameworks made of a selection of different alloys customised for each patient. For cast denture bases, a wax pattern is produced in preparation for investing with a phosphate-bonded investment and subsequent casting. Cobalt-chromium is the most popular type of material and has achieved a high level of success for RPDs.

Gold alloys, not widely used, provide excellent fit and flexibility. Pure titanium or titanium alloys have gained popularity. Titanium RPD frameworks are light, flexible and non-allergenic. They need more bulk for strength and do not polish as well as cobalt-chromium.



Cobalt-chromium maxillary denture on study model.

Steps for Successful RPDs

Planning	<p>Use a surveyor:</p> <ul style="list-style-type: none"> • Surveying shows undercut areas that can provide mechanical retention • Guides the correct position of rests, major connectors, guide planes and crown position relative to the abutments <p>Diagnostic casts:</p> <ul style="list-style-type: none"> • Use stock trays and alginates for primary impression • Pour alginates within one hour • Consider use of Alginot™ – no pouring up needed • Employ interocclusal registrations if occlusal is not self-evident • Facilitate the planning of the RPD design • Enable special tray fabrication for secondary impressions and provide a permanent record for medico-legal requirements
Secondary Impressions	<ul style="list-style-type: none"> • Class I, II and IV RPDs require border moulding with a special tray. If using PVS, use light body on all the teeth and heavy body in the tray.
Clinical Procedure	<ul style="list-style-type: none"> • Tooth preparation for rest seats. Use pumice and water to clean teeth. Rinse well. • Take impression.
Final Casts	<ul style="list-style-type: none"> • Use stone or densite (die stone) if pouring models.
Interocclusal Records	<ul style="list-style-type: none"> • Preferable to use fast-setting, filled, addition-reaction silicone for accuracy. • Check material does not obscure occlusal contacts that define the occlusion.
Occlusal Rims	<ul style="list-style-type: none"> • Made from resin and wax. Useful for many Class I, II and IV RPDs. • Sometimes useful before final casts are sent for framework construction but usually used at the framework try-in stage.
Framework, Try-in and Records	<p>Ensure:</p> <ul style="list-style-type: none"> • Passive fit of framework. • Stability of framework across the arch. • Framework does not interfere with normal tooth-tooth contacts. • Wear-resistant resin teeth are chosen. <p>Avoid porcelain teeth unless full lower opposing denture has porcelain teeth.</p>
Teeth Try-In	<ul style="list-style-type: none"> • Confirm appropriate occlusal scheme and aesthetics are approved by patient.
Issue	<ul style="list-style-type: none"> • Confirm proper seating of acrylic and framework. Verify retention, and extensions.

Implant-Supported Removable Partial Dentures (ISRPDs)

The principles of RPD design must also be applied where implants are being incorporated.

INDICATIONS FOR ISRPDs:

- Assist patient after loss of several implants with “step-back solution” (fixed to removable).
- Remaining dentition not suitable to be used as an abutment.
- Patient does not want to lose all the teeth even if teeth not strategically suitable.
- Gradual implant placement and transitional removable partial is needed.
- Advanced ridge resorption in edentulous areas so added stability and retention needed.
- Surgical augmentation procedures to place needed implants are contraindicated.
- Desire for clasps not to be visible and denture base is to be smaller.
- Jaw relationship is difficult and placing teeth in centric occlusion will threaten denture stability.
- Extremely angulated implants cannot be treated conventionally.

CONTRAINDICATIONS FOR ISRPDs:

- Patient not suitable for surgery.
- Patient unable to wear removable denture.
- Interocclusal or interarch distance does not allow placement of an implant attachment.

ADVANTAGES OF ISRPDs:

- Enhanced aesthetics compared to conventional dentures.
- Change of fulcrum axis possible.
- Reduced forces on remaining teeth.
- Vertical support may be increased in free-end partially edentulous arch situations.
- Improved retention and stability.
- Path of insertion improved with implant abutments.
- May reduce need for indirect retention.
- Reduced pressure or trauma on supporting tissues.
- Bone is preserved around implants.

DISADVANTAGES OF ISRPDs:

- Increased cost and treatment time – multidisciplinary approach needed.
- Time required for osseointegration.
- Treatment more technique sensitive.

COMPLICATIONS ASSOCIATED WITH ISRPDs

Mechanical complications associated with ISRPDs are similar to those associated with Implant Supported Overdentures (ISODs). ISRPDs with distal extension revealed an implant survival rate of 95% to 100% (De Freitas, R.F.C.P., et al., 2012). Complications associated with ISRPDs include the need for repairing or relining the prosthesis, replacement of attachments, loosening of screws, and the need for repair of the acrylic denture base (Sakar, O., 2016).

Digital Removable Prosthodontics

Digitally designed and fabricated dentures are currently available in selected markets. They utilise CAD/CAM technology to provide virtual designs. These technologies are adaptable to both full dentures and partials. Current technologies favour conventional impressions. Poured models are then scanned.

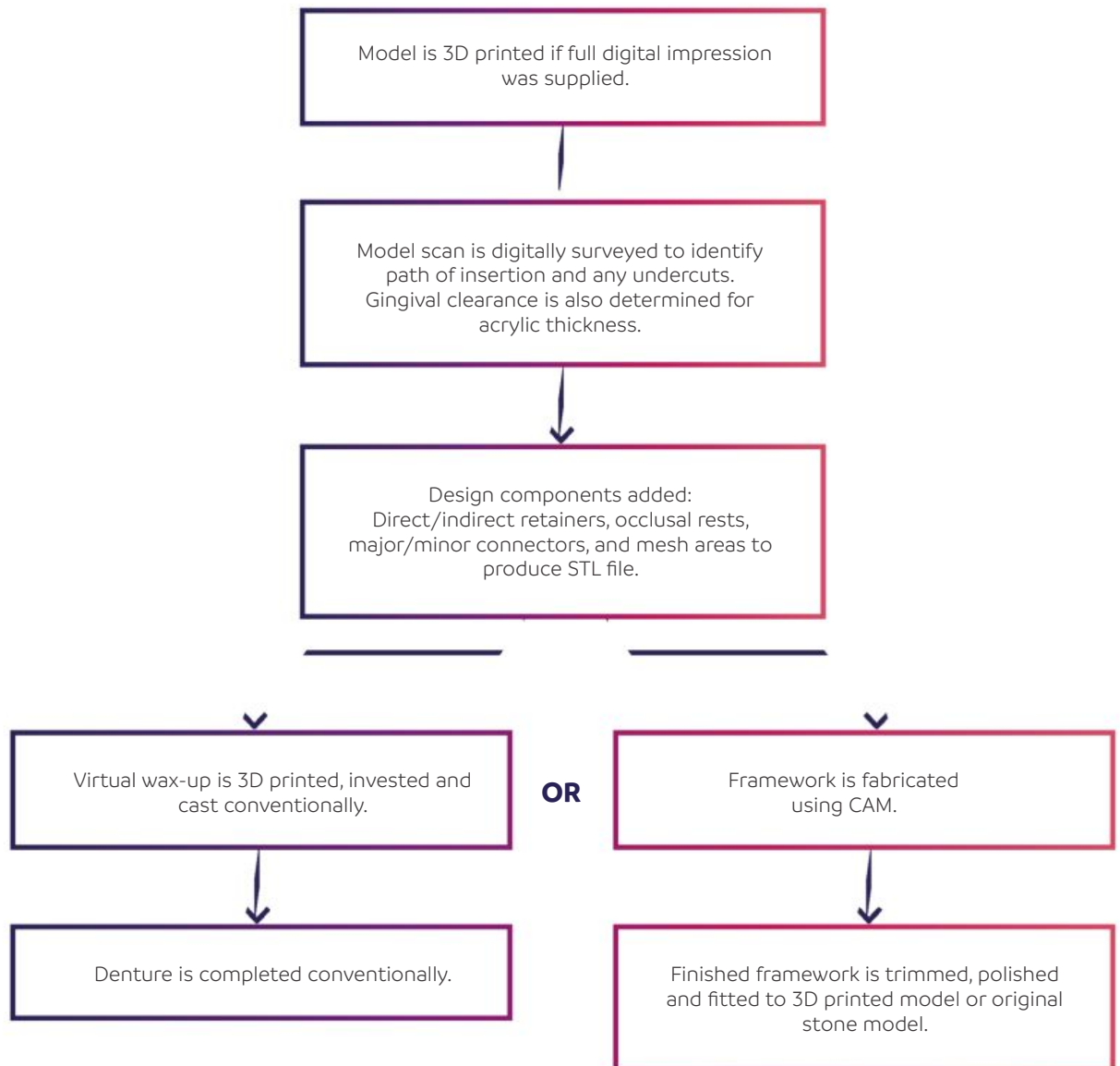
Full arch intraoral scanning is available, though inaccurate (Patzelt, S.B., et al., 2014, Ender, A. and Mehl, A., 2015, Ender, A., et al., 2016). There is an inability to capture appropriate extensions of movable tissue and to replicate mucocompressive loads into the final design (Kattadiyil, M.T., et al., 2014). Thus, conventional impressions are still recommended for full arch impressions.

DIGITAL METAL FRAMEWORK PARTIALS

Currently there are three approaches to CAD/CAM partial dentures:

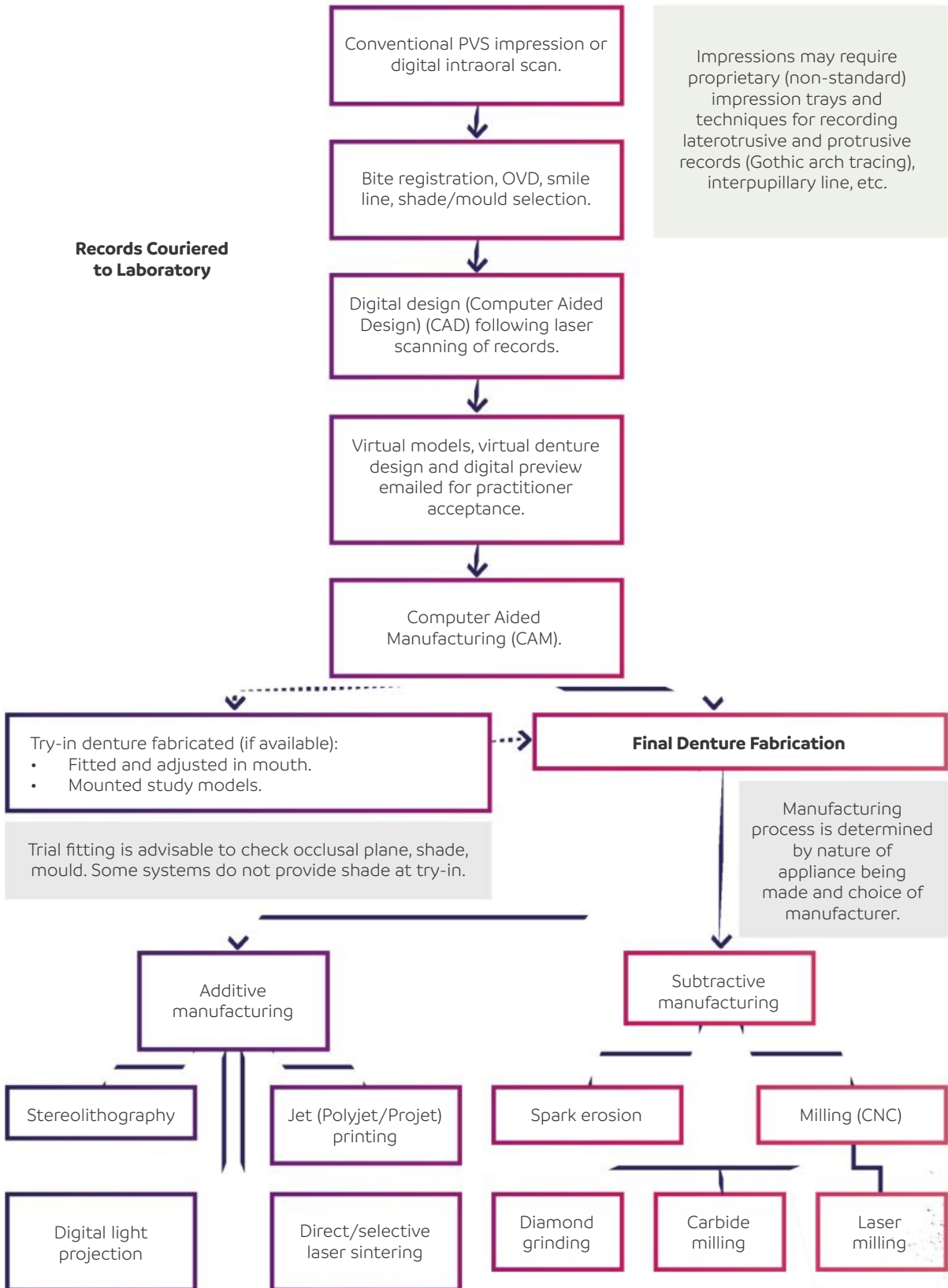
1. Full digital – intraoral scans are used to design a virtual wax-up to fabricate the metal framework.
2. Conventional impressions are scanned in the laboratory, a virtual wax-up is designed and the metal framework is fabricated.
3. Conventional impressions are scanned in the laboratory, a virtual wax-up is designed and printed. This is then invested and cast conventionally.

Digital Design, Virtual Wax-Up and Fabrication of Framework



Flow Chart of CAD/CAM Denture Production

(Adapted from Bilgin, M.S., et al., 2016)



Precision Attachments

The balance between function and aesthetics in removable prosthodontics requires providing solutions with small interlocking devices, called “precision attachments,” which connect the prosthesis to the abutment teeth.

These devices can be classified as:

INTRADENTAL ATTACHMENTS

These attachments are housed within the crown or root structure of a natural tooth. Intra-dental attachments can be further classified into two groups indicating the type of retentive mechanism used to unite the parts. They are:

- Frictional, with designs having tapered and parallel-walled boxes and tubes, adjustable metal plates, springs, studs or locks.
- Magnetic.

FRICTIONAL

Tapered and Parallel-Walled Boxes and Tubes

These attachments link sections of a bridge. They can be made separately by making a deep interproximal occlusal rest or box within the wax pattern of a crown. After casting the crown, the male part of the attachment is made by flowing wax into the box. Then, the wax pattern is joined to the wax pattern of the adjacent crown or pontic. Plastic prefabricated patterns can be included into the wax pattern of the proposed restoration. These attachments require extra support for direct retention. The tapered varieties ensure vertical support and lateral stabilisation. They are pin and tube or rectangular block and box assemblies. These should be within the natural tooth contours. Preparations will be required within the teeth.

Adjustable Metal Plates

These attachments are made so that there is increased friction between the parts. A narrow slit is provided in the male part of the attachment. This provides a simple form of direct retention; an example is the Stern Latch® IP/C complete (Sterngold) attachment. The length of the slit within the block affects the flexibility of the retaining mechanism. A minimum of 2.5mm of tooth height is required. The movement and life span of the metal is finite. Eventually, these attachments fatigue. At that stage, the male portion attached to the denture must be replaced.

Springs

When a small spring is included within the metal block to control the friction between the male and female parts, greater efficiency is achieved. The spring activates a plunger rod which juts out from the block which touches a depression in the wall of the box. When it deteriorates, it can be replaced. Springs require 4.0-5.0mm of vertical height between the occlusal surface and the gingival crest.

Studs

Direct retention for a removable partial denture or overdenture can be gained by using a stud that clips into a flexible ring. A metallic stud can be soldered to a post and core and cemented into an abutment tooth. The ring is kept within a cavity in the denture base; an example is the Ceka® (Alphadent NV) attachment.

Locks

Parts are available that lock rigidly together. Parts of a fixed prosthesis are put together by the dentist directly on the teeth and connected by the attachment screw. The sections can be easily removed if needed. The vertical height required for this attachment is at least 6.0mm.

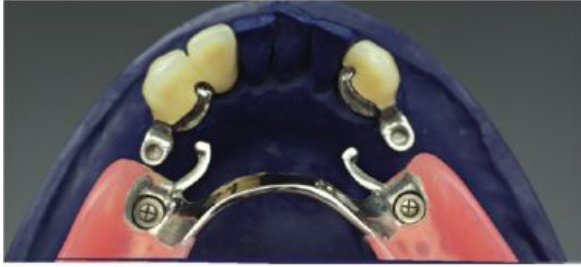MAGNETIC

A small, strong closed-field samarium-cobalt (Sm-Co) magnet fits onto the tooth surface. A metal keeper is attached to the tooth surface, which is usually into the root canal. The magnet is contained within the resin of the denture base. The alloy in the magnet produces a constant and strong magnetic force. Magnets are brittle and can corrode in the mouth unless protected by a stainless steel shield.

EXTRADENTAL ATTACHMENTS

This class of attachment devices may be divided into two groups:

1. *Cantilever (which can be rigid or mobile) – e.g. Ceka® and VKS (Bredent).*



Milled crowns with Ceka® attachments.

The VKS-SG is available in two sizes; 2.2mm and 1.7mm in diameter. They can be used in virtually any attachment case. A VKS-SG can be placed almost anywhere – on the buccal, lingual, distal or mesial of a bar or crown – and are excellent for cases with limited room.

Indications and Features:

- 10 levels of retention.
- Crown and Bridge mesial/distal.
- Crown and Bridge bar.
- Crown and Bridge unilateral.
- Limited vertical space.
- Mesial/distal of implant bar.
- One side of implant bars.
- For implant abutments.
- Laser welding.

2. *Bar attachment.*

CANTILEVER

The limits of the size of intradental attachments and a need to allow movement between the abutment crown and the denture base encouraged the need to develop joints that protruded from the surface of a cast crown and that were able to be cantilevered over the ridges.

Rigid

There is a need for a rigid connection between the parts, and movement can occur only along the path of insertion. The prosthesis becomes a rigid extension of the cantilever.

Mobile

The cantilever in the rigid attachment can produce undesirable forces on the gingival support of the abutment teeth. Therefore, attachments have evolved to allow rotation and resilience within the joints to reduce the torque on the teeth.

Rotational

Hinges allow rotation around a horizontal axis and transmit some forces to the residual ridge; an example is the Gerber hinge (CENDRES + METAUX – distributed by Sterngold). They can be used to attach a unilateral prosthesis to an abutment tooth.

The Dalbo® B attachment (CENDRES + METAUX – distributed by Sterngold) is an example of a ball and socket joint. The ball is cantilevered off the abutment tooth. The socket is attached to the prosthesis. The wall of the metal socket has small slits to provide a resilient entrance to the socket.

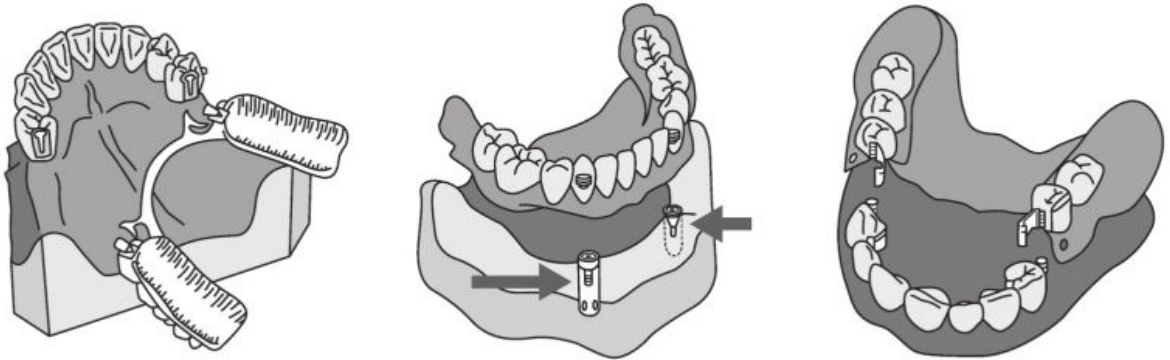
Resilient

The action of the Dalbo® ball and socket joint has been augmented by adding a spring within the body of the socket. This allows vertical “settling” of the denture next to the abutment teeth.

BAR ATTACHMENT

Bars connected to cast metal crowns or copings support and retain dentures. Cast custom-made bars can be made with a flat upper surface to support the prosthesis and have parallel sides that ensures stability. They can be obtained as a bar with an overlapping matrix. The Ackermann bar (CENDRES + METAUX – distributed by Sterngold) can follow the shape of the edentulous ridge. Several short matrices rest on the bar to attach the denture base.

The Hader Bar® is a semi-precision bar attachment. The minimum height of a Hader Bar® is 2.5mm. An oval cross-section has been used in the Dolder® Bar, which provides retention to a resilient matrix. It must be positioned in a straight line between the abutment teeth.



Precision attachments can be used in a variety of applications but are designed principally to minimise the load on abutment teeth and to support and stabilise overdentures.

Immediate Dentures

The immediate denture is a dental prosthesis constructed to replace the lost dentition, associated structures of the maxilla and mandible and inserted immediately following removal of some or all of the remaining teeth. Conventional immediate dentures require a series of appointments to perform the standard procedures; indeed, after the extraction of remaining teeth and any necessary adjunct surgery, the denture is placed, tested for areas of excessive pressure, and adjusted. (Gilboa, I. and Cardash, H.S., 2009).

Generally, two types of immediate dentures are described in the literature: conventional immediate dentures; and interim immediate dentures (Gooya, A., et al., 2013). In the traditional type, the interim prosthesis is fabricated to immediately place after the extraction of natural teeth and can be used as the definitive or long-term prosthesis. The interim type is used for a short time after tooth extraction. In addition, the interim immediate denture is used in order to preserve the aesthetics, mastication and occlusal support. Following healing, the immediate denture may be relined or replaced with a newly fabricated final denture. It was reported that the interim immediate dentures show numerous advantages including preservation of facial appearance and height, muscular tone, phonetic and reduction of post-extraction pain (Seals Jr, R.R., et al., 1996).

Treatment outcomes may not always be predictable as the prostheses cannot be completely assessed before issue (MacEntee, M.I. and Wyatt, C.C.L., 1999). One of the most important issues to be considered in immediate denture fabrication is the difficulty in assessing the Occlusal Vertical Dimension (OVD) and centric relation after extraction of the posterior teeth.

When a conventional complete denture is fabricated, there is generally a period from several weeks to months of edentulism for healing after teeth extraction (Bouma, L.O., et al., 2001).

Maintenance of the original OVD and centric relation is fundamental for the success of a total removable prosthesis. Select artificial teeth with the same cuspal inclination, which helps to match cuspal inclination with anterior and posterior guidance and make an acceptable occlusal scheme (Gooya, A., et al., 2013).

Full Acrylic Dentures/Flexible Dentures

ACRYLIC REMOVABLE DENTURES

Dentures that are press packed and heat cured have been the reliable standard for many years. Heat curing provides the maximum strength and fit. The most successful dentures emulate the natural form and function of teeth and suit the individual characteristics of a patient.

The widespread and growing acceptance of flexible partial dentures is primarily due to patient considerations: patients largely find them to be more comfortable, more aesthetic and easier to insert than metal-based partials. Flexible partial dentures are also useful for patients who may have acrylic or metal allergies or who would simply prefer a metal-free removable denture.

A clinical advantage of flexible partials is that they are minimally invasive: no tooth preparation or occlusal rest seats are required, which allows them to be easily and successfully incorporated as interim prostheses in implant treatment planning. Flexible partial dentures are contraindicated, however, when vertical clearance is limited to 4.0mm or when abutment teeth have minimal undercuts. The most common complaints about flexible partials have been that they are difficult to adjust, they may stain or develop odours over time, and teeth cannot be added after the initial denture is fabricated.

Comparison of Denture Base Materials

	Alloy	Acrylic	Flexible
Material Options	Co-Cr Titanium	Standard or High Impact	Duraflex™
Longevity	✓ ✓ ✓	✓ ✓	✓ ✓
Immediate Cases	✓ ✓ (some partial designs)	✓ ✓ ✓	Limited
Additions/Relines/ Repairs	✓ ✓ (Some)	✓ ✓ ✓	–
Retention	✓ ✓ ✓	✓	✓ ✓
Clasp Adjustment	✓ ✓ ✓	✓ ✓ ✓	Poor
Cost	High	Low	Medium
Thickness	Thin	Thick/medium	Medium
Comfort	✓ ✓ ✓	✓	✓ ✓ (✓ ✓ ✓ if unilateral)
Tensile Strength	Co-Cr 940 MPa Titanium 900 MPa	505 MPa	Less than 70 MPa
Dentition Status Required	High stability	Low stability	Highest stability
Tooth-Coloured Clasps	✓ ✓ (some)	✓ ✓ ✓	✓ ✓ ✓
Precision Attachments	✓ ✓ ✓	✓ (some)	Limited
Hygiene	✓ ✓ ✓	✓ ✓	✓
Aesthetics of Frame Materials	✓	✓ ✓	✓ ✓ ✓



BIBLIOGRAPHY



CHAPTER 1

American Dental Association Council on Scientific Affairs, 2006. The use of dental radiographs: update and recommendations. *The Journal of the American Dental Association*, 137(9), pp.1304-1312.

Anusavice, K.J., 1988. Conference report: Criteria for placement and replacement of dental restorations. *Journal of Dental Research*, 67(4), pp.795-796.

Arroyo, J.G., Bollain, I.G. and Esquiú, C.P., 2012. Multidisciplinary treatment plans in the adult patient—Step by step and rationale. *The European Journal of Aesthetic Dentistry*. Spring, pp.18-35.

Australian Dental Association 2018, *Professional information - Policies*, viewed 30 March 2017, <<https://www.ada.org.au/Professional-Information/Policies>>

Bain, C.A., 2004. Treatment planning in general dental practice: case presentation and communicating with the patient. *Dental update*, 31(2), pp.72-82

Boyce, R.A. and Klemons, G., 2015. Treatment planning for restorative implantology. *Dental Clinics*, 59(2), pp.291-304.

Christensen, G.J., 2003. Magnification in dentistry: useful tool or another gimmick?. *The Journal of the American Dental Association*, 134(12), pp.1647-1650.

Corbet, E.F. and Davies, W.I.R., 1993. The role of supragingival plaque in the control of progressive periodontal disease. *Journal of clinical periodontology*, 20(5), pp.307-313.

Featherstone, J.D., 1999. Prevention and reversal of dental caries: role of low level fluoride. *Community dentistry and oral epidemiology*, 27(1), pp.31-40.

Floyd, P., Palmer, P. and Palmer, R., 1999. Dental implants: Radiographic technique. *British dental journal*, 187(7), p.359.

Garavaglia, G., Mojon, P. and Belser, U., 2012. Modern treatment planning approach facing a failure of conventional treatment. Part I: Analysis of treatment options. *European Journal of Esthetic Dentistry*, 7(4).

Giddon, D.B., Donoff, R.B. and Guralnick, W.C., 2015. Interprofessional collaboration: opportunity for dentists to reinvent themselves as oral physicians. *Journal of the California Dental Association*, 43(2), p.63.

Go, A.S., Mozaffarian, D., Roger, V.L., Benjamin, E.J., Berry, J.D., Borden, W.B., Bravata, D.M., Dai, S., Ford, E.S., Fox, C.S. and Franco, S., 2013. Heart disease and stroke statistics—2013 update. *Circulation*, 127(1), pp.e6-e245.

Greenberg, B.L., Glick, M., Frantsve-Hawley, J. and Kantor, M.L., 2010. Dentists' attitudes toward chairside screening for medical conditions. *The Journal of the American Dental Association*, 141(1), pp.52-62.

Gurrea, J. and Bollain, I.G., 2016. Turning a Difficult Situation into a Routine Treatment. *Journal of Cosmetic Dentistry*, 32(3).

Harris, D., Horner, K., Gröndahl, K., Jacobs, R., Helmrot, E., Benic, G.I., Bornstein, M.M., Dawood, A. and Quirynen, M., 2012. EAO guidelines for the use of diagnostic imaging in implant dentistry 2011. A consensus workshop organized by the European Association for Osseointegration at the Medical University of Warsaw. *Clinical oral implants research*, 23(11), pp.1243-1253.

Hattab, F.N., Al-Momani, A.S., Yassin, O.M., Al-Omari, M.A.O., Hamasha, A.H., Rawashdeh, M.A. and Tavas, A., 1999. Crown diameters of deciduous teeth in Jordanians. *Dent Anthropol*, 13, pp.1-9.

Jung, R.E., Pjetursson, B.E., Glauser, R., Zembic, A., Zwahlen, M. and Lang, N.P., 2008. A systematic review of the 5-year survival and complication rates of implant-supported single crowns. *Clinical oral implants research*, 19(2), pp.119-130.

Kalsi, J.S. and Hemmings, K.W., 2013. The influence of patients' decisions on treatment planning in restorative dentistry. *Dental update*, 40(9), pp.698-710.

Lambrechts, P., Braem, M., Vuylsteke-Wauters, M. and Vanherle, G., 1989. Quantitative in vivo wear of human enamel. *Journal of Dental Research*, 68(12), pp.1752-1754.

Malamed, S.F., 2015. *Medical Emergencies in the Dental Office*, 7th Edition, Elsevier Mosby

Mehta, S.B., Banerji, S., Millar, B.J. and Suarez-Feito, J.M., 2012. Current concepts on the management of tooth wear: part 1. Assessment, treatment planning and strategies for the prevention and the passive management of tooth wear. *British dental journal*, 212(1), p.17.

Misch, C.E., 2007. *Contemporary implant dentistry*-E-Book. Elsevier Health Sciences.

Newsome, P., Smales, R. and Yip, K., 2012. Oral diagnosis and treatment planning: part 1. Introduction. *British dental journal*, 213(1), p.15.

Pjetursson, B.E., Tan, K., Lang, N.P., Brägger, U., Egger, M. and Zwahlen, M., 2004. A systematic review of the survival and complication rates of fixed partial dentures (FPDs) after an observation period of at least 5 years. *Clinical oral implants research*, 15(6), pp.625-642.

Ranjitkar, S., Smales, R.J. and Kaidonis, J.A., 2012. Oral manifestations of gastroesophageal reflux disease. *Journal of gastroenterology and hepatology*, 27(1), pp.21-27.

Sawhney, S., Kundabala, M., Shetty, N. and Thomas, M., 2014. Patient record and communication in interdisciplinary dentistry. *Journal of Interdisciplinary Dentistry*, 4(2), p.62.

Randow, K., Glantz, P.O. and Zöger, B.O., 1986. Technical failures and some related clinical complications in extensive fixed prosthodontics: an epidemiological study of long-term clinical quality. *Acta Odontologica Scandinavica*, 44(4), pp.241-255.

Wong, R., Ng, S.K., Corbet, E.F. and Keung Leung, W., 2012. Non-surgical periodontal therapy improves oral health-related quality of life. *Journal of clinical periodontology*, 39(1), pp.53-61.

Yanase, R.T. and Le, H.H., 2014. Caries Management by Risk Assessment Care Paths for Prosthodontic Patients: Oral Microbial Control and Management. *Dental Clinics*, 58(1), pp.227-245.

Yip, K. and Smales, R., 2012. Oral diagnosis and treatment planning: part 2. Dental caries and assessment of risk. *British dental journal*, 213(2), p.59.

CHAPTER 2

Aarab, G., Lobbezoo, F., Heymans, M.W., Hamburger, H.L. and Naeije, M., 2011. Long-term follow-up of a randomized controlled trial of oral appliance therapy in obstructive sleep apnea. *Respiration*, 82(2), pp.162-168.

Andrén, A., Sjöquist, M. and Tegelberg, Å., 2009. Effects on blood pressure after treatment of obstructive sleep apnoea with a mandibular advancement appliance—a three-year follow-up. *Journal of oral rehabilitation*, 36(10), pp.719-725.

Bailey, D.R. and Attanasio, R., 2012. The history of sleep medicine. *Dental Clinics*, 56(2), pp.313-317.

Baker, B.H., 2015. Xerostomia – an update. Part 1. *Australasian Dentist*, March - April, pp. 54-58

Baker, B.H., 2015. Xerostomia – an update. Part 2. *Australasian Dentist*, May - June, pp. 46-49

- Baker, J.S. and Nolan, P.J., 2017. Effectiveness of botulinum toxin type A for the treatment of chronic masticatory myofascial pain: A case series. *The Journal of the American Dental Association*, 148(1), pp.33-39.
- Balasubramaniam, R., Klasser, G.D., Cistulli, P.A. and Lavigne, G.J., 2014. The link between sleep bruxism, sleep disordered breathing and temporomandibular disorders: an evidence-based review. *J Dent Sleep Med*, 1(1), pp.27-37.
- Bartold, P.M., Shi, S. and Gronthos, S., 2006. Stem cells and periodontal regeneration. *Periodontology 2000*, 40(1), pp.164-172.
- Bretz, W.A., Loesche, W.J., Chen, Y.M., Schork, M.A., Dominguez, B.L. and Grossman, N., 2000. Minor salivary gland secretion in the elderly. *Oral Surgery, Oral Medicine, Oral Pathology, Oral Radiology, and Endodontics*, 89(6), pp.696-701.
- Dawes, C., 1987. Physiological factors affecting salivary flow rate, oral sugar clearance, and the sensation of dry mouth in man. *Journal of dental research*, 66(1_ suppl), pp.648-653.
- Deng, G., Hou, B.L., Holodny, A.I. and Cassileth, B.R., 2008. Functional magnetic resonance imaging (fMRI) changes and saliva production associated with acupuncture at LI-2 acupuncture point: a randomized controlled study. *BMC complementary and alternative medicine*, 8(1), p.37.
- Doff, M.H., Veldhuis, S.K., Hoekema, A., Slater, J.J., Wijkstra, P.J. and de Bont, L.G., Long-term oral appliance therapy in obstructive sleep apnea syndrome: a controlled study on temporomandibular side effects. *Clin Oral Investig*. 2012; 16 (3): 689-97.
- de Almeida, F.R., Lowe, A.A., Tsuiki, S., Otsuka, R., Wong, M. and Fastlicht, S., 2005. Long-term compliance and side effects of oral appliances used for the treatment of snoring and obstructive sleep apnea syndrome. *Journal of Clinical Sleep Medicine*, 1(02), pp.143-152.
- Ferguson, K.A., Cartwright, R., Rogers, R. and Schmidt-Nowara, W., 2006. Oral appliances for snoring and obstructive sleep apnea: a review. *Sleep*, 29(2), pp.244-262.
- Fleury, B., Rakotonanahary, D., Petelle, B., Vincent, G., Fleury, N.P., Meyer, B. and Lebeau, B., 2004. Mandibular advancement titration for obstructive sleep apnea: optimization of the procedure by combining clinical and oximetric parameters. *Chest*, 125(5), pp.1761-1767.
- Fox, P.C. and Eversole, R., 2001. Diseases of the salivary glands. *Essentials of oral medicine*, pp.260-76.
- Fox, R.I. and Liu, A.Y., 2006. Sjögren's syndrome in dermatology. *Clinics in dermatology*, 24(5), pp.393-413.
- Gagnadoux, F., Fleury, B., Vielle, B., Pételle, B., Meslier, N., N'Guyen, X.L., Trzepizur, W. and Racineux, J.L., 2009. Titrated mandibular advancement versus positive airway pressure for sleep apnoea. *European Respiratory Journal*, 34(4), pp.914-920.
- Ghezzi, E.M., Lange, L.A. and Ship, J.A., 2000. Determination of variation of stimulated salivary flow rates. *Journal of dental research*, 79(11), pp.1874-1878.
- Giannasi, L.C., Almeida, F.R., Magini, M., Costa, M.S., de Oliveira, C.S., de Oliveira, J.C.M., Bussadori, S.K. and de Oliveira, L.V.F., 2009. Systematic assessment of the impact of oral appliance therapy on the temporomandibular joint during treatment of obstructive sleep apnea: long-term evaluation. *Sleep and Breathing*, 13(4), pp.375-381.
- Guggenheimer, J. and Moore, P.A., 2003. Xerostomia: etiology, recognition and treatment. *The Journal of the American Dental Association*, 134(1), pp.61-69.
- Hammond, R.J., Gotsopoulos, H., Shen, G., Petocz, P., Cistulli, P.A. and Darendeliler, M.A., 2007. A follow-up study of dental and skeletal changes associated with mandibular advancement splint use in obstructive sleep apnea. *American Journal of Orthodontics and Dentofacial Orthopedics*, 132(6), pp.806-814.
- Itzhaki, S., Dorchin, H., Clark, G., Lavie, L., Lavie, P. and Pillar, G., 2007. The effects of 1-year treatment with a Herbst mandibular advancement splint on obstructive sleep apnea, oxidative stress, and endothelial function. *Chest*, 131(3), pp.740-749.
- Johal, A., Battagel, J. and Hector, M., 2011. Controlled, prospective trial of psychosocial function before and after mandibular advancement splint therapy. *American Journal of Orthodontics and Dentofacial Orthopedics*, 139(5), pp.581-587.

Bibliography

- Kassan, S.S. and Moutsopoulos, H.M., 2004. Clinical manifestations and early diagnosis of Sjögren syndrome. *Archives of internal medicine*, 164(12), pp.1275-1284.
- Kato, J., Isono, S., Tanaka, A., Watanabe, T., Araki, D., Tanzawa, H. and Nishino, T., 2000. Dose-dependent effects of mandibular advancement on pharyngeal mechanics and nocturnal oxygenation in patients with sleep-disordered breathing. *Chest*, 117(4), pp.1065-1072.
- Kotiranta, U., Suvinen, T. and Forssell, H., 2014. Tailored treatments in temporomandibular disorders: where are we now? A systematic qualitative literature review. *Journal of Oral & Facial Pain & Headache*, 28(1).
- Lafaurie, G., Fedele, S., López, R.M., Wolff, A., Strietzel, F., Porter, S.R. and Konttinen, Y.T., 2009. Biotechnological advances in neuro-electro-stimulation for the treatment of hyposalivation and xerostomia. *Med Oral Patol Oral Cir Bucal*, 14(2), pp.E76-80.
- Lavery, D., Szollosi, I., Czyniewski, S., Beer, F. and Hart, C., 2016, October. EFFECTS OF A NOVEL MANDIBULAR ADVANCEMENT DEVICE ON AHI AND SNORING IN PATIENTS WITH OBSTRUCTIVE SLEEP APNOEA: A PILOT STUDY. In *JOURNAL OF SLEEP RESEARCH* (Vol. 25, pp. 50-50). 111 RIVER ST, HOBOKEN 07030-5774, NJ USA: WILEY-BLACKWELL.
- Lim, J., Lasserson, T.J., Fleetham, J. and Wright, J.J., 2006. Oral appliances for obstructive sleep apnoea. *The Cochrane Library*.
- Lobbezoo, F. and Lavigne, G.J., 1997. Do bruxism and temporomandibular disorders have a cause-and-effect relationship?. *Journal of orofacial pain*, 11(1).
- Malladi, A.S., Sack, K.E., Shiboski, S.C., Shiboski, C.H., Baer, A.N., Banushree, R., Dong, Y., Helin, P., Kirkham, B.W., Li, M. and Sugai, S., 2012. Primary Sjögren's syndrome as a systemic disease: a study of participants enrolled in an international Sjögren's syndrome registry. *Arthritis care & research*, 64(6), pp.911-918.
- Manfredini, D., Cocilovo, F., Favero, L., Ferronato, G., Tonello, S. and Guarda-Nardini, L., 2011. Surface electromyography of jaw muscles and kinesiographic recordings: diagnostic accuracy for myofascial pain. *Journal of oral rehabilitation*, 38(11), pp.791-799.
- Martínez-Gomis, J., Willaert, E., Nogues, L., Pascual, M., Somoza, M. and Monasterio, C., 2010. Five years of sleep apnea treatment with a mandibular advancement device: side effects and technical complications. *The Angle Orthodontist*, 80(1), pp.30-36.
- O'Sullivan, E.M. and Higginson, I.J., 2010. Clinical effectiveness and safety of acupuncture in the treatment of irradiation-induced xerostomia in patients with head and neck cancer: a systematic review. *Acupuncture in Medicine*, 28(4), pp.191-199.
- Pliska, B.T. and Almeida, F., 2012. Effectiveness and outcome of oral appliance therapy. *Dental Clinics*, 56(2), pp.433-444.
- Ramar, K., Dort, L.C., Katz, S.G., Lettieri, C.J., Harrod, C.G., Thomas, S.M. and Chervin, R.D., 2015. Clinical practice guideline for the treatment of obstructive sleep apnea and snoring with oral appliance therapy: an update for 2015: an American Academy of Sleep Medicine and American Academy of Dental Sleep Medicine clinical practice guideline. *Journal of clinical sleep medicine: JCSM: official publication of the American Academy of Sleep Medicine*, 11(7), p.773.
- Reilich, P., Fheodoroff, K., Kern, U., Mense, S., Seddigh, S., Wissel, J. and Pongratz, D., 2004. Consensus statement: botulinum toxin in myofascial pain. *Journal of neurology*, 251, pp.i36-i38.
- Sutherland, K., Vanderveken, O.M., Tsuda, H., Marklund, M., Gagnadoux, F., Kushida, C.A. and Cistulli, P.A., 2014. Oral appliance treatment for obstructive sleep apnea: an update. *Journal of clinical sleep medicine: JCSM: official publication of the American Academy of Sleep Medicine*, 10(2), p.215.
- Sutherland, K., Phillips, C.L., Davies, A., Srinivasan, V.K., Dalci, O., Yee, B.J., Darendeliler, M.A., Grunstein, R.R. and Cistulli, P.A., 2014. CPAP pressure for prediction of oral appliance treatment response in obstructive sleep apnea. *Journal of clinical sleep medicine: JCSM: official publication of the American Academy of Sleep Medicine*, 10(9), p.943.
- Tasali, E., Leproult, R., Ehrmann, D.A. and Van Cauter, E., 2008. Slow-wave sleep and the risk of type 2 diabetes in humans. *Proceedings of the National Academy of Sciences*, 105(3), pp.1044-1049.

Vissink, A., Mitchell, J.B., Baum, B.J., Limesand, K.H., Jensen, S.B., Fox, P.C., Elting, L.S., Langendijk, J.A., Coppes, R.P. and Reylund, M.E., 2010. Clinical management of salivary gland hypofunction and xerostomia in head-and-neck cancer patients: successes and barriers. *International Journal of Radiation Oncology • Biology • Physics*, 78(4), pp.983-991.

Vissink, A., Luijk, P., Langendijk, J.A. and Coppes, R.P., 2015. Current ideas to reduce or salvage radiation damage to salivary glands. *Oral diseases*, 21(1).

Walker-Engström, M.L., Ringqvist, I., Vestling, O., Wilhelmsson, B. and Tegelberg, Å., 2003. A prospective randomized study comparing two different degrees of mandibular advancement with a dental appliance in treatment of severe obstructive sleep apnea. *Sleep and Breathing*, 7(03), pp.119-130.

Wolff, M. and Kleinberg, I., 1998. Oral mucosal wetness in hypo-and normosalivators. *Archives of oral biology*, 43(6), pp.455-462.

Yoshida, K., 2006. Effect on blood pressure of oral appliance therapy for sleep apnea syndrome. *International Journal of Prosthodontics*, 19(1).

CHAPTER 3

Ahlholm, P., Sipilä, K., Vallittu, P., Jakonen, M. and Kotiranta, U., 2016. Digital versus conventional impressions in fixed prosthodontics: a review. *Journal of Prosthodontics*.

Chochlidakis, K.M., Papaspyridakos, P., Geminiani, A., Chen, C.J., Feng, I.J. and Ercoli, C., 2016. Digital versus conventional impressions for fixed prosthodontics: a systematic review and meta-analysis. *Journal of Prosthetic Dentistry*, 116(2), pp.184-190.

Hack, G.D., Bloom, I.T. and Patzelt, S., 2015. Digital impressions. In *Clinical Applications of Digital Dental Technology* (pp. 27-40). John Wiley & Sons, Inc.

Renne, W., McGill, S.T., Forshee, K.V., DeFee, M.R. and Mennito, A.S., 2012. Predicting marginal fit of CAD/CAM crowns based on the presence or absence of common preparation errors. *Journal of Prosthetic Dentistry*, 108(5), pp.310-315.

Schoenbaum, T.R., 2012. Dentistry in the digital age: an update. *Dentistry today*, 31(2), pp.108-110.

Seitz, S.D. and Zimmermann, R.L., 2017. Digital Impressions. In *The Dental Reference Manual* (pp. 177-182). Springer, Cham.

Su, T.S. and Sun, J., 2016. Comparison of marginal and internal fit of 3-unit ceramic fixed dental prostheses made with either a conventional or digital impression. *Journal of Prosthetic Dentistry*, 116(3), pp.362-367.

Weston, J., 2016. Closing the Gap Between Esthetics and Digital Dentistry. *Compendium of continuing education in dentistry (Jamesburg, NJ: 1995)*, 37(2), pp.84-91.

CHAPTER 4

Ali, Z., Ashley, M. and West, C., 2013. Factors to consider when treatment planning for patients seeking comprehensive aesthetic dental treatment. *Dental update*, 40(7), pp.526-533.

Barzilay, I. and Myers, M.L., 1987. The dual-arch impression. *Quintessence Int*, 18(4), pp.293-5.

Castellanos, M. and Echeto, L.F., 2017. Removable Partial Dentures (RPD) Treatment: A Clinical Guide. In *The Dental Reference Manual* (pp. 129-145). Springer, Cham.

- Chu, F.C., Siu, A.S., Newsome, P.R., Chow, T.W. and Smales, R.J., 2002. Restorative management of the worn dentition: 4. Generalized toothwear. *Dent update*, 29(7), pp.318-24.
- Cox, J.R., Brandt, R.L. and Hughes, H.J., 2002. A clinical pilot study of the dimensional accuracy of double-arch and complete-arch impressions. *Journal of Prosthetic Dentistry*, 87(5), pp.510-515.
- Goodlin, R., 2011. Photographic-assisted diagnosis and treatment planning. *Dental Clinics*, 55(2), pp.211-227.
- Greenberg, J.R. and Bogert, M.C., 2010. A dental esthetic checklist for treatment planning in esthetic dentistry. *Compendium*, 31(8).
- Kaplowitz, G.J., 1997. Trouble-shooting dual arch impressions II. *The Journal of the American Dental Association*, 128(9), pp.1277-1281.
- Parker, M.H., Cameron, S.M., Hughbanks, J.C. and Reid, D.E., 1997. Comparison of occlusal contacts in maximum intercuspation for two impression techniques. *Journal of Prosthetic Dentistry*, 78(3), pp.255-259.
- Shillingburg, H.T., Sather, D.A., Wilson, E.L., Cain, J.R., Mitchell, D.L., Blanco, L.J. and Kessler, J.C., 2012. *Fundamentals of fixed prosthodontics* (pp. 149-163). Quintessence Publishing Company
- Seitz, S.D. and Zimmermann, R.L., 2017. Digital Impressions. In *The Dental Reference Manual* (pp. 177-182). Springer, Cham.
- WANG, Y.L., Cheng, J., CHEN, Y.M., YIP, K.K., Smales, R.J. and YIN, X.M., 2011. Patterns and forces of occlusal contacts during lateral excursions recorded by the T-Scan II system in young Chinese adults with normal occlusions. *Journal of oral rehabilitation*, 38(8), pp.571-578.
- Weinstein, G.M. and Zientz, M.T., 2017. *The dental reference manual*. Springer,.
- Weston, J.F. and Haupt, E., 2011. Creating aesthetic success through proper clinician and laboratory technical communication. *Dental Clinics*, 55(2), pp.371-382.

CHAPTER 5

- Asmussen, E., Peutzfeldt, A. and Heitmann, T., 1999. Stiffness, elastic limit, and strength of newer types of endodontic posts. *Journal of dentistry*, 27(4), pp.275-278.
- Barone, A., Derchi, G., Rossi, A., Marconcini, S. and Covani, U., 2008. Longitudinal clinical evaluation of bonded composite inlays: A 3-year study. *Quintessence International*, 39(1).
- Brackett, M.G., Dib, A., Brackett, W.W., Estrada, B.E. and Reyes, A.A., 2002. One-year clinical performance of a resin-modified glass ionomer and a resin composite restorative material in unprepared Class V restorations. *Operative dentistry*, 27(2), pp.112-116.
- Cavalcanti, A.N., Foxton, R.M., Watson, T.F., Oliveira, M.T., Giannini, M. and Marchi, G.M., 2009. Bond strength of resin cements to a zirconia ceramic with different surface treatments. *Operative dentistry*, 34(3), pp.280-287.
- Donovan, T.E., 2006. Longevity of the tooth/restoration complex: a review. *Journal of the California Dental Association*, 34(2), pp.122-128.
- Gerdolle, D.A., Mortier, E., Loos-Ayav, C., Jacquot, B. and Panighi, M.M., 2005. In vitro evaluation of microleakage of indirect composite inlays cemented with four luting agents. *Journal of Prosthetic Dentistry*, 93(6), pp.563-570
- Goracci, C. and Ferrari, M., 2011. Current perspectives on post systems: a literature review. *Australian Dental Journal*, 56(s1), pp.77-83.
- Grossman, D.G., 1985. Cast glass ceramics. *Dental Clinics of North America*, 29(4), pp.725-739.

Haywood, V.B., Heymann, H.O. and Scurria, M.S., 1989. Effects of water, speed, and experimental instrumentation on finishing and polishing porcelain intra-orally. *Dental Materials*, 5(3), pp.185-188.

Isidor, F., Brøndum, K. and Ravnholt, G., 1999. The influence of post length and crown ferrule length on the resistance to cyclic loading of bovine teeth with prefabricated titanium posts. *International Journal of Prosthodontics*, 12(1).

Jovanovski, S., Popovski, J., Dakskobler, A., Marion, L. and Jevnikar, P., 2017. The influence of crown ferrule on fracture resistance of endodontically treated maxillary central incisors. *Balkan Journal of Dental Medicine*, 21(1), pp.44-49.

Mannocci, F., Sherriff, M., Watson, T.F. and Vallittu, P.K., 2005. Penetration of bonding resins into fibre-reinforced composite posts: A confocal microscopic study. *International endodontic journal*, 38(1), pp.46-51.

Solow, R.A., 2016. Esthetic, conservative, cast gold restorations for posterior teeth. *General dentistry*, 64(5), pp.14-19.

Vaderhobli, R.M., 2011. Advances in dental materials. *Dental Clinics*, 55(3), pp.619-625.

Wataha, J.C., 2002. Alloys for prosthodontic restorations. *The Journal of Prosthetic Dentistry*, 87(4), pp.351-363.

Wohlwend, A., Ivoclar Ag, 1998. *Method for manufacturing dental crowns*. U.S. Patent 5,788,498.

CHAPTER 6

Abouts, Y.E., 1998. Removing saliva contamination from porcelain veneers before bonding. *Journal of Prosthetic Dentistry*, 80(6), pp.649-653.

Alex, G., 2008. CE 1-Preparing Porcelain Surfaces for Optimal Bonding. *Compendium*, 29(6), p.324.

Blatz, M.B., Sadan, A. and Kern, M., 2003. Resin-ceramic bonding: a review of the literature. *Journal of Prosthetic Dentistry*, 89(3), pp.268-274.

Brännström, M., 1992. Etiology of dentin hypersensitivity. Proceedings of the Finnish Dental Society. *Suomen Hammaslaakariseuran toimituksia*, 88, pp.7-13.

Bloom, D.R. and Padayachy, J.N., 2006. Smile lifts—A functional and aesthetic perspective. *British dental journal*, 200(4), p.199.

Cardash, H.S., Baharav, H., Pilo, R. and Ben-Amar, A., 1993. The effect of porcelain color on the hardness of luting composite resin cement. *The Journal of prosthetic dentistry*, 69(6), pp.620-623.

Cherukara, G.P., Davis, G.R., Seymour, K.G., Zou, L. and Samarawickrama, D.Y., 2005. Dentin exposure in tooth preparations for porcelain veneers: a pilot study. *Journal of Prosthetic Dentistry*, 94(5), pp.414-420.

Christensen, G.J. and Christensen, R.P., 1991. Clinical Observations of Porcelain Veneers: A Three-Year Report. *Journal of Esthetic and Restorative Dentistry*, 3(5), pp.174-179.

Coachman, C. and Calamita, M.A., 2014. VIRTUAL Esthetic Smile Design. *Journal of Cosmetic Dentistry*, 29(4).

Dietschi, D., 2005. Bright and white: is it always right?. *Journal of Esthetic and Restorative Dentistry*, 17(3), pp.183-190.

Feuerstein, O., Matalon, S., Slutzky, H. and Weiss, E.I., 2007. Antibacterial properties of self-etching dental adhesive systems. *The Journal of the American Dental Association*, 138(3), pp.349-354.

Fradeani, M., Redemagni, M. and Corrado, M., 2005. Porcelain laminate veneers: 6-to 12-year clinical evaluation--a retrospective study. *International Journal of Periodontics & Restorative Dentistry*, 25(1).

Friedman, M.J., 2001. Masters of esthetic dentistry: Porcelain veneer restorations: A clinician's opinion about a disturbing trend. *Journal of Esthetic and Restorative Dentistry*, 13(5), p.318.

Bibliography

- Goldstein, R.E., 1989. Finishing of composites and laminates. *Dental Clinics of North America*, 33(2), pp.305-18.
- Gürel, G. and Gürel, G., 2003. *The science and art of porcelain laminate veneers* (pp. 369-390). London: Quintessence.
- Haywood, V.B., Heymann, H.O., Kusy, R.P., Whitley, J.Q. and Andreaus, S.B., 1988. Polishing porcelain veneers: an SEM and specular reflectance analysis. *Dental Materials*, 4(3), pp.116-121.
- Highton, R.M., Caputo, A.A. and Matyas, J., 1979. Effectiveness of porcelain repair systems. *Journal of Prosthetic Dentistry*, 42(3), pp.292-294.
- Javaheri, D., 2007. Considerations for planning esthetic treatment with veneers involving no or minimal preparation. *The journal of the American dental Association*, 138(3), pp.331-337.
- Layton, D. and Walton, T., 2007. An up to 16-year prospective study of 304 porcelain veneers. *International Journal of Prosthodontics*, 20(4), p.389.
- Linden, J.J., Swift Jr, E.J., Boyer, D.B. and Davis, B.K., 1991. Photo-activation of resin cements through porcelain veneers. *Journal of dental research*, 70(2), pp.154-157.
- Magne, P. and Belser, U.C., 2004. Novel porcelain laminate preparation approach driven by a diagnostic mock-up. *Journal of Esthetic and restorative dentistry*, 16(1), pp.7-16.
- Mandikos, M.N., 1998. Polyvinyl siloxane impression materials: an update on clinical use. *Australian dental journal*, 43(6), pp.428-434.
- McLaren, E.A. and Culp, L., 2013. Smile analysis. *J Cosmet Dent*, 29(1), pp.94-108.
- Meereis, C.T.W., de Souza, G.B.F., Albino, L.G.B., Ogliari, F.A., Piva, E. and Lima, G.S., 2016. Digital smile design for computer-assisted esthetic rehabilitation: two-year follow-up. *Operative Dentistry*, 41(1), pp.E13-E22.
- Mizrahi, B., 2005. Visualization before finalization: a predictable procedure for porcelain laminate veneers. *Practical procedures & aesthetic dentistry: PPAD*, 17(8), pp.513-8.
- Newsome, P., Smales, R. and Yip, K., 2012. Oral diagnosis and treatment planning: part 1. Introduction. *British dental journal*, 213(1), pp.15.
- Nicholls, J.I., 1988. Tensile bond of resin cements to porcelain veneers. *Journal of Prosthetic Dentistry*, 60(4), pp.443-447.
- O'Keefe, K.L., Pinzon, L.M., Rivera, B. and Powers, J.M., 2005. Bond strength of composite to astringent-contaminated dentin using self-etching adhesives. *American journal of dentistry*, 18(3), pp.168-172.
- Olgart, L., Brännström, M. and Johnson, G., 1974. Invasion of bacteria into dentinal tubules Experiments in vivo and in vitro. *Acta Odontologica Scandinavica*, 32(1), pp.61-70.
- Ostler, L. n.d., *The 21 Principles of Smile Design – Your Guide to a More Attractive Confident Smile*, The Center for Dental Health, viewed 23 March 2017, < <http://centerfordentalhealth.com/wp-content/uploads/2015/06/21-Principles-of-Smile-Design.pdf> >
- Paul, S.J. and Schärer, P., 1997. The dual bonding technique: A modified method to improve adhesive luting procedures. *International Journal of Periodontics & Restorative Dentistry*, 17(6).
- Perdigão, J., Duarte Jr, S. and Lopes, M.M., 2003. Advances in dentin adhesion. *Compendium of continuing education in dentistry (Jamesburg, NJ: 1995)*, 24(8 Suppl), pp.10-6.
- Peumans, M., Van Meerbeek, B., Lambrechts, P., Vuylsteke-Wauters, M. and Vanherle, G., 1998. Five-year clinical performance of porcelain veneers. *Quintessence international*, 29(4).
- Priest, G., 2004. Proximal margin modifications for all-ceramic veneers. *Practical procedures & aesthetic dentistry: PPAD*, 16(4), pp.265-72.

Shillingburg, H.T., Sather, D.A., Wilson, E.L., Cain, J.R., Mitchell, D.L., Blanco, L.J. and Kessler, J.C., 2012. *Fundamentals of fixed prosthodontics* (pp. 149-163). Quintessence Publishing Company.

Smales, R.J. and Etemadi, S., 2004. Long-term survival of porcelain laminate veneers using two preparation designs: a retrospective study. *International Journal of Prosthodontics*, 17(3).

Van Meerbeek, B., Perdigao, J., Lambrechts, P. and Vanherle, G., 1998. The clinical performance of adhesives. *Journal of dentistry*, 26(1), pp.1-20.

Walls, A.W., 1995. The use of adhesively retained all-porcelain veneers during the management of fractured and worn anterior teeth: Part 2. Clinical results after 5 years of follow-up. *British dental journal*, 178(9), pp.337-340.

Weston, J., 2016. Closing the Gap Between Esthetics and Digital Dentistry. *Compendium of continuing education in dentistry (Jamesburg, NJ: 1995)*, 37(2), pp.84-91.

CHAPTER 7

Annerstedt, A.L., Engström, U., Hansson, A., Jansson, T., Karlsson, S., Liljhagen, H., Lindquist, E., Rydhammar, E., Tyreman-Bandhede, M., Svensson, P. and Wandel, U., 1996. Axial wall convergence of full veneer crown preparations Documented for dental students and general practitioners. *Acta Odontologica Scandinavica*, 54(2), pp.109-112.

Barone, A., Derchi, G., Rossi, A., Marconcini, S. and Covani, U., 2008. Longitudinal clinical evaluation of bonded composite inlays: A 3-year study. *Quintessence International*, 39(1).

Brackett, M.G., Dib, A., Brackett, W.W., Estrada, B.E. and Reyes, A.A., 2002. One-year clinical performance of a resin-modified glass ionomer and a resin composite restorative material in unprepared Class V restorations. *Operative dentistry*, 27(2), pp.112-116.

Bra, M. and Nyborg, H., 1974. Bacterial growth and pulpal changes under inlays cemented with zinc phosphate cement and EpoxyLite CBA 9080. *Journal of Prosthetic Dentistry*, 31(5), pp.556-565.

Christensen, G.J., 2010. Why use resin cements?. *Journal (Indiana Dental Association)*, 89(3), pp.6-8.

Gerdolle, D.A., Mortier, E., Loos-Ayav, C., Jacquot, B. and Panighi, M.M., 2005. In vitro evaluation of microleakage of indirect composite inlays cemented with four luting agents. *Journal of Prosthetic Dentistry*, 93(6), pp.563-570

Haywood, V.B., Heymann, H.O. and Scurria, M.S., 1989. Effects of water, speed, and experimental instrumentation on finishing and polishing porcelain intra-orally. *Dental Materials*, 5(3), pp.185-188.

Karl, M., Taylor, T.D., Wichmann, M.G. and Heckmann, S.M., 2006. In Vivo Stress Behavior in Cemented and Screw-Retained Five-Unit Implant FPDs. *Journal of Prosthodontics*, 15(1), pp.20-24.

Kent, W.A., Shillingburg Jr, H.T. and Duncanson Jr, M.G., 1988. Taper of clinical preparations for cast restorations. *Quintessence international (Berlin, Germany: 1985)*, 19(5), pp.339-345.

MACK, P.J., 1980. A theoretical and clinical investigation into the taper achieved on crown and inlay preparations. *Journal of oral rehabilitation*, 7(3), pp.255-265.

Magne, P., 2005. Immediate dentin sealing: a fundamental procedure for indirect bonded restorations. *Journal of Esthetic and Restorative Dentistry*, 17(3), pp.144-154.

Matinlinna, J.P. and Vallittu, P.K., 2007. Bonding of resin composites to etchable ceramic surfaces—an insight review of the chemical aspects on surface conditioning. *Journal of oral rehabilitation*, 34(8), pp.622-630.

Mitchell, C.A., Abbariki, M. and Orr, J.F., 2000. The influence of luting cement on the probabilities of survival and modes of failure of cast full-coverage crowns. *Dental Materials*, 16(3), pp.198-206.

Nordlander, J., Weir, D., Stoffer, W. and Ochi, S., 1988. The taper of clinical preparations for fixed prosthodontics. *Journal of Prosthetic Dentistry*, 60(2), pp.148-151.

Paul, S.J. and Schärer, P., 1997. The dual bonding technique: A modified method to improve adhesive luting procedures. *International Journal of Periodontics & Restorative Dentistry*, 17(6).

Pjetursson, B.P., et al., 2008):

Proos, K.A., Swain, M.V., Ironside, J. and Steven, G.P., 2003. Influence of margin design and taper abutment angle on a restored crown of a first premolar using finite element analysis. *International Journal of Prosthodontics*, 16(4).

Rosenstiel, S.F., Land, M.F. and Fujimoto, J., 2016. Color science, esthetic and shade selection. In *Contemporary fixed prosthodontics* (pp. 624-626). Elsevier, St. Louis.

Shillingburg, H.T., Sather, D.A., Wilson, E.L., Cain, J.R., Mitchell, D.L., Blanco, L.J. and Kessler, J.C., 2012. *Fundamentals of fixed prosthodontics* (pp. 149-163). Quintessence Publishing Company.

Smith, D.C., 1968. A new dental cement. *British Dental Journal*, 124(9), pp.381-384.

Swift, E.J., 2002. Dentin/enamel adhesives: review of the literature. *Pediatric dentistry*, 24(5), pp.456-461.

VALDERHAUGW, J. and Birkeland, J.M., 1976. Periodontal conditions in patients 5 years following insertion of fixed prostheses. *Journal of oral rehabilitation*, 3(3), pp.237-243.

Wilson, A.D., 1972. A new translucent cement for dentistry: the glass-ionomer cement. *Br Dent J*, 132, pp.133-135.

Woolsey, G.D. and Matich, J.A., 1978. The effect of axial grooves on the resistance form of cast restorations. *The Journal of the American Dental Association*, 97(6), pp.978-980.

Zidan, O. and Ferguson, G.C., 2003. The retention of complete crowns prepared with three different tapers and luted with four different cements. *Journal of Prosthetic Dentistry*, 89(6), pp.565-571.

CHAPTER 8

Abi Nader, S., De Souza, R.F., Fortin, D., Fromentin, O. and ALBUQUERQUE JUNIOR, R.F., 2011. Effect of simulated masticatory loading on the retention of stud attachments for implant overdentures. *Journal of oral rehabilitation*, 38(3), pp. 157-164.

Almasri, R., Drago, C.J., Siegel, S.C. and Hardigan, P.C., 2011. Volumetric misfit in CAD/CAM and cast implant frameworks: a university laboratory study. *Journal of Prosthodontics*, 20(4), pp.267-274.

American Dental Association Council on Scientific Affairs, 2012. The use of cone-beam computed tomography in dentistry: an advisory statement from the American Dental Association Council on Scientific Affairs. *The Journal of the American Dental Association*, 143(8), pp.899-902.

Angelopoulos, C. and Aghaloo, T., 2011. Imaging technology in implant diagnosis. *Dental Clinics*, 55(1), pp.141-158.

Baker, B.H., 2016. Treatment Considerations for Implant Restoration of the Edentulous Patient. *Implant Dentistry Today*, July - August, pp. 12-16.

Bergenblock, S., Andersson, B., Fürst, B. and Jemt, T., 2012. Long-Term Follow-Up of CeraOne™ Single-Implant Restorations: An 18-Year Follow-Up Study Based on a Prospective Patient Cohort. *Clinical implant dentistry and related research*, 14(4), pp.471-479.

Boyce, R.A. and Klemons, G., 2015. Treatment planning for restorative implantology. *Dental Clinics*, 59(2), pp.291-304.

Bryant, S.R., MacDonald-Jankowski, D. and Kim, K., 2007. Does the type of implant prosthesis affect outcomes for the completely edentulous arch? *International Journal of Oral & Maxillofacial Implants*, 22(7).

Burbano, M., Wilson Jr, T.G., Valderrama, P., Blansett, J., Wadhvani, C.P., Choudhary, P.K., Rodriguez, L.C. and Rodrigues, D.C., 2015. Characterization of Cement Particles Found in Peri-implantitis-Affected Human Biopsy Specimens. *International Journal of Oral & Maxillofacial Implants*, 30(5).

Cha, H.S., Kim, Y.S., Jeon, J.H. and Lee, J.H., 2013. Cumulative survival rate and complication rates of single-tooth implant; focused on the coronal fracture of fixture in the internal connection implant. *Journal of oral rehabilitation*, 40(8), pp.595-602.

Chaar, M.S., Att, W. and Strub, J.R., 2011. Prosthetic outcome of cement-retained implant-supported fixed dental restorations: a systematic review. *Journal of oral rehabilitation*, 38(9), pp.697-711.

Christman, A., Schrader, S., John, V., Zunt, S., Maupome, G. and Prakasam, S., 2014. Designing a safety checklist for dental implant placement: a Delphi study. *The Journal of the American Dental Association*, 145(2), pp.131-140.

Cooper, L.F., 2008. Objective criteria: guiding and evaluating dental implant esthetics. *Journal of Esthetic and Restorative Dentistry*, 20(3), pp.195-205.

Cooper, L.F. and Pin-Harry, O.C., 2013. "Rules of Six"—Diagnostic and Therapeutic Guidelines for Single-Tooth Implant Success. *Compend Contin Educ Dent*, 34(2), pp.94-98.

Drago, C., Saldarriaga, R.L., Domagala, D. and Almasri, R., 2010. Volumetric determination of the amount of misfit in CAD/CAM and cast implant frameworks: a multicenter laboratory study. *International Journal of Oral & Maxillofacial Implants*, 25(5).

Emms, M., Tredwin, C.J., Setchell, D.J. and Moles, D.R., 2007. The Effects of Abutment Wall Height, Platform Size, and Screw Access Channel Filling Method on Resistance to Dislodgement of Cement-Retained, Implant-Supported Restorations. *Journal of Prosthodontics*, 16(1), pp.3-9.

Engelman Michael, 1996. Clinical Decision Making and Treatment Planning in Osseointegration

Enkling, N., Jöhren, P., Katsoulis, J., Bayer, S., Jervøe-Storm, P.M., Mericske-Stern, R. and Jepsen, S., 2013. Influence of platform switching on bone-level alterations: a three-year randomized clinical trial. *Journal of dental research*, 92(12_suppl), pp.139S-145S.

Feine, J.S., Carlsson, G.E., Awad, M.A., Chehade, A., Duncan, W.J., Gizani, S., Head, T., Lund, J.P., MacEntee, M., Mericske-Stern, R. and Mojon, P., 2002. The McGill consensus statement on overdentures. Mandibular two-implant overdentures as first choice standard of care for edentulous patients. Montreal, Quebec, May 24-25, 2002. *The International journal of oral & maxillofacial implants*, 17(4), p.601.

Fugazzotto, P.A., 2009. *Implant and regenerative therapy in dentistry: a guide to decision making*. John Wiley & Sons.

Ganz, S.D., 2015. Three-dimensional imaging and guided surgery for dental implants. *Dental Clinics*, 59(2), pp.265-290.

Gracis, S., Michalakis, K., Vigolo, P., Vult von Steyern, P., Zwahlen, M. and Sailer, I., 2012. Internal vs. external connections for abutments/reconstructions: a systematic review. *Clinical oral implants research*, 23(s6), pp.202-216.

Gross M.D. Occlusion in implant dentistry. A review of the literature of prosthetic determinants and current concepts. *Australian Dental Journal* 2007; 53:60-68.

Gulizio, M.P., Agar, J.R., Kelly, J.R. and Taylor, T.D., 2005. Effect of implant angulation upon retention of overdenture attachments. *Journal of Prosthodontics*, 14(1), pp.3-11.

Hatai, Y., 2014. Extreme masking: achieving predictable outcomes in challenging situations with lithium disilicate bonded restorations. *Int J Esthet Dent*, 9(2), pp.206-22.

Hermann, J.S., Buser, D., Schenk, R.K., Higginbottom, F.L. and Cochran, D.L., 2000. Biologic width around titanium implants. A physiologically formed and stable dimension over time. *Clinical oral implants research*, 11(1), pp. 1-11.

Bibliography

- Hosseini, M., Worsaae, N., Schiødt, M. and Gotfredsen, K., 2011. A 1-year randomised controlled trial comparing zirconia versus metal-ceramic implant-supported single-tooth restorations. *European journal of oral implantology*, 4(4).
- Isidor, F., 2006. Influence of forces on peri-implant bone. *Clinical oral implants research*, 17(S2), pp.8-18.
- Jemt, T. and Johansson, J., 2006. Implant Treatment in the Edentulous Maxillae: A 15-Year Follow-Up Study on 76 Consecutive Patients Provided with Fixed Protheses. *Clinical Implant Dentistry and Related Research*, 8(2), pp.61-69.
- Jeu, S., Guillaud, E., Hauret, L., Coutant, J.C. and Ella, B., 2015. Assessment of the Correlation between the Implant Distance and Primary Stability by Resonance Frequency Analysis. *Journal of Dental Surgery*, 2015.
- Kan, J.Y., Rungcharassaeng, K., Umezu, K. and Kois, J.C., 2003. Dimensions of peri-implant mucosa: an evaluation of maxillary anterior single implants in humans. *Journal of periodontology*, 74(4), pp, 557-562.
- Kerstein, D.M.D. and Robert, B. eds., 2014. *Handbook of research on computerized occlusal analysis technology applications in dental medicine*. IGI Global.
- Kleis, W.K., Kämmerer, P.W., Hartmann, S., Al-Nawas, B. and Wagner, W., 2010. A Comparison of Three Different Attachment Systems for Mandibular Two-Implant Overdentures: One-Year Report. *Clinical implant dentistry and related research*, 12(3), pp.209-218.
- Kowar, J., Eriksson, A. and Jemt, T., 2013. Fixed Implant-Supported Protheses in Elderly Patients: A 5 Year Retrospective Comparison between Partially and Completely Edentulous Patients Aged 80 Years or Older at Implant Surgery. *Clinical implant dentistry and related research*, 15(1), pp.37-46.
- Koyano, K. and Esaki, D., 2015. Occlusion on oral implants: current clinical guidelines. *Journal of oral rehabilitation*, 42(2), pp.153-161.
- Kreissl, M.E., Gerds, T., Mucbe, R., Heydecke, G. and Strub, J.R., 2007. Technical complications of implant-supported fixed partial dentures in partially edentulous cases after an average observation period of 5 years. *Clinical oral implants research*, 18(6), pp.720-726.
- Lai, H.C., Si, M.S., Zhuang, L.F., Shen, H., Liu, Y.L. and Wismeijer, D., 2013. Long-term outcomes of short dental implants supporting single crowns in posterior region: a clinical retrospective study of 5–10 years. *Clinical Oral Implants Research*, 24(2), pp.230-237.
- Lang, N.P., Wilson, T.G. and Corbet, E.F., 2000. Biological complications with dental implants: their prevention, diagnosis and treatment. *Clinical oral implants research*, 11(s1), pp.146-155.
- Lin, W.S., Harris, B.T., Zandinejad, A. and Morton, D., 2014. Use of digital data acquisition and CAD/CAM technology for the fabrication of a fixed complete dental prosthesis on dental implants. *Journal of Prosthetic Dentistry*, 111(1), pp.1-5.
- Lindhe, J. and Meyle, J., 2008. Peri-implant diseases: Consensus Report of the Sixth European Workshop on Periodontology. *Journal of clinical periodontology*, 35(s8), pp.282-285.
- Lindquist, L.W., Carlsson, G.E. and Jemt, T., 1996. A prospective 15-year follow-up study of mandibular fixed protheses supported by osseointegrated implants. Clinical results and marginal bone loss. *Clinical oral implants research*, 7(4), pp.329-336.
- Mangano, F.G., Shibli, J.A., Sammons, R.L., Iaculli, F., Piattelli, A. and Mangano, C., 2014. Short (8-mm) locking-taper implants supporting single crowns in posterior region: a prospective clinical study with 1-to 10-years of follow-up. *Clinical Oral Implants Research*, 25(8), pp.933-940.
- Mericske-Stern, R. and Worni, A., 2014. Optimal number of oral implants for fixed reconstructions: a review of the literature. *Eur J Oral Implantol*, 7(Suppl 2), pp.S133-S153.
- Naert, I., Gizani, S., Vuylsteke, M. and Van Steenberghe, D., 1998. A 5-year randomized clinical trial on the influence of splinted and unsplinted oral implants in the mandibular overdenture therapy. Part I: peri-implant outcome. *Clinical Oral Implants Research*, 9(3), pp.170-177.

- Nedir, R., Bischof, M., Szmukler-Moncler, S., Belser, U.C. and Samson, J., 2006. Prosthetic complications with dental implants: from an up-to-8-year experience in private practice. *International Journal of Oral & Maxillofacial Implants*, 21(6).
- Nissan, J., Narobai, D., Gross, O., Ghelfan, O. and Chaushu, G., 2011. Long-term outcome of cemented versus screw-retained implant-supported partial restorations. *International Journal of Oral and Maxillofacial Implants*, 26(5), p.1102.
- Nothdurft, F. and Pospiech, P., 2010. Prefabricated zirconium dioxide implant abutments for single-tooth replacement in the posterior region: evaluation of peri-implant tissues and superstructures after 12 months of function. *Clinical oral implants research*, 21(8), pp. 857-865
- Ogle, O.E., 2015. Implant surface material, design, and osseointegration. *Dental Clinics*, 59(2), pp.505-520.
- Örtorp, A. and Jemt, T., 2008. Laser-Welded Titanium Frameworks Supported by Implants in the Partially Edentulous Mandible: A 10-Year Comparative Follow-Up Study. *Clinical implant dentistry and related research*, 10(3), pp.128-139.
- Osman, R.B., Payne, A.G. and Ma, S., 2012. Prosthodontic maintenance of maxillary implant overdentures: a systematic literature review. *International Journal of Prosthodontics*, 25(4).
- Phillips, K. and Wong, K.M., 2001. Space requirements for implant-retained bar-and-clip overdentures. *Compendium of continuing education in dentistry (Jamesburg, NJ: 1995)*, 22(6): 516-518, 520, 522
- Pjetursson, B.E., Thoma, D., Jung, R., Zwahlen, M. and Zembic, A., 2012. A systematic review of the survival and complication rates of implant-supported fixed dental prostheses (FDPs) after a mean observation period of at least 5 years. *Clinical oral implants research*, 23(s6), pp 22-38.
- Pozzi, A., Sannino, G. and Barlattani, A., 2012. Minimally invasive treatment of the atrophic posterior maxilla: a proof-of-concept prospective study with a follow-up of between 36 and 54 months. *Journal of Prosthetic Dentistry*, 108(5), pp.286-297.
- Preciado, A., Del Río, J., Suárez-García, M.J., Montero, J., Lynch, C.D. and Castillo-Oyagüe, R., 2012. Differences in impact of patient and prosthetic characteristics on oral health-related quality of life among implant-retained overdenture wearers. *Journal of Dentistry*, 40(10), pp.857-865.
- Romeo, E., Tomasi, C., Finini, I., Casentini, P. and Lops, D., 2009. Implant-supported fixed cantilever prosthesis in partially edentulous jaws: a cohort prospective study. *Clinical oral implants research*, 20(11), pp.1278-1285.
- Sadid-Zadeh, R., Kutkut, A. and Kim, H., 2015. Prosthetic failure in implant dentistry. *Dental Clinics of North America*, 59(1), pp.195-214.
- Sadig, W.M. and Al Harbi, M.W., 2007. Effects of surface conditioning on the retentiveness of titanium crowns over short implant abutments. *Implant dentistry*, 16(4), pp.387-396.
- Sadowsky, S.J., 2001. Mandibular implant-retained overdentures: a literature review. *Journal of prosthetic dentistry*, 86(5), pp. 468-473.
- Sadowsky, S.J., 2007. Treatment considerations for maxillary implant overdentures: a systematic review. *Journal of Prosthetic Dentistry*, 97(6), pp.340-348.
- Sadowsky, S.J. and Zitzmann, N.U., 2016. Protocols for the Maxillary Implant Overdenture: A Systematic Review. *International Journal of Oral & Maxillofacial Implants*, 31.
- Schwarz, S., Schröder, C., Hassel, A., Bömicke, W. and Rammelsberg, P., 2012. Survival and Chipping of Zirconia-Based and Metal-Ceramic Implant-Supported Single Crowns. *Clinical implant dentistry and related research*, 14(s1).
- Shah, K.C. and Lum, M.G., 2008. Treatment planning for the single-tooth implant restoration--general considerations and the pretreatment evaluation. *Journal of the California Dental Association*, 36(11), pp.827-834.
- Sailer, I., Sailer, T., Stawarczyk, B., Jung, R.E. and Hämmerle, C.H., 2009. In vitro study of the influence of the type of connection on the fracture load of zirconia abutments with internal and external implant-abutment connections. *Int J Oral Maxillofac Implants*, 24(5), pp.850-858.

- Sethi, A., Kaus, T., Weber, H. and Rajarayan, R.K., 2005. *Practical implant dentistry: diagnostic, surgical, restorative and technical aspects of aesthetic and functional Harmony*. Quintessence.
- Stanford, C.M., 2005. Application of oral implants to the general dental practice. *The Journal of the American Dental Association*, 136(8), pp. 1092-1100.
- Tagliareni, J.M. and Clarkson, E., 2015. Basic concepts and techniques of dental implants. *Dental Clinics*, 59(2), pp.255-264.
- Teigen, K. and Jokstad, A., 2012. Dental implant suprastructures using cobalt–chromium alloy compared with gold alloy framework veneered with ceramic or acrylic resin: a retrospective cohort study up to 18 years. *Clinical oral implants research*, 23(7), pp.853-860.
- Thalji, G., Bryington, M., De Kok, I.J. and Cooper, L.F., 2014. Prosthodontic management of implant therapy. *Dental Clinics*, 58(1), pp.207-225.
- Thoma, D.S., Villar, C.C., Cochran, D.L., Hämmerle, C.H. and Jung, R.E., 2012. Tissue integration of collagen-based matrices: an experimental study in mice. *Clinical oral implants research*, 23(12), pp.1333-1339.
- Vandeweghe, S., Cosyn, J., Thevissen, E., Teerlinck, J. and De Bruyn, H., 2012. The Influence of Implant Design on Bone Remodeling around Surface-Modified Southern Implants®. *Clinical implant dentistry and related research*, 14(5), pp. 655-662.
- Vasak, C., Kohal, R.J., Lettner, S., Rohner, D. and Zechner, W., 2014. Clinical and radiological evaluation of a template-guided (NobelGuide™) treatment concept. *Clinical oral implants research*, 25(1), pp.116-123.
- Wahlström, M., Sagulin, G.B. and Jansson, L.E., 2010. Clinical follow-up of unilateral, fixed dental prosthesis on maxillary implants. *Clinical oral implants research*, 21(11), pp.1294-1300.
- Weber, H.P., Buser, D. and Belser, U.C., 2008. Examination of the candidate for implant therapy. *Clinical periodontology and implant dentistry*, 1, pp. 587-597.
- Yamaguchi, Y., Shiota, M., Munakata, M., Kasugai, S. and Ozeki, M., 2015. Effect of implant design on primary stability using torque-time curves in artificial bone. *International Journal of Implant Dentistry*, 1(1), p.21.
- Zahedi, C., 2016. Treatment of Orally Handicapped Edentulous Older Adults Using Dental Implants. *Dental Clinics*, 60(3), pp.663-691.
- Zarb, G.A. and Schmitt, A., 1990. The longitudinal clinical effectiveness of osseointegrated dental implants: the Toronto study. Part I: surgical results. *The Journal of prosthetic dentistry*, 63(4), pp.451-457.
- Zembic, A. and Wismeijer, D., 2014. Patient-reported outcomes of maxillary implant-supported overdentures compared with conventional dentures. *Clinical oral implants research*, 25(4), pp.441-450.
- Zembic, A., Bösch, A., Jung, R.E., Hämmerle, C.H. and Sailer, I., 2013. Five-year results of a randomized controlled clinical trial comparing zirconia and titanium abutments supporting single-implant crowns in canine and posterior regions. *Clinical oral implants research*, 24(4), pp.384-390.

CHAPTER 9

Atito, A.M., Reda, M.S. and Al Khames, B., 2006. COMPARISON BETWEEN COBALT-CHROMIUM AND DENTAL D-ACETAL RESIN CLASPS (IN VITRO STUDY). *Official Journal of the Egyptian Dental Association*, 52(4.2).

Barco Jr, M.T. and Flinton, R.J., 1988. An overview of four removable partial denture clasps. *International Journal of Prosthodontics*, 1(2).

- Bilgin, M.S., Baytaroğlu, E.N., Erdem, A. and Dilber, E., 2016. A review of computer-aided design/computer-aided manufacture techniques for removable denture fabrication. *European journal of dentistry*, 10(2), p.286.
- Bohnenkamp, D.M., 2014. Removable partial dentures: clinical concepts. *Dental Clinics of North America*, 58(1), pp.69-89.
- Bouma, L.O., Mansueto, M.A. and Koeppen, R.G., 2001. A nontraditional technique for obtaining optimal esthetics for an immediate denture: a clinical report. *Journal of Prosthodontics*, 10(2), pp.97-101.
- Browning, J.D., Meadors, L.W. and Eick, J.D., 1986. Movement of three removable partial denture clasp assemblies under occlusal loading. *The Journal of prosthetic dentistry*, 55(1), pp.69-74.
- Carr, A.B. and Brown, D.T., 2010. *McCracken's removable partial prosthodontics*. Elsevier Health Sciences.
- De Freitas, R.F.C.P., de Carvalho Dias, K., da Fonte Porto Carreiro, A., Barbosa, G.A.S. and Ferreira, M.A.F., 2012. Mandibular implant-supported removable partial denture with distal extension: a systematic review. *Journal of oral rehabilitation*, 39(10), pp.791-798.
- Ender, A. and Mehl, A., 2015. In-vitro evaluation of the accuracy of conventional and digital methods of obtaining full-arch dental impressions. *Quintessence International*, 46(1).
- Ender, A., Attin, T. and Mehl, A., 2016. In vivo precision of conventional and digital methods of obtaining complete-arch dental impressions. *Journal of Prosthetic Dentistry*, 115(3), pp.313-320.
- Gilboa, I. and Cardash, H.S., 2009. An alternative approach to the immediate overdenture. *Journal of Prosthodontics*, 18(1), pp.71-75.
- Gooya, A., Ejlali, M. and Adli, A.R., 2013. Fabricating an interim immediate partial denture in one appointment (modified jiffy denture). A clinical report. *Journal of Prosthodontics*, 22(4), pp.330-333.
- Kattadiyil, M.T., Mursic, Z., AlRumaih, H. and Goodacre, C.J., 2014. Intraoral scanning of hard and soft tissues for partial removable dental prosthesis fabrication. *Journal of Prosthetic Dentistry*, 112(3), pp.444-448.
- MacEntee, M.I. and Wyatt, C.C.L., 1999. An index of clinical oral disorder in elders (CODE). *Gerodontology*, 16(2), pp.85-96.
- Patzelt, S.B., Vonau, S., Stampf, S. and Att, W., 2013. Assessing the feasibility and accuracy of digitizing edentulous jaws. *The Journal of the American Dental Association*, 144(8), pp.914-920.
- Phoenix, R.D. and Fleigel, J.D., 2008. Cast modification for immediate complete dentures: Traditional and contemporary considerations with an introduction of spatial modeling. *Journal of Prosthetic Dentistry*, 100(5), pp.399-405.
- Sülün, T. and Sakar, O., 2016. Diagnosis and Treatment Planning in Partially Edentulous Patients. In *Removable Partial Dentures* (pp. 37-52). Springer, Cham.
- Seals Jr, R.R., Kuebker, W.A. and Stewart, K.L., 1996. Immediate complete dentures. *Dental Clinics of North America*, 40(1), pp.151-167.

CONTACTS

Andent

W: andent.com | **P:** +61 3 9650 6766

Gold and Ceramics

W: goldandceramics.com.au | **P:** +61 7 3852 1195

Precision Dental Laboratory

W: precisiondental.co.nz | **P:** +64 9 377 5451

Proform Australia

W: proformaaustralia.com.au | **P:** +61 3 9650 9779

Southern Cross Dental AU

W: scdlab.com | **P:** +61 2 8062 9800

Southern Cross Dental NZ

W: scdlab.co.nz | **P:** +64 7 346 0516

Southern Cross Dental ROI & NI/UK

W: scdlab.co.uk | **P:** (ROI) 048 8772 7100 | **P:** (NI/UK) 028 8772 7100







Since 1986, Modern Dental Group has provided continuous dental innovations and clinical support to dental professionals around the globe, including Asia, Oceania, Europe and the USA. As their local arm, Modern Dental Pacific's laboratories draw from the group's global expertise to cater to the evolving needs of the Australasian dental community.

Every day, we help oral physicians achieve best practice clinical outcomes and optimal patient care. We do this by providing full-service laboratories, expert guidance and clinical support, as well as professional training and accreditation.

Our state-of-the-art laboratories are fully equipped with the latest technologies and comprehensive digital workflow systems. We offer a full spectrum of laboratory services produced both domestically and internationally. Our highly skilled team of technicians specialise in the creation of high-quality dental restorations, ranging from fixed and removable prosthodontics, implants, occlusal appliances, anti-snoring devices, sleep devices and orthodontic products.

We offer our practice partners a high quality and personalised service, access to peer-to-peer support and product specific guidelines and advice. As part of our commitment to supporting the professional development of dentists, we also offer a comprehensive learning suite with up to date training courses and professional clear aligner treatment accreditation.

**Get ready to take the next step in your dental practice.
Think Innovation. Think Modern Dental Pacific.**